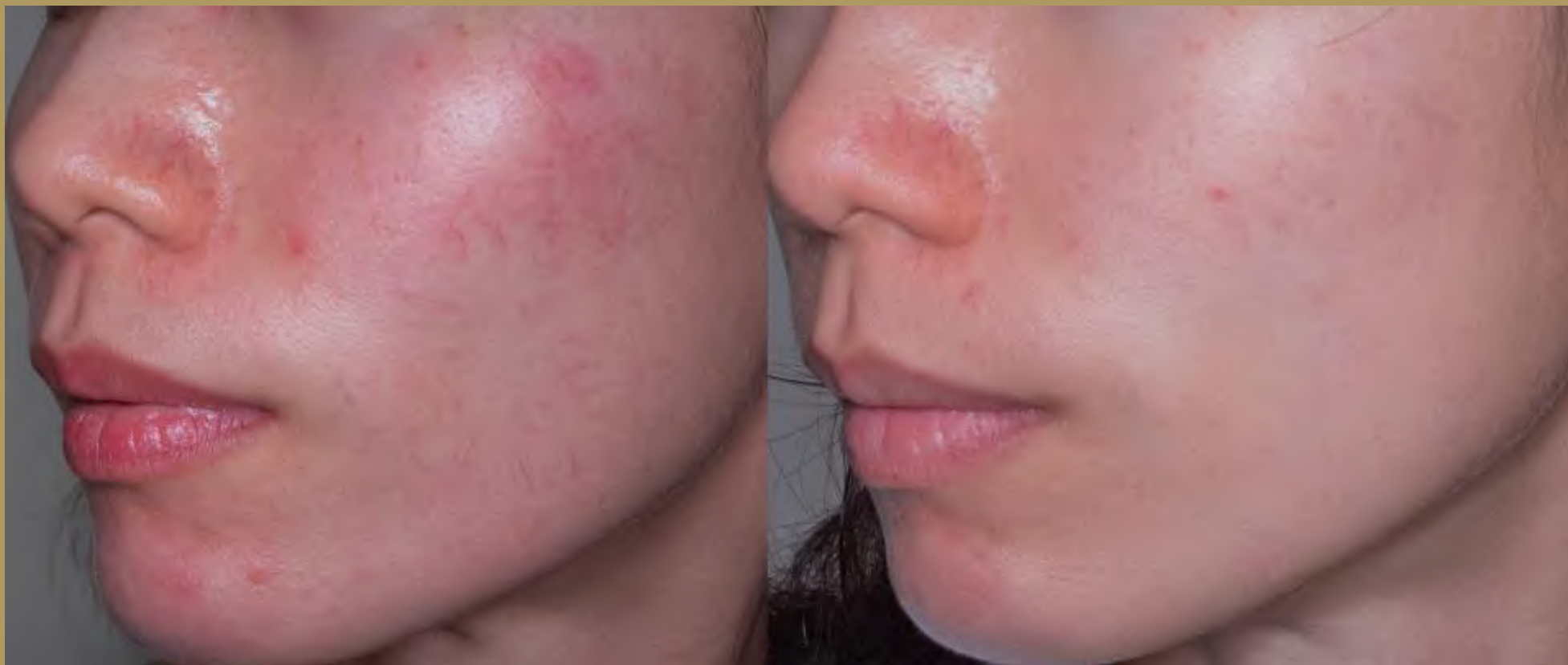
Clinical Case Book QuadroStarPRO



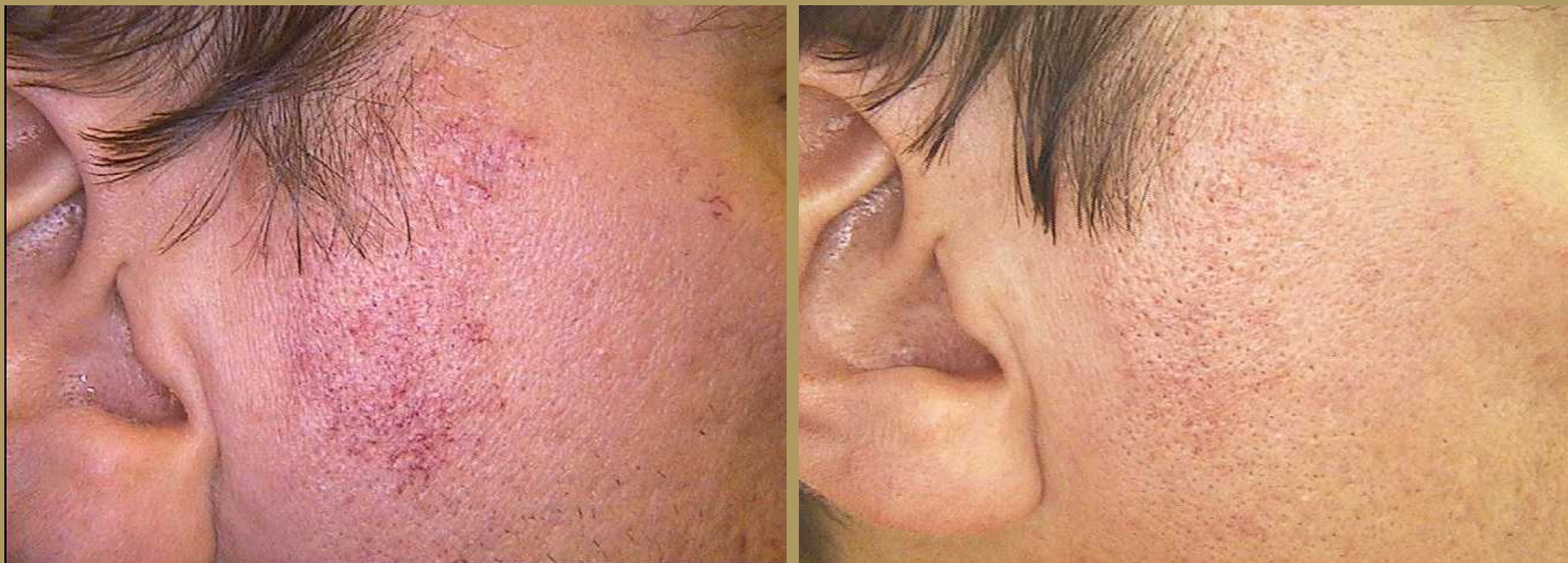QuadroStarPRO^{YELLOW} (577 nm)

Telangiectasia



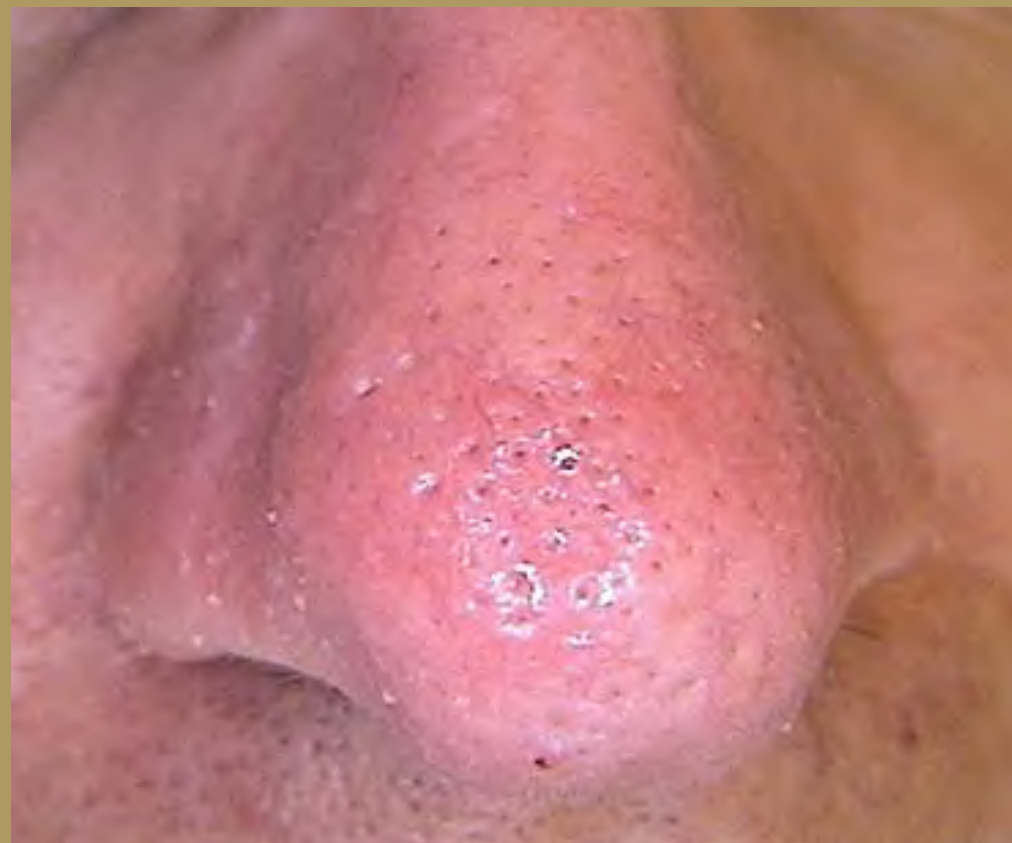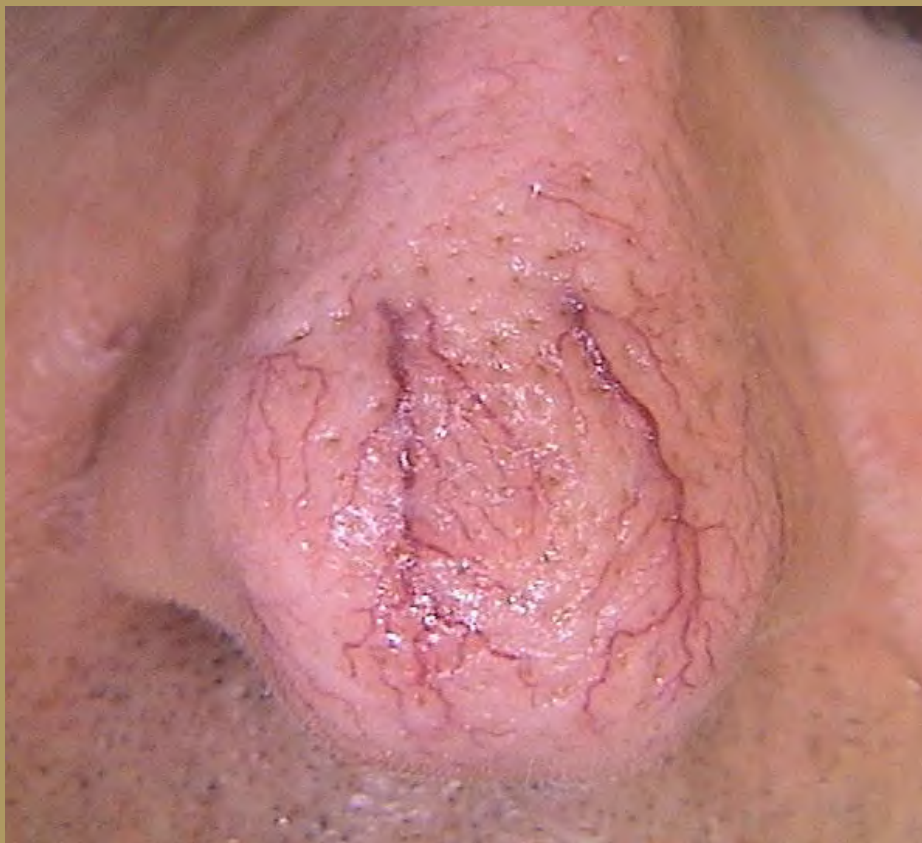before and after 1 month, trace, 1mm spot size, 14-16j/cm², shortest pulse

Telangiectasia

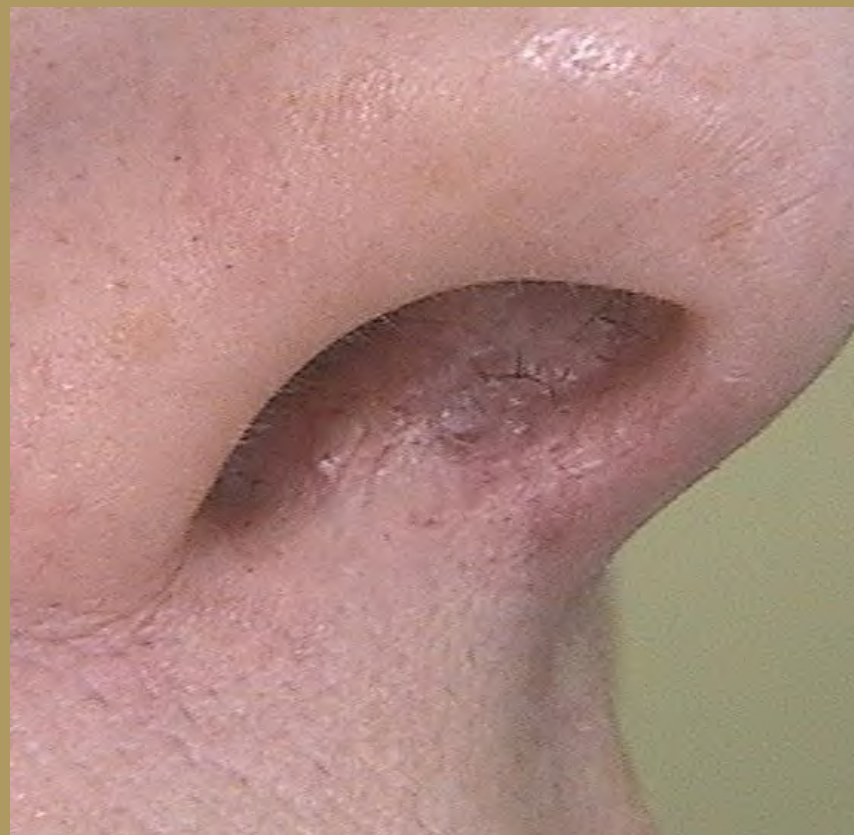
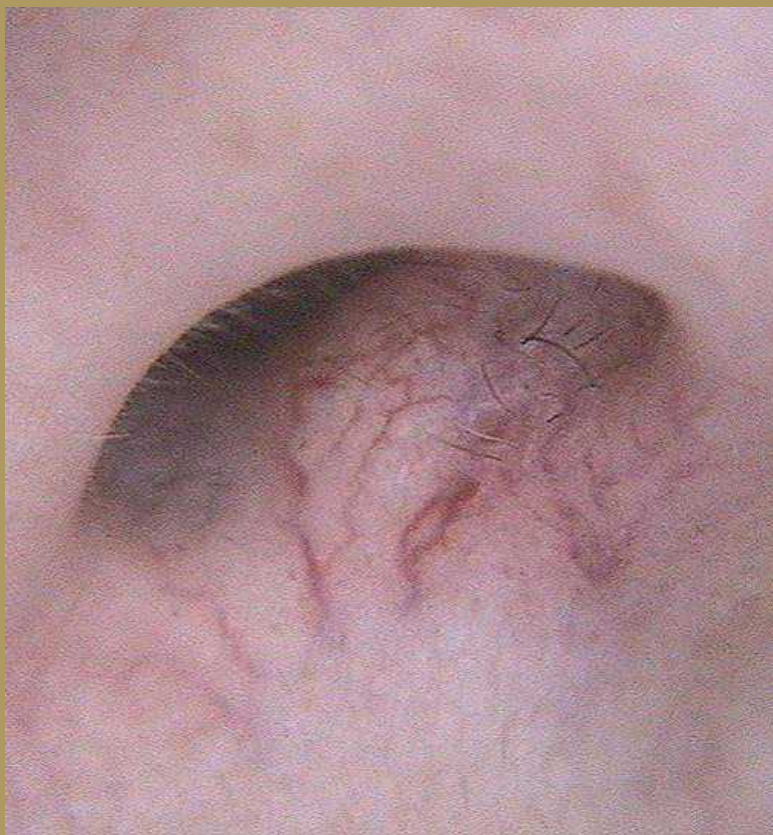
before and after 3 weeks, Scanner 100% coverage, 19 J/cm², 11ms

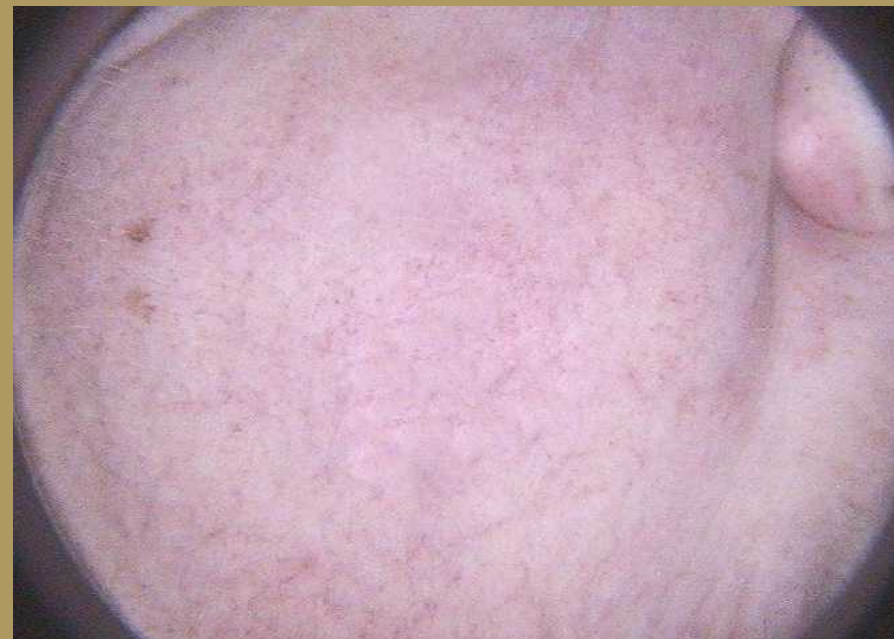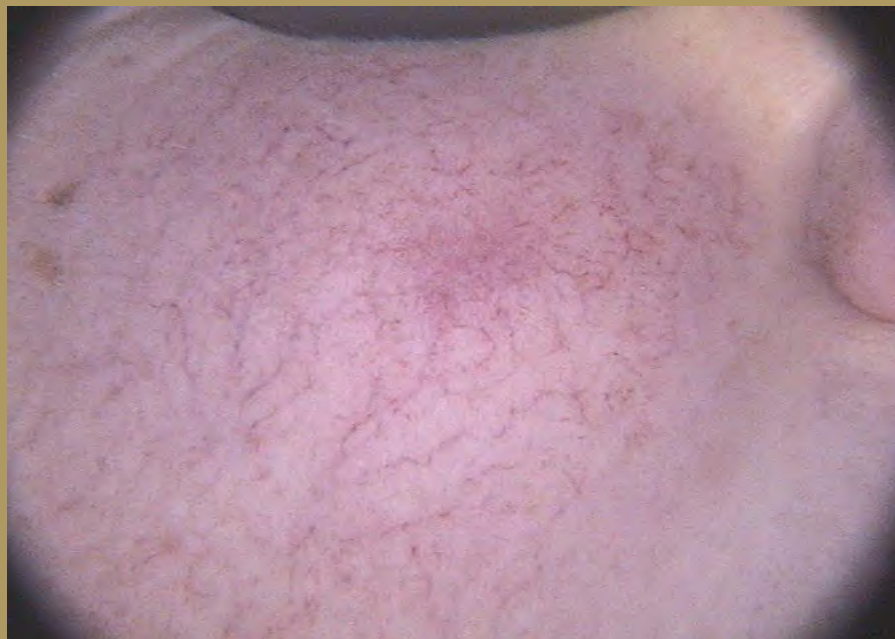Telangiectasia



Telangiectasia

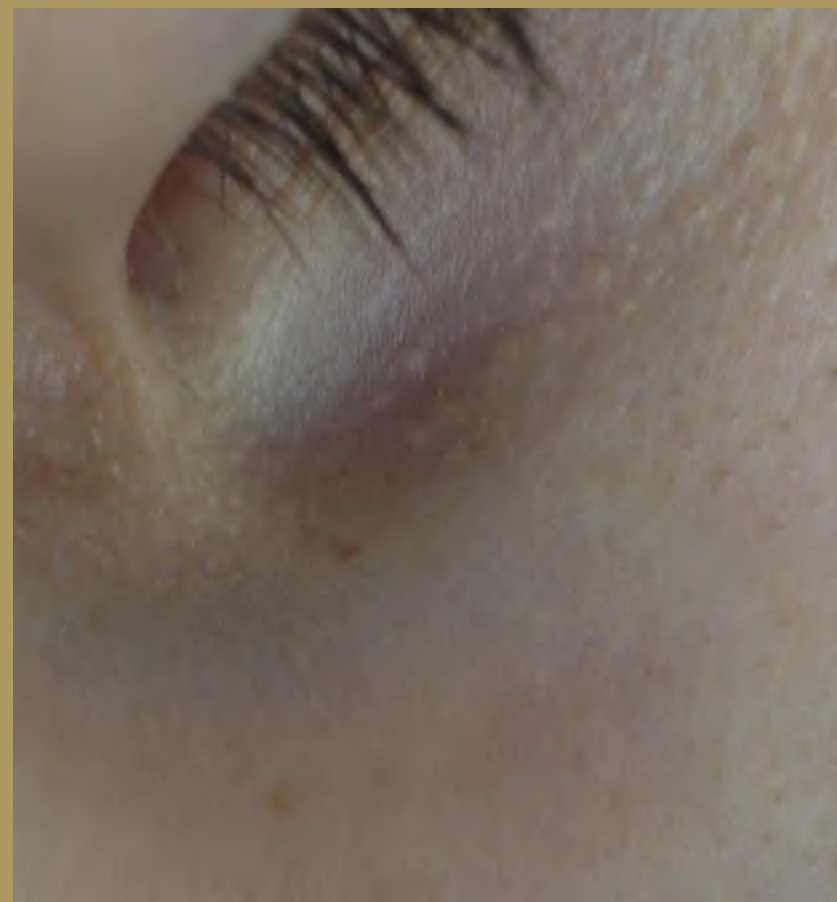
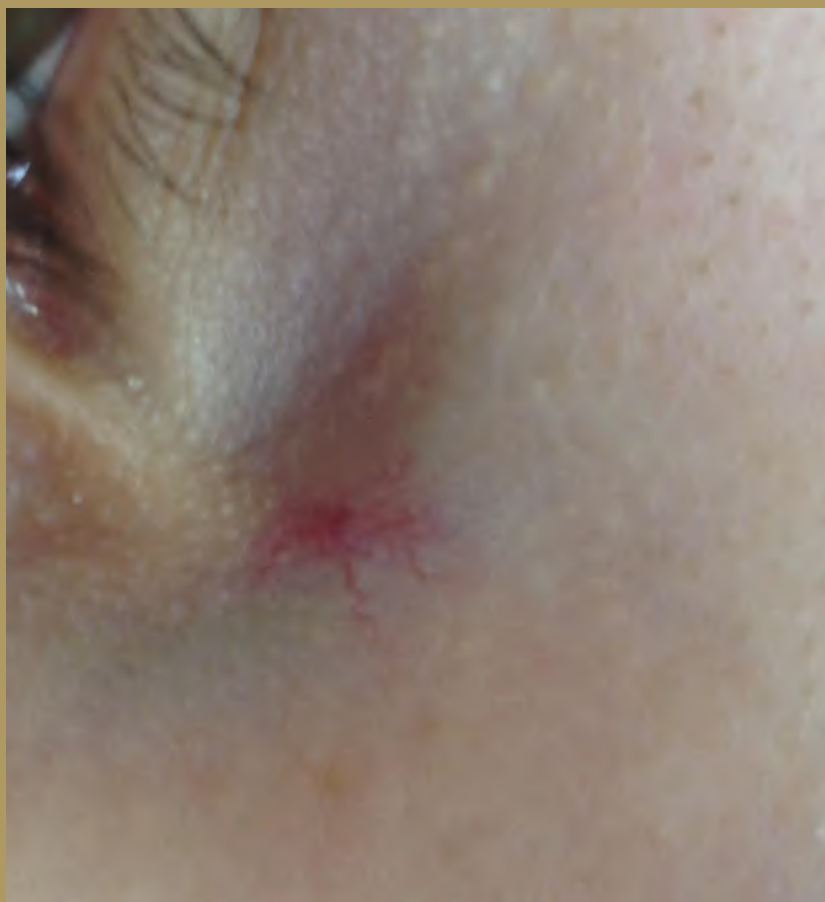
Couperose/rosacea

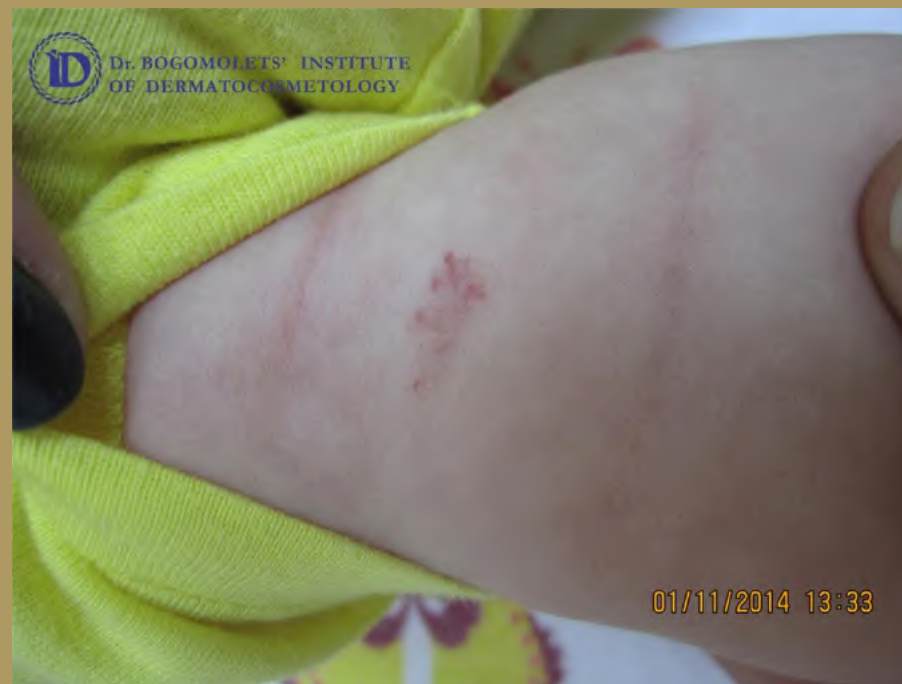
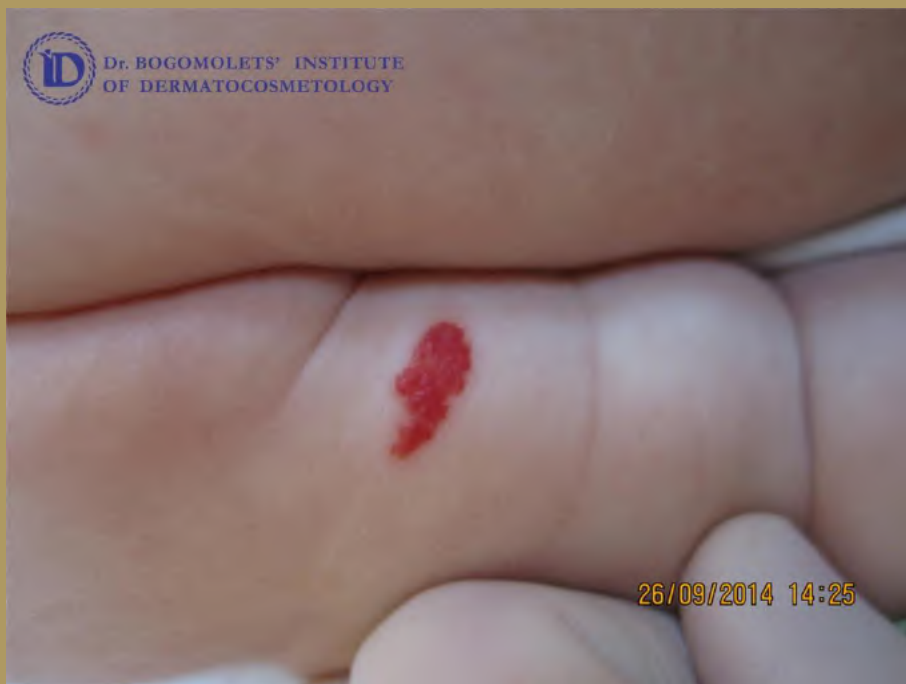
before and after 3 weeks, 1mm spot, 12J/cm², 19ms

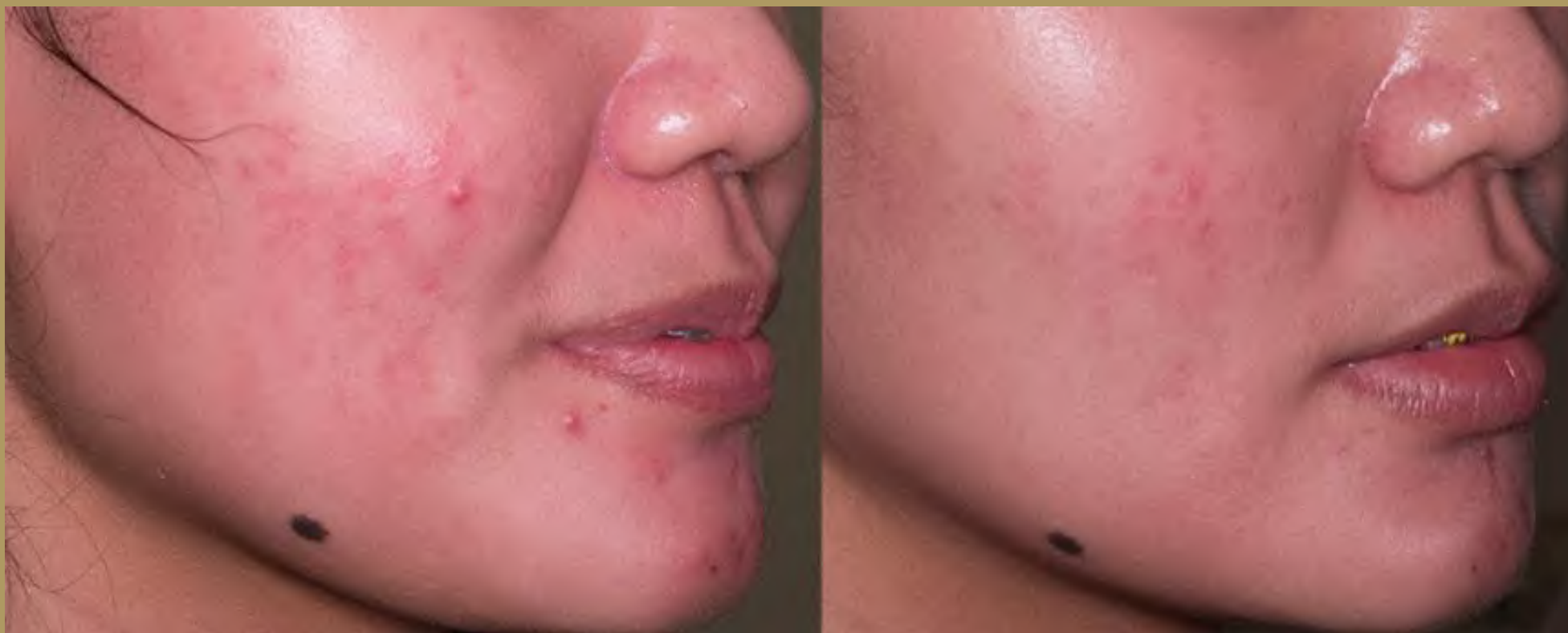Spider nevus



Hemangioma

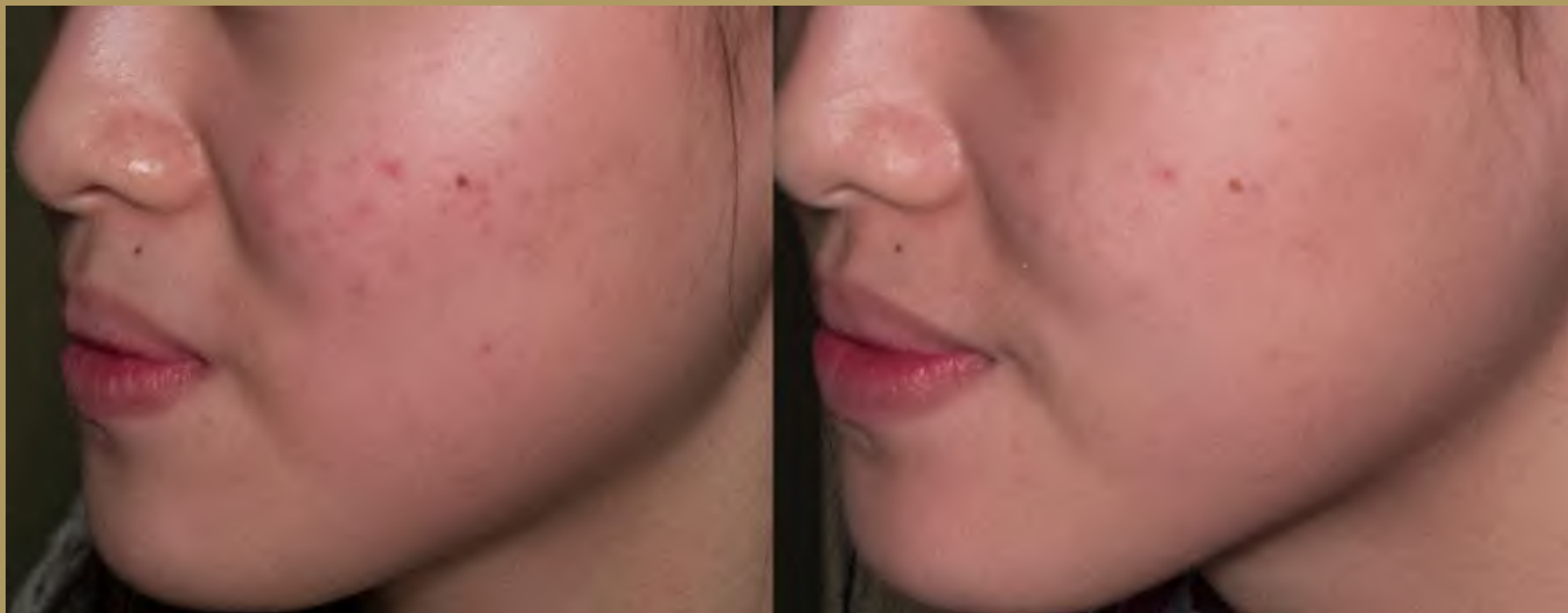

Post acne erythema



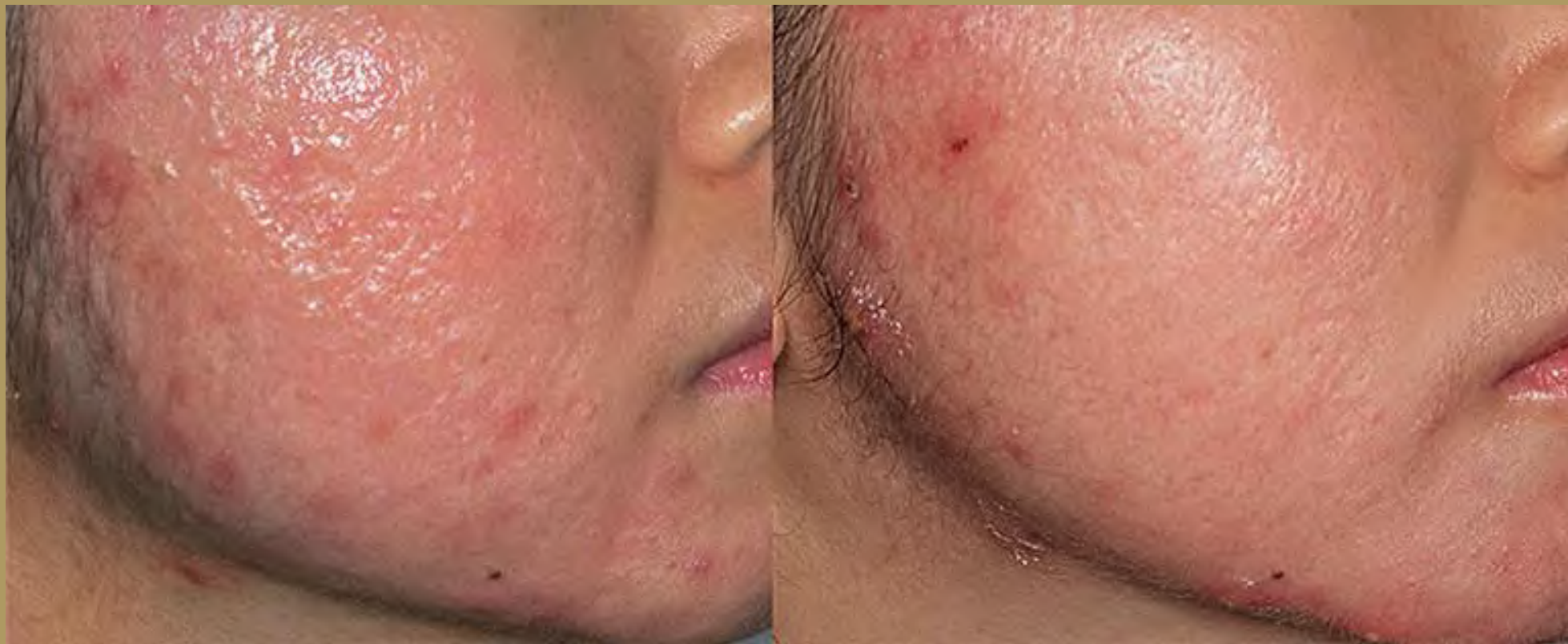before and after 1 month, Scanner 80% coverage, 70% cooling, 20 J/cm², shortest pulse

Post acne erythema



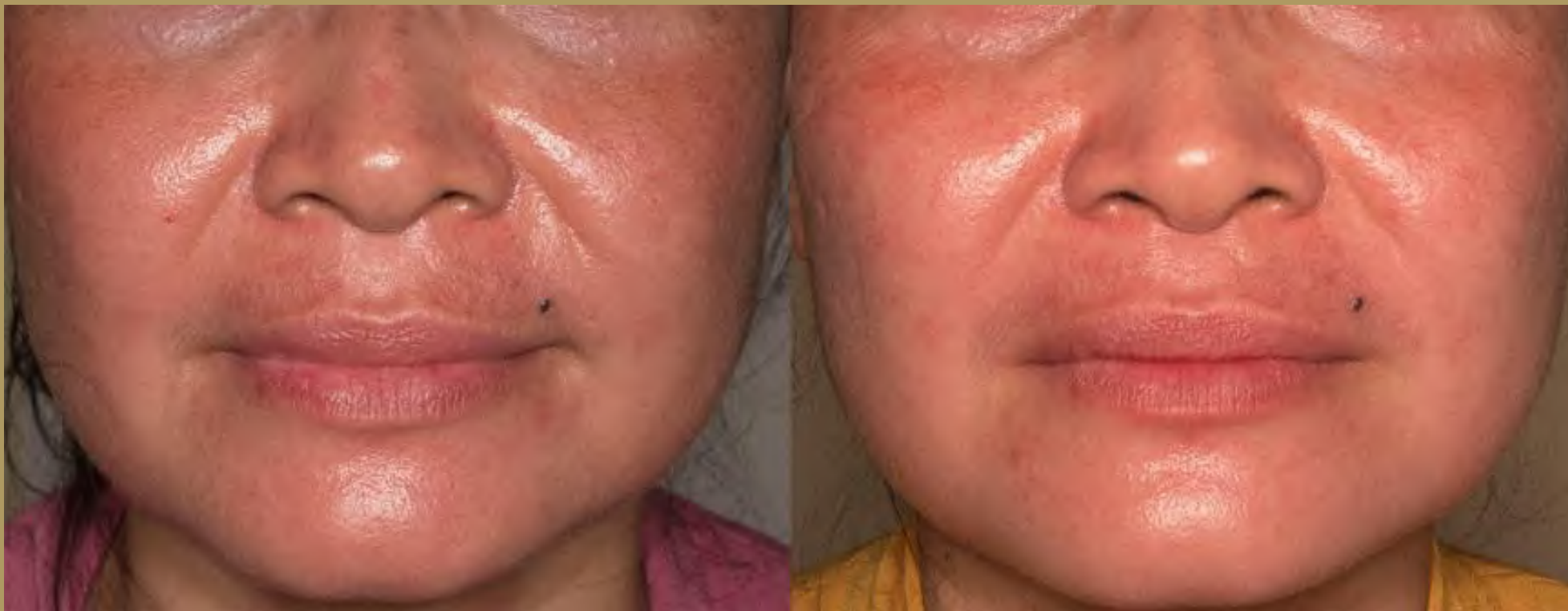before and after 1 month, Scanner 80% coverage, 70% cooling, 20 J/cm², shortest pulse + brush 14 J/cm² on spots defocused 5 cm

Post acne erythema



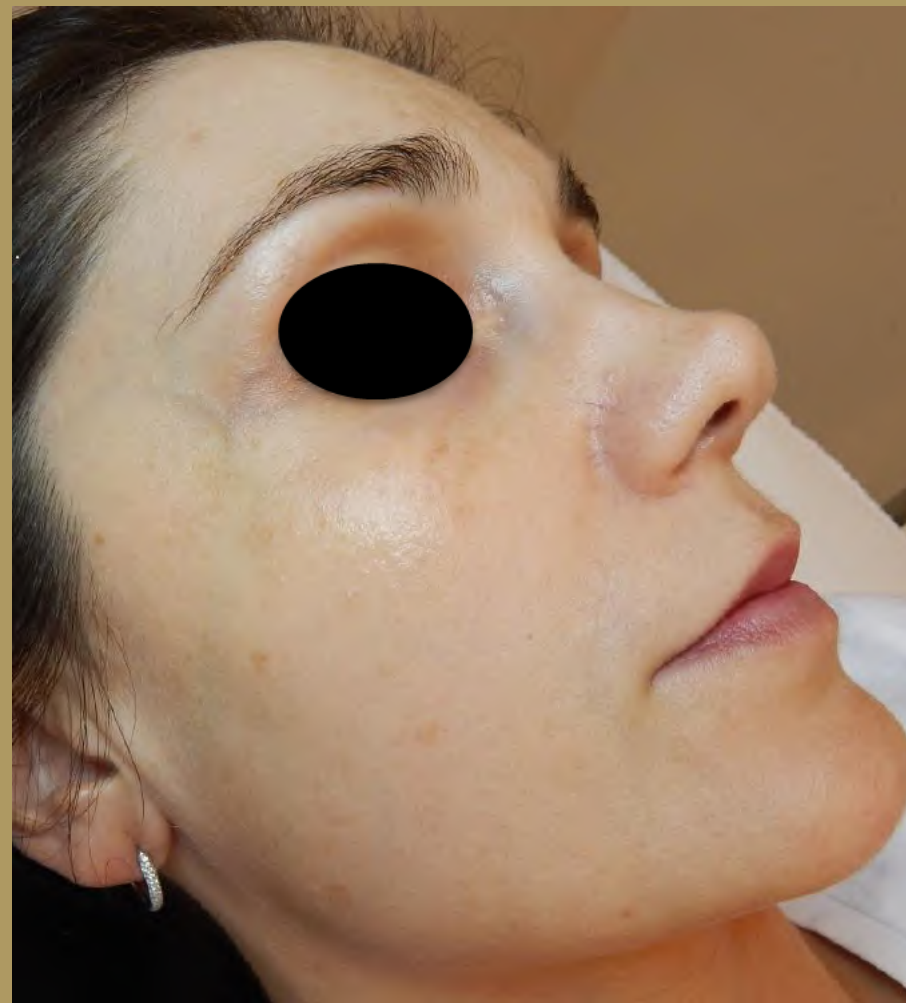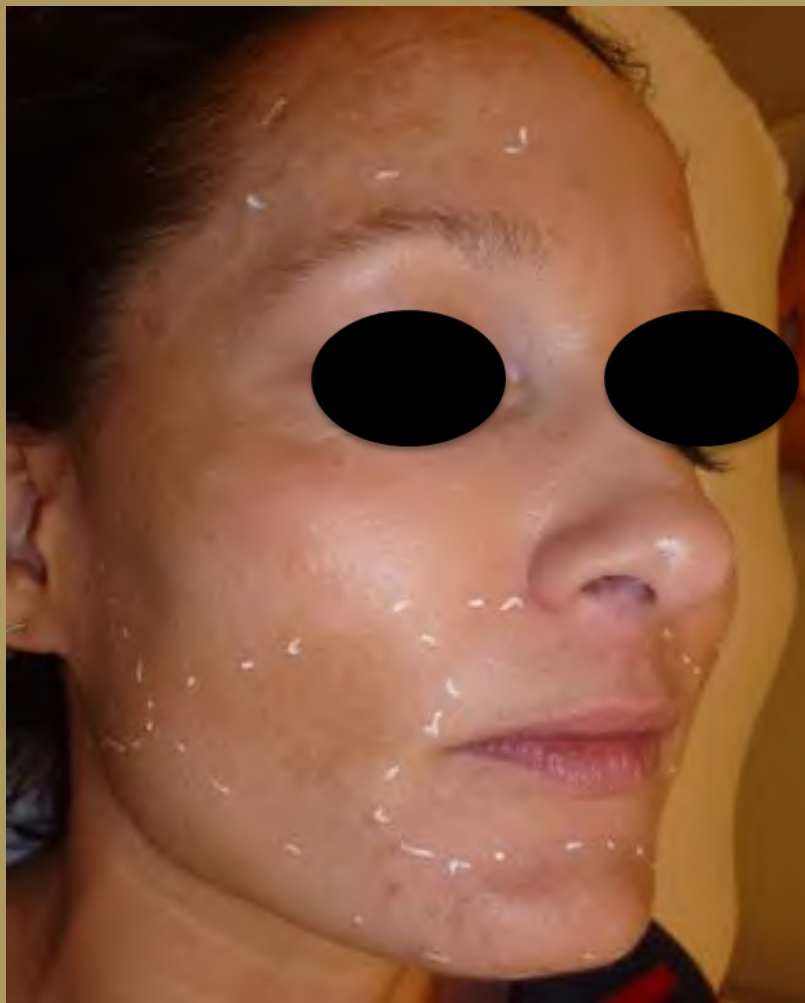before and after 1 month, Scanner 80% coverage, 70% cooling, 22 J/cm², shortest pulse

Pigmented and vascular lesions

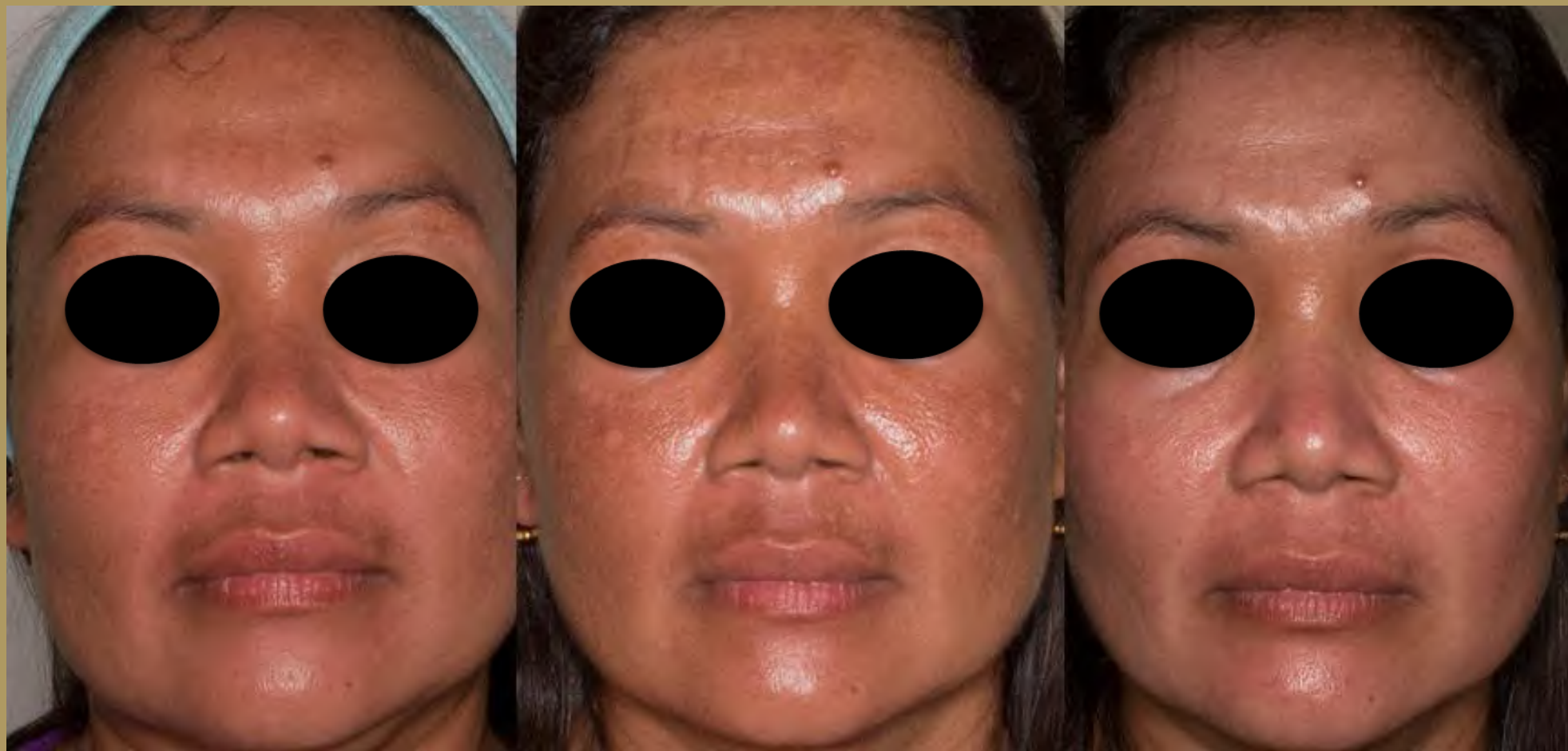

before and after 1 month, 1 mm spot, 1 trace, 15 J/cm², shortest pulse

Melasma

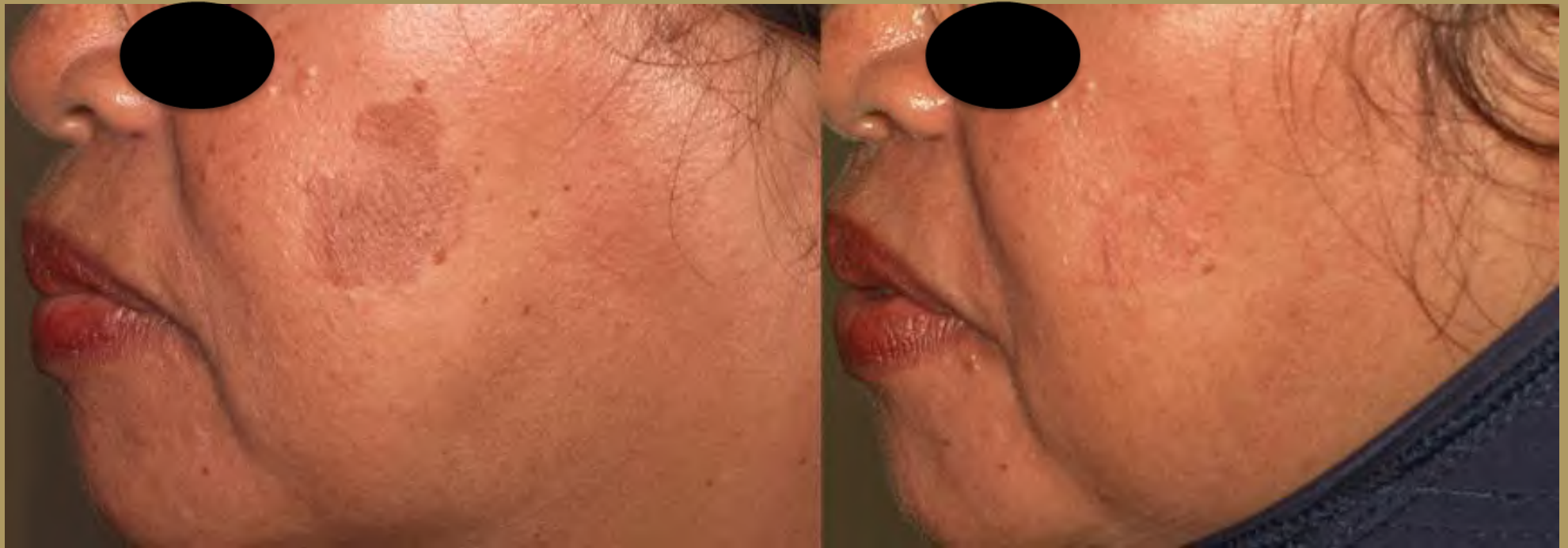

Melasma



before and after 1 month, Scanner 80% coverage, 100% cooling, 18 J/cm², shortest pulse

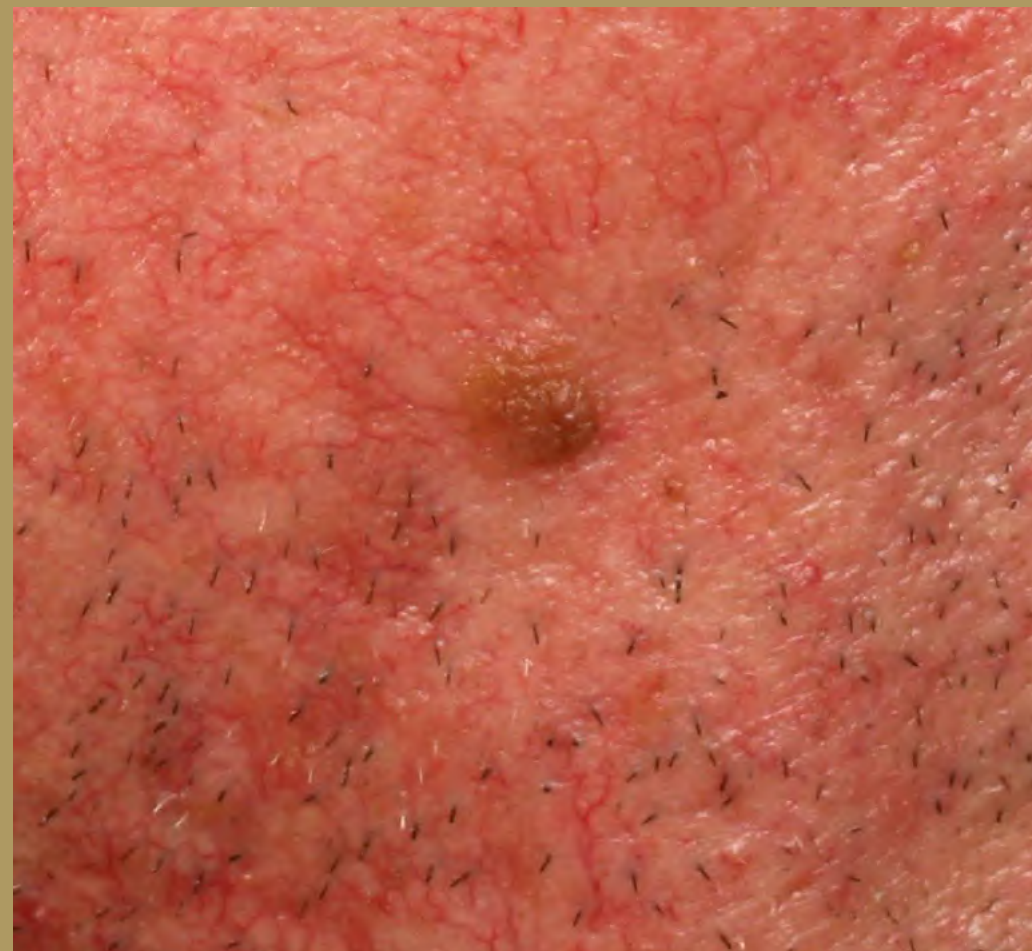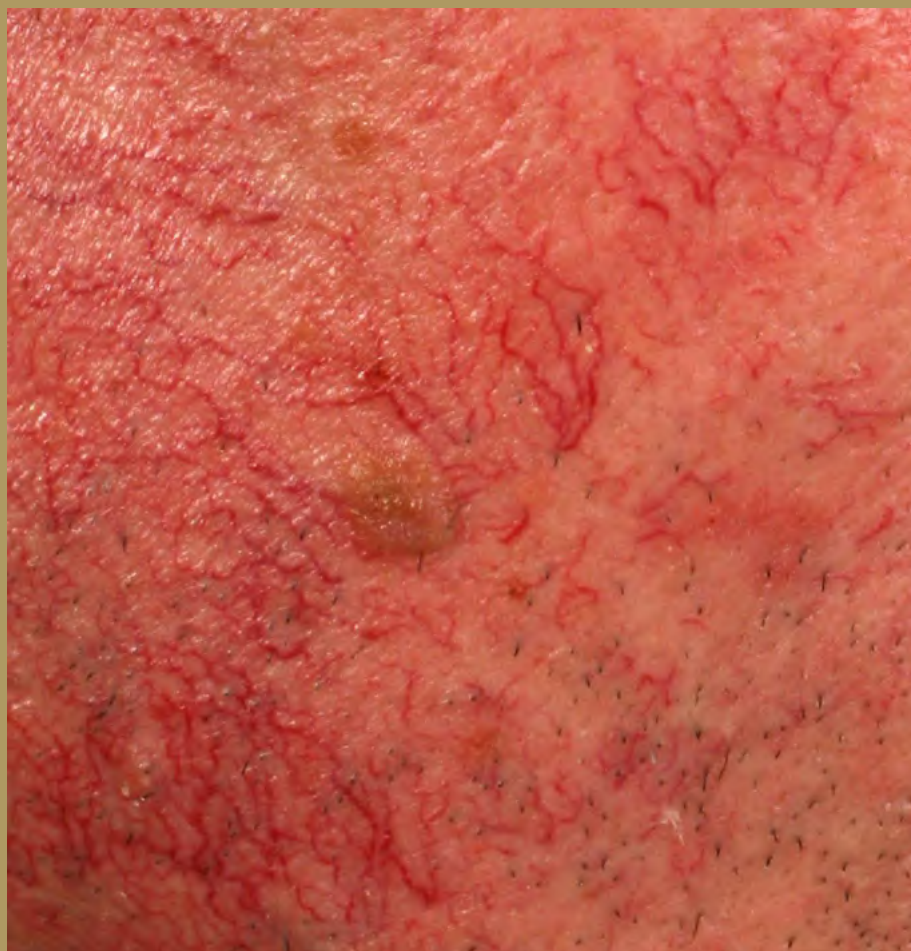Lentigo



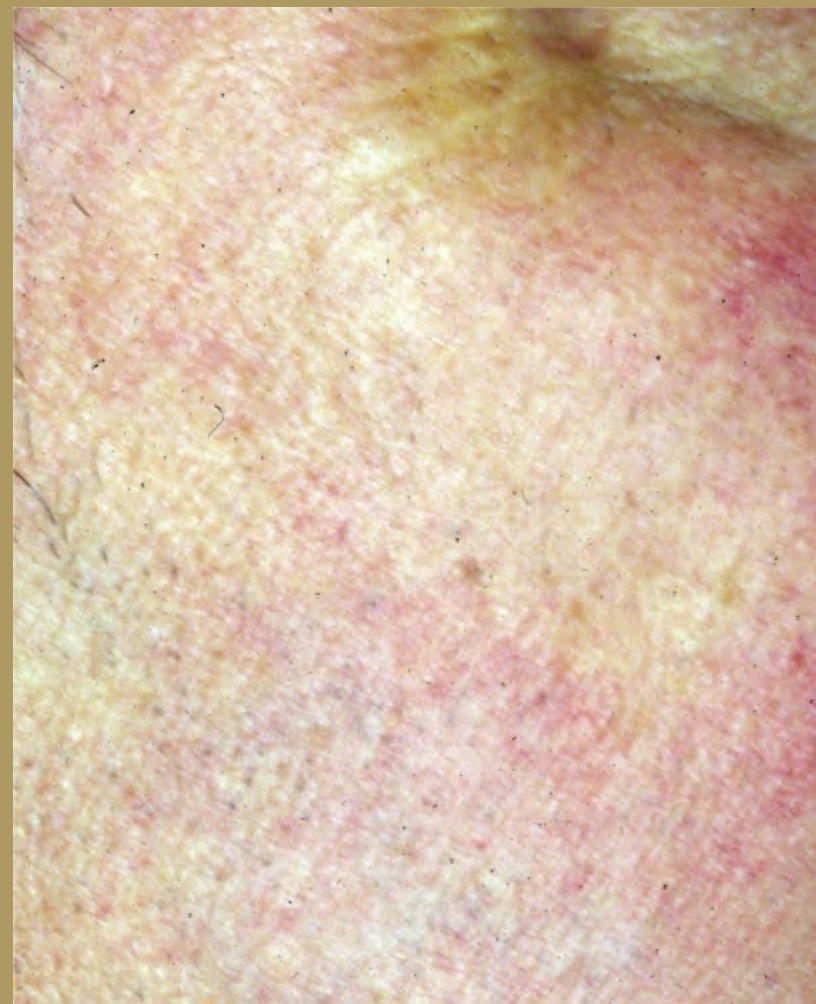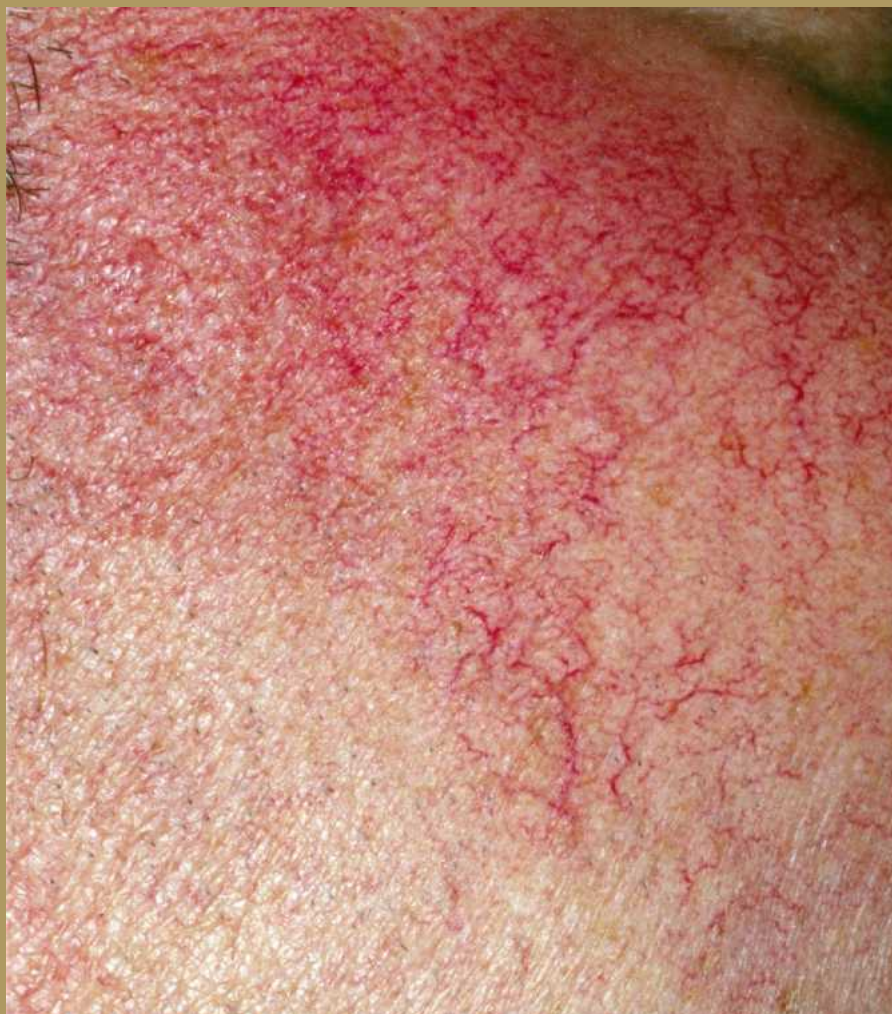before and after 1 month, brush 12 J/cm² on spot defocused 5 cm, shortest pulse

QuadroStarPRO **GREEN** (532 nm)

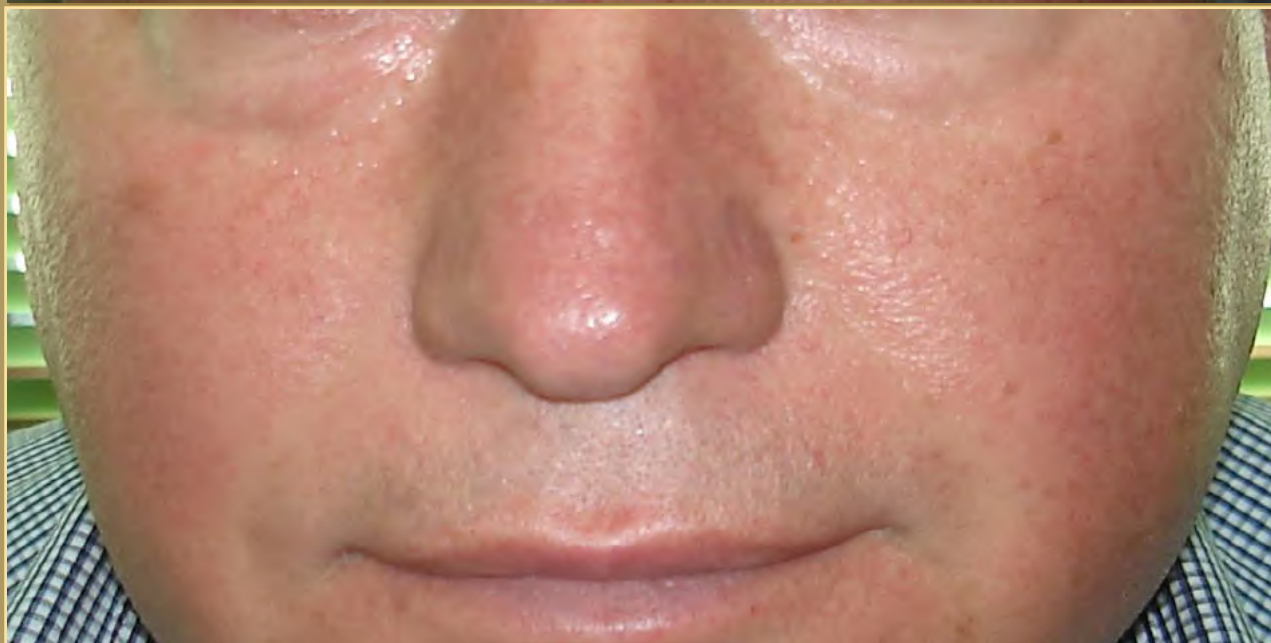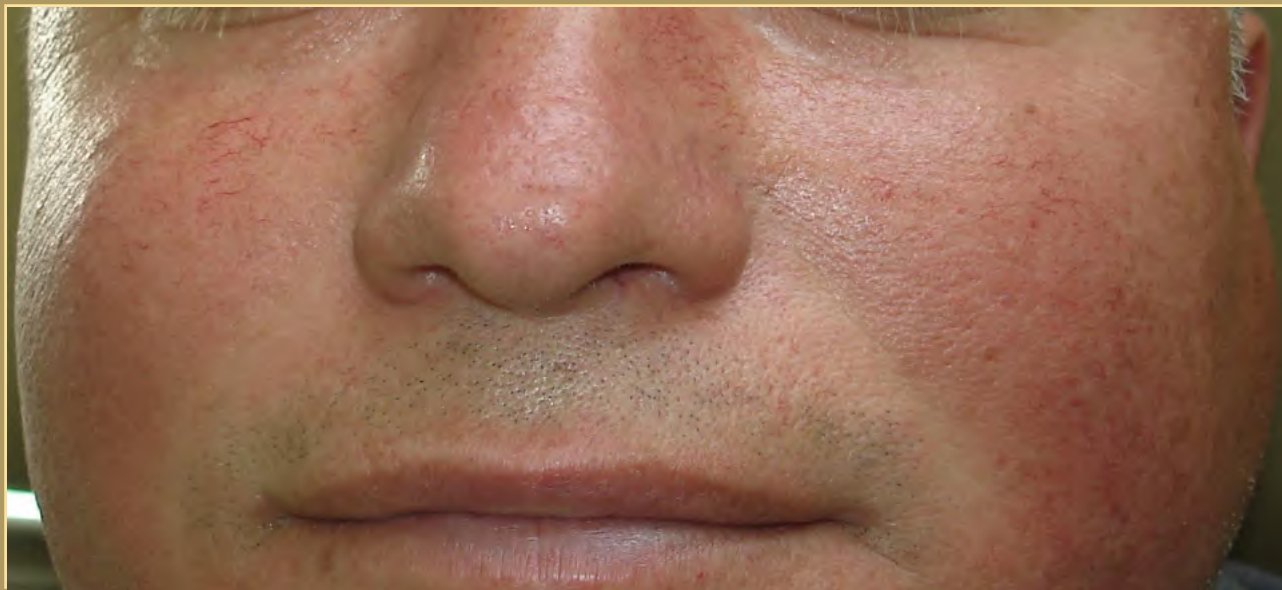Telangiectasia



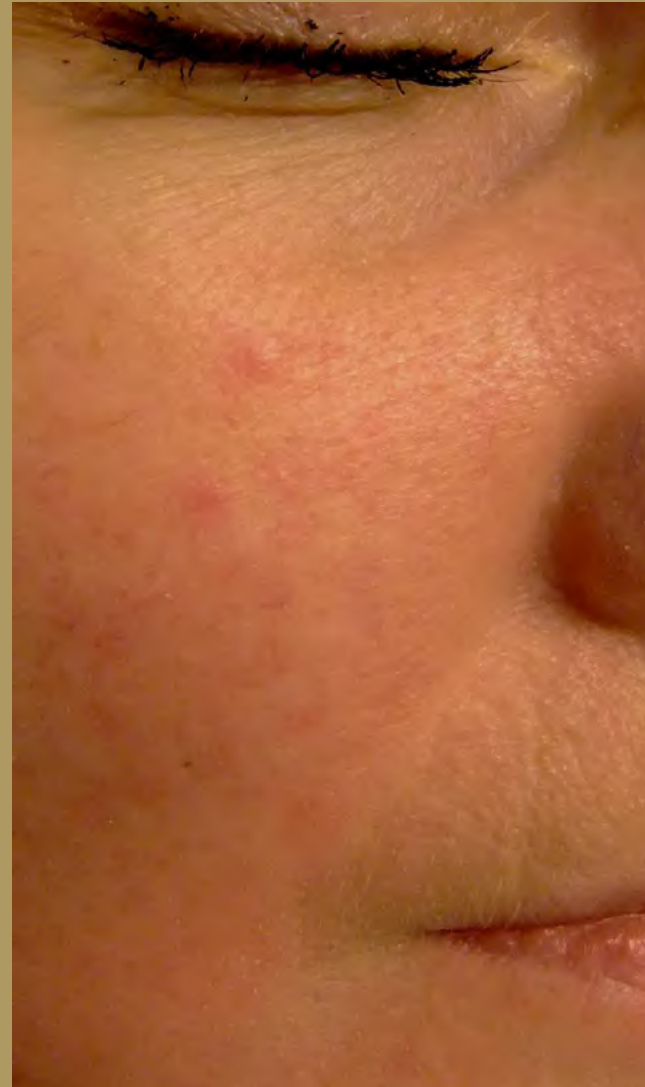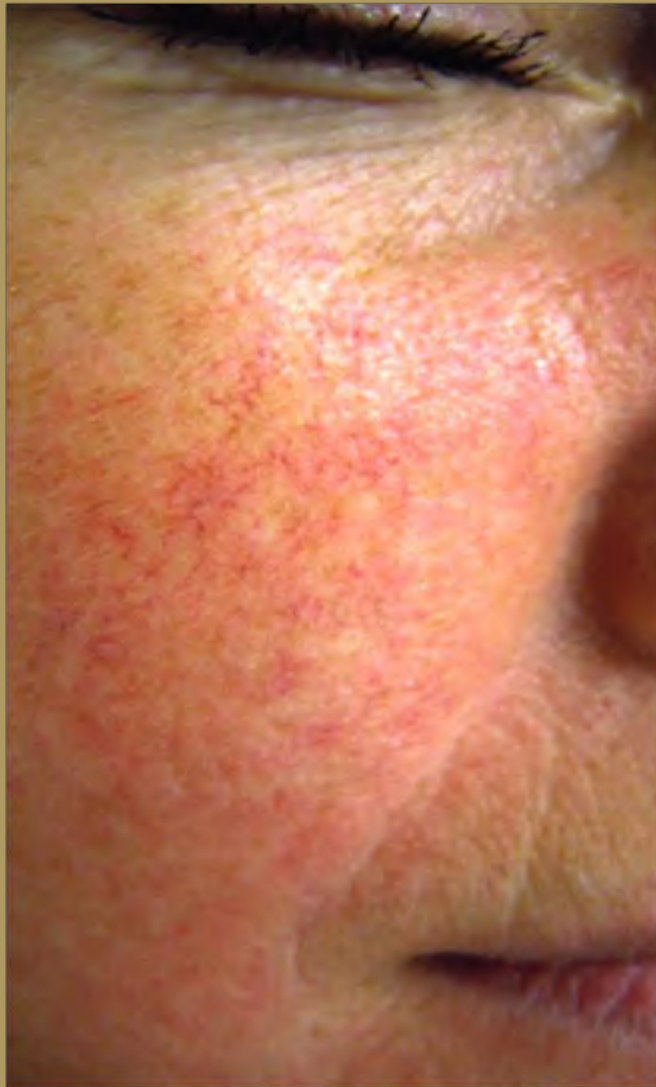Telangiectasia



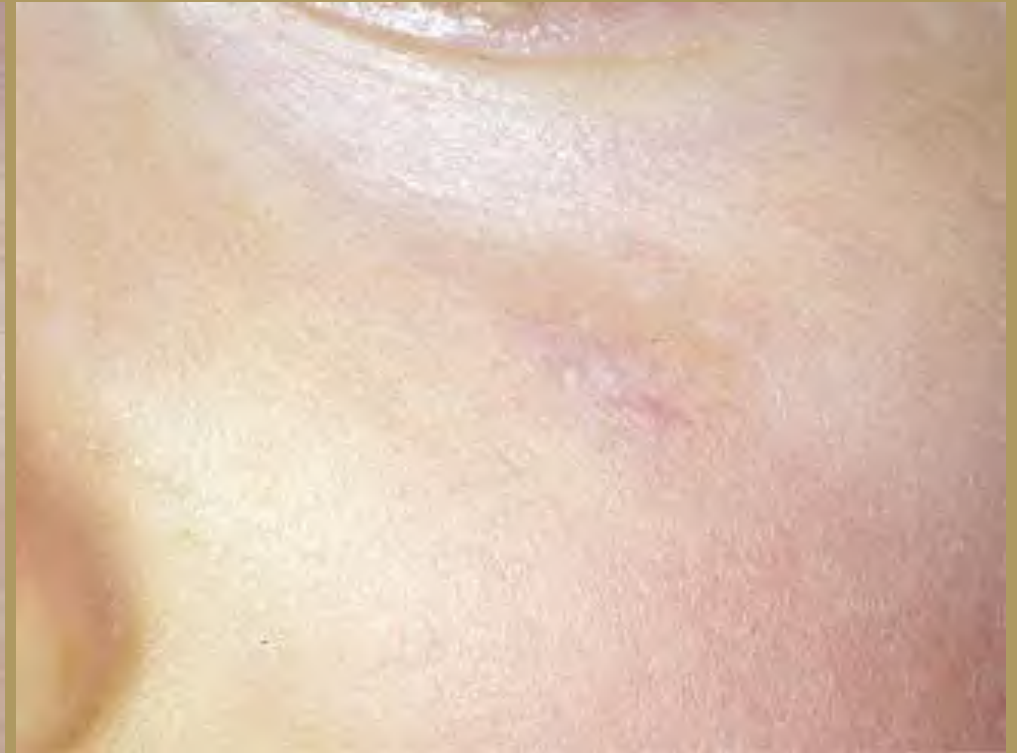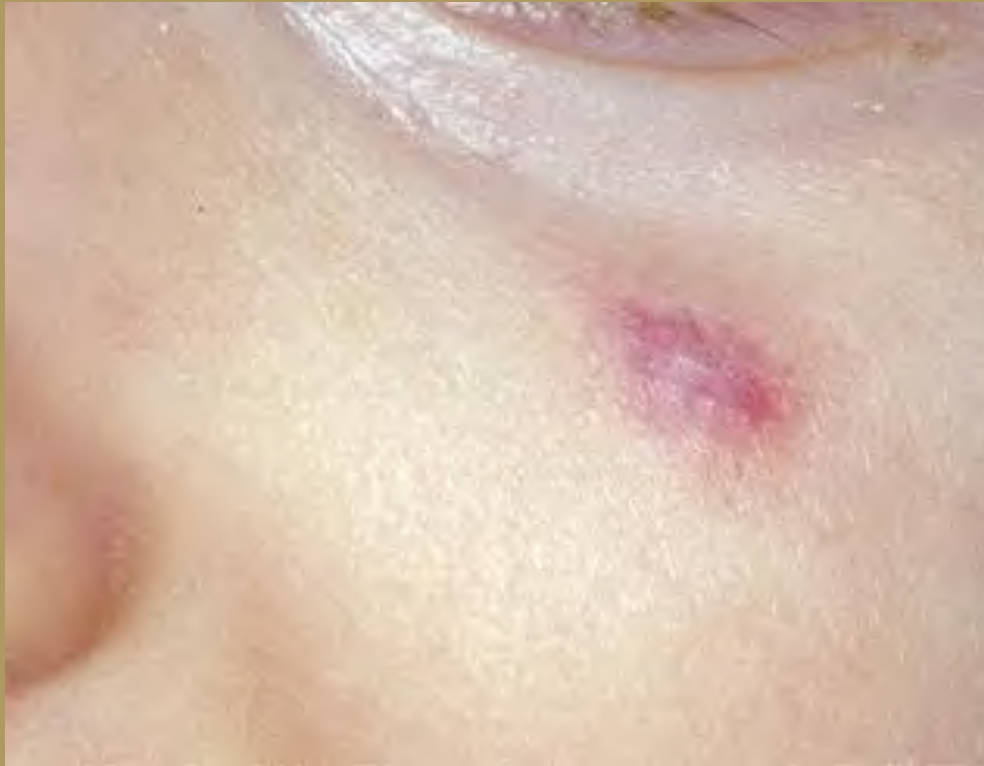Telangiectasia



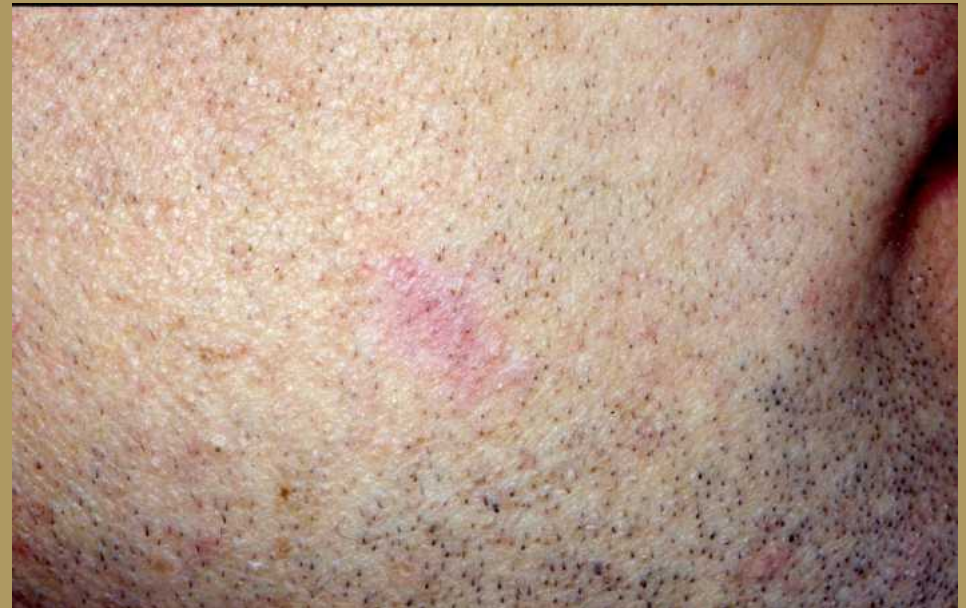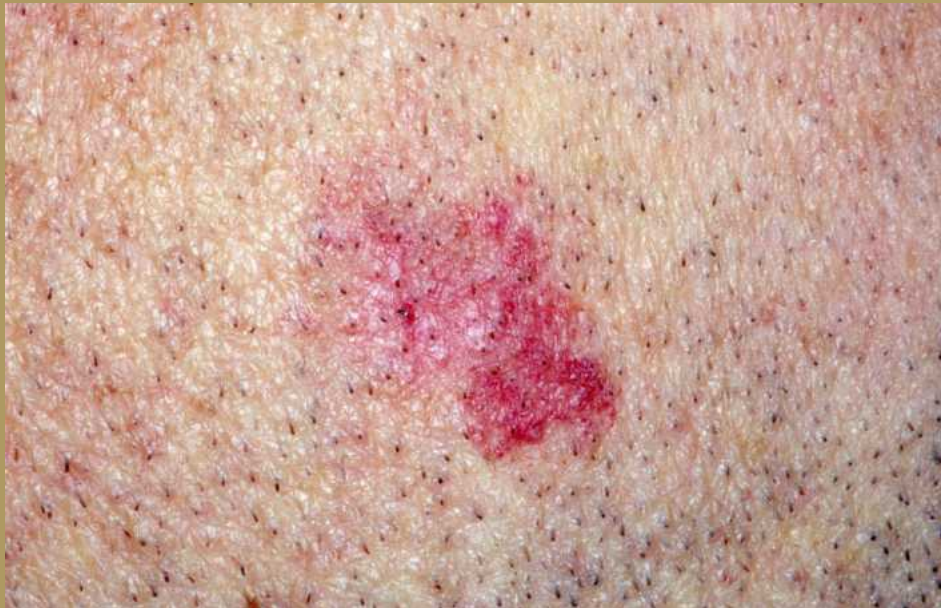Telangiectasia



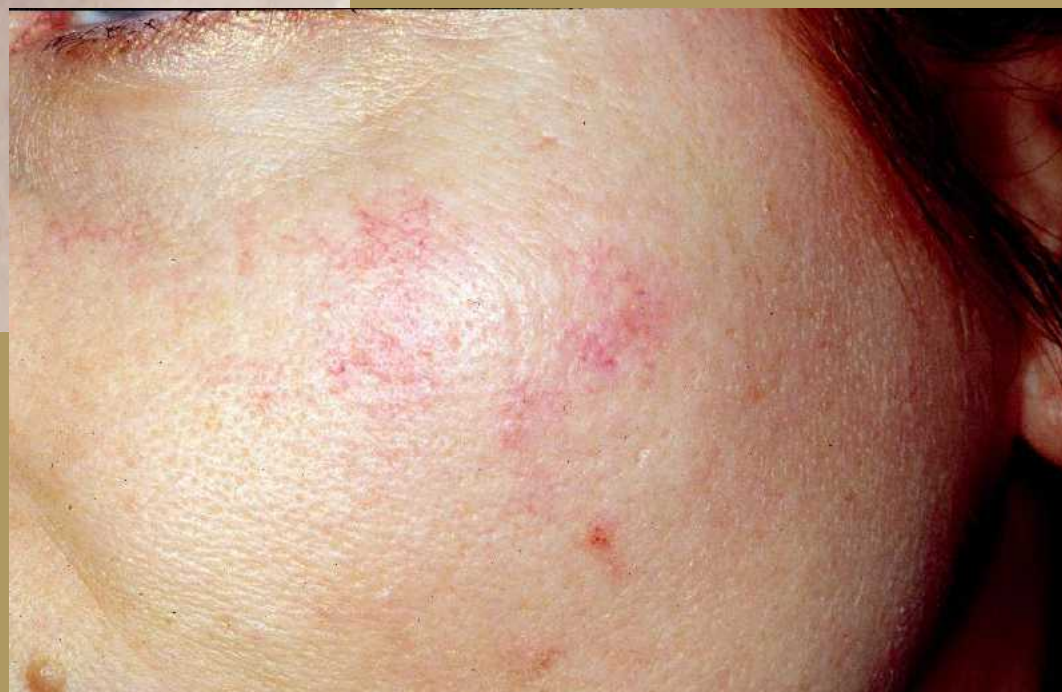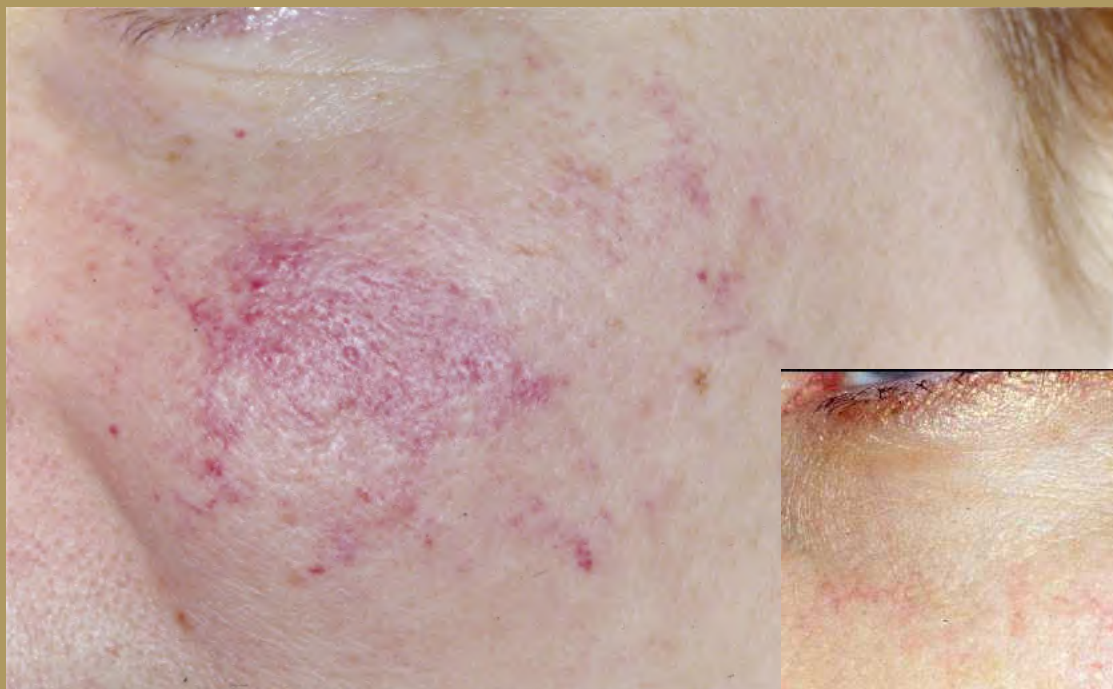
Hemangioma



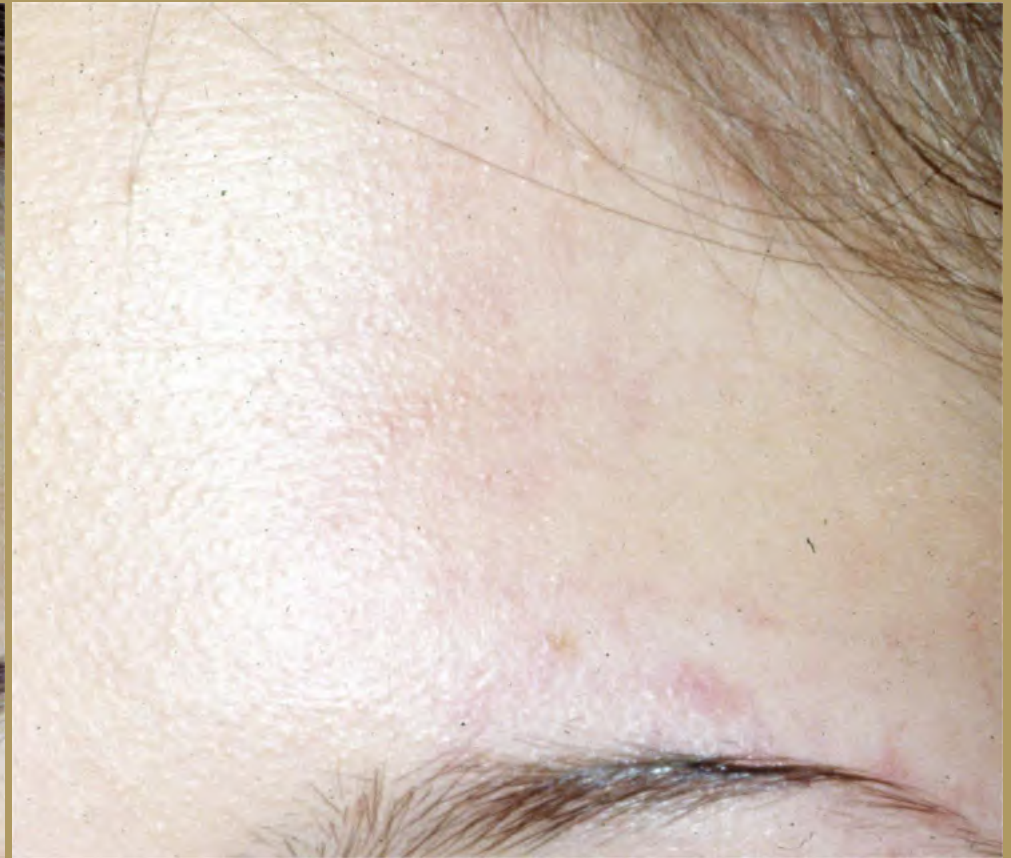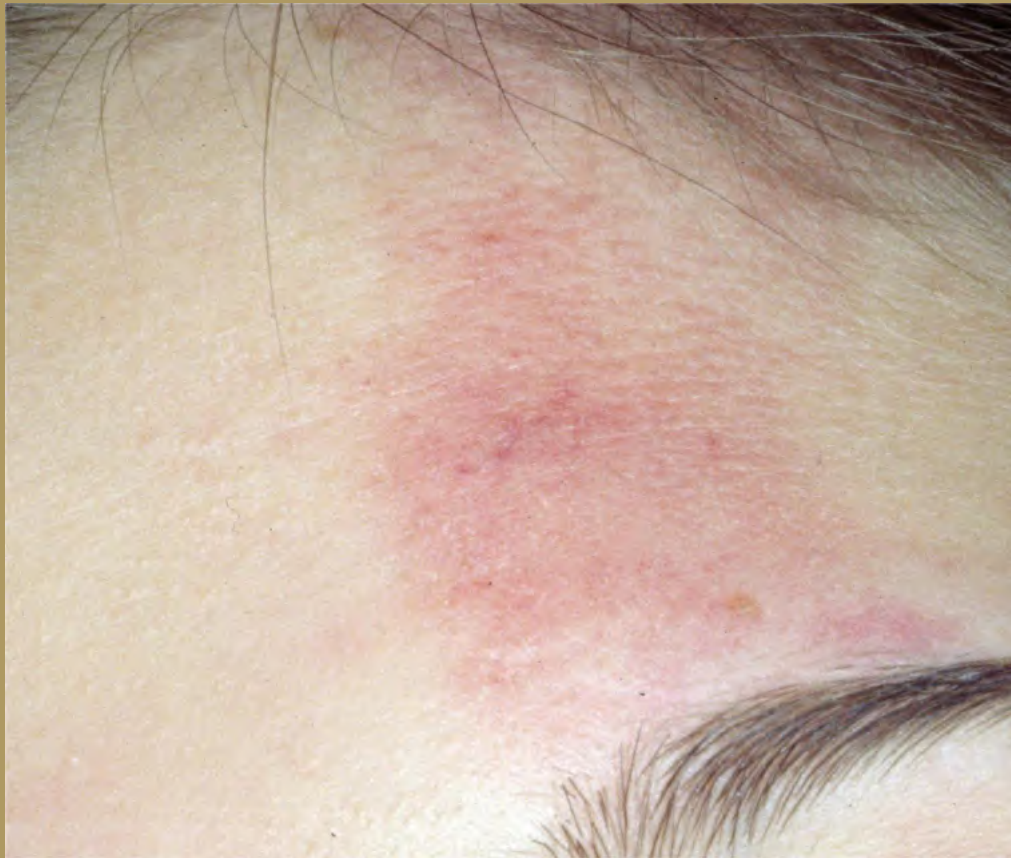Nevus flammeus



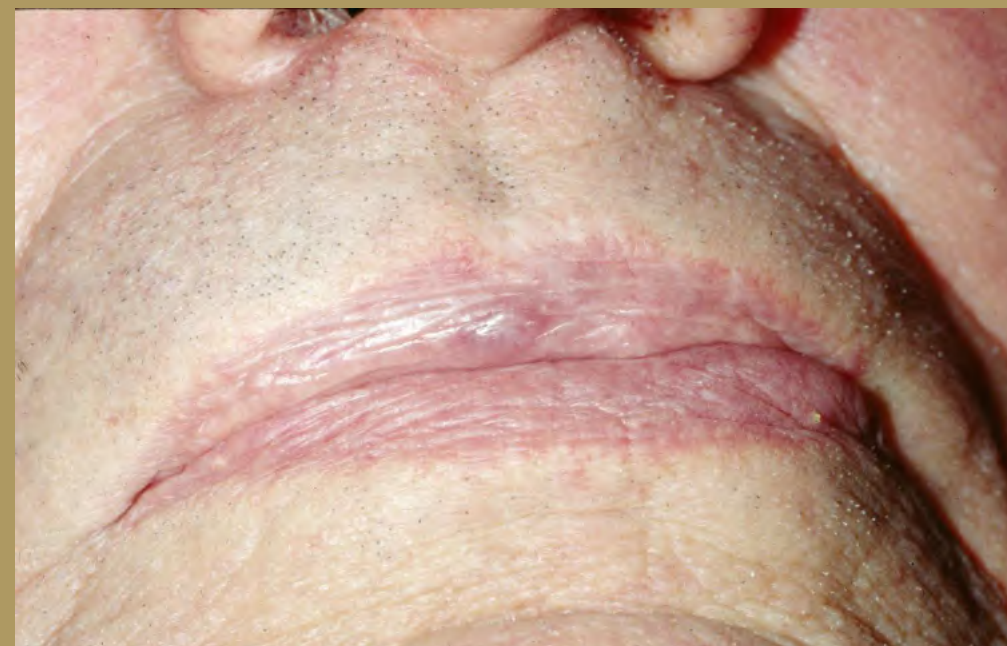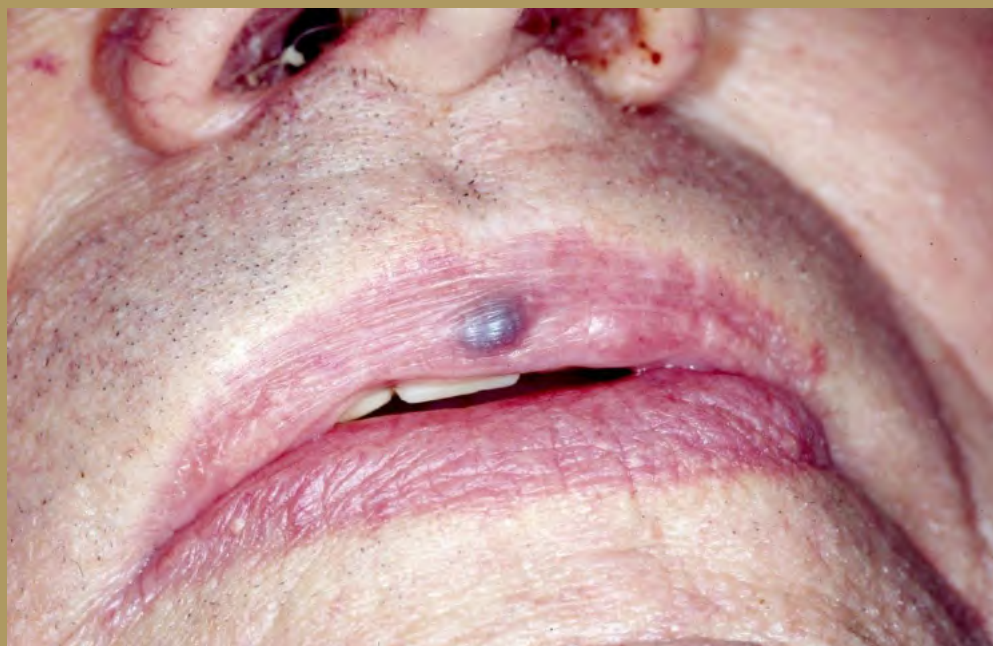Nevus flammeus



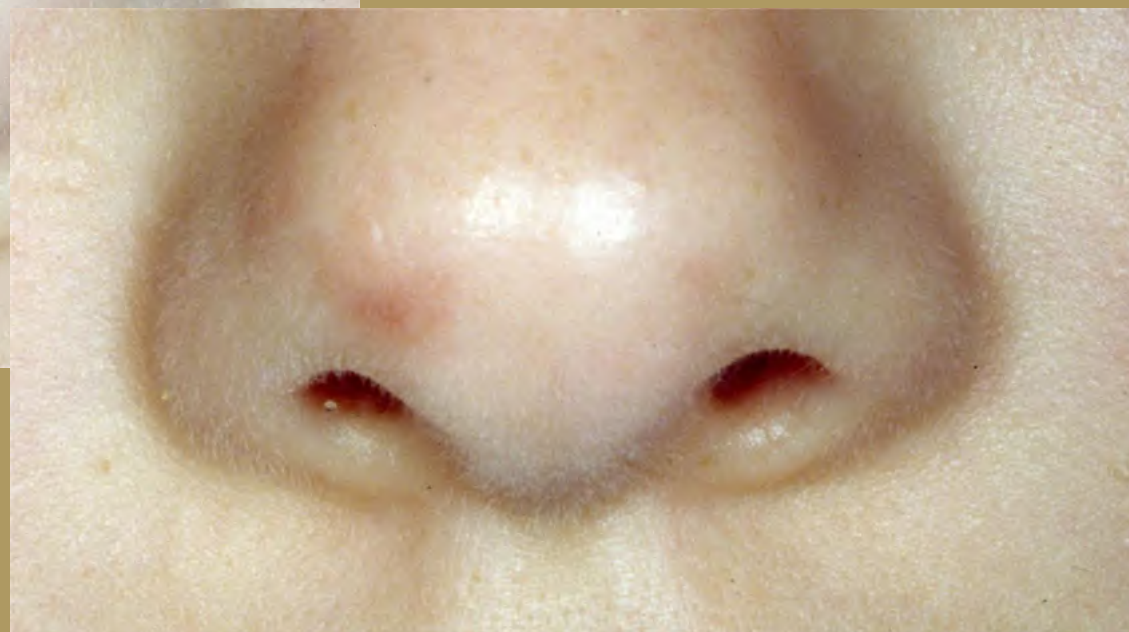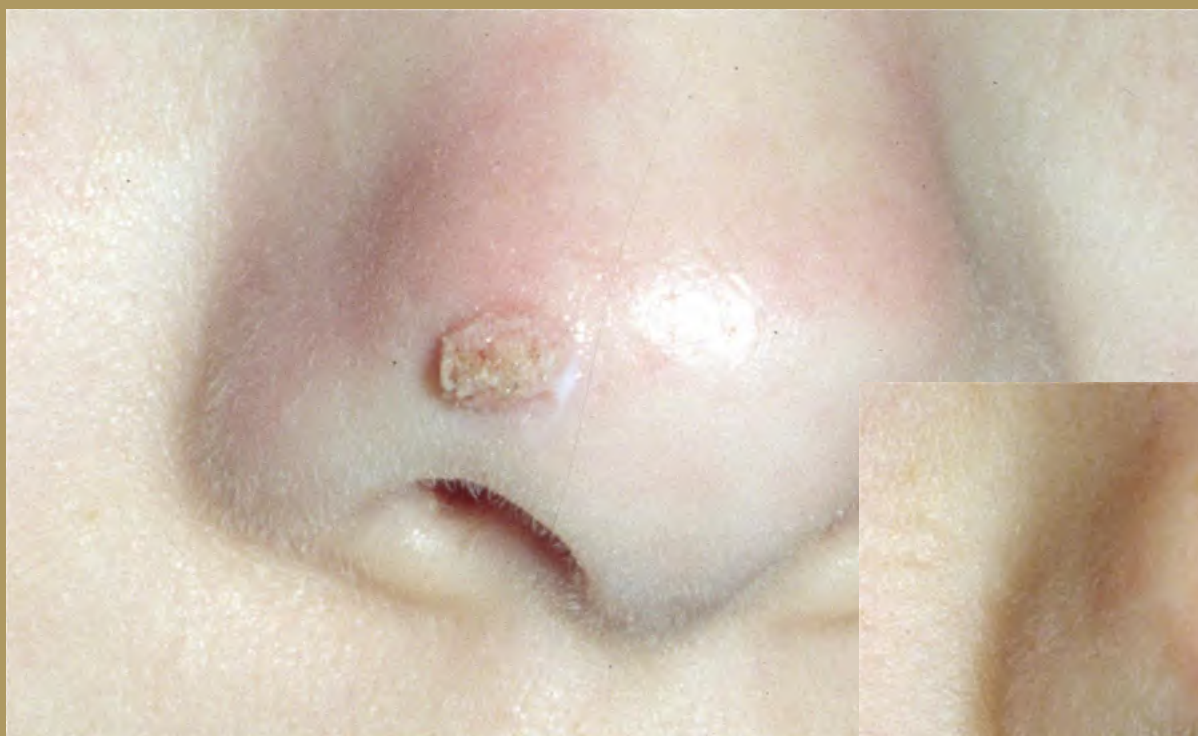Nevus flammeus



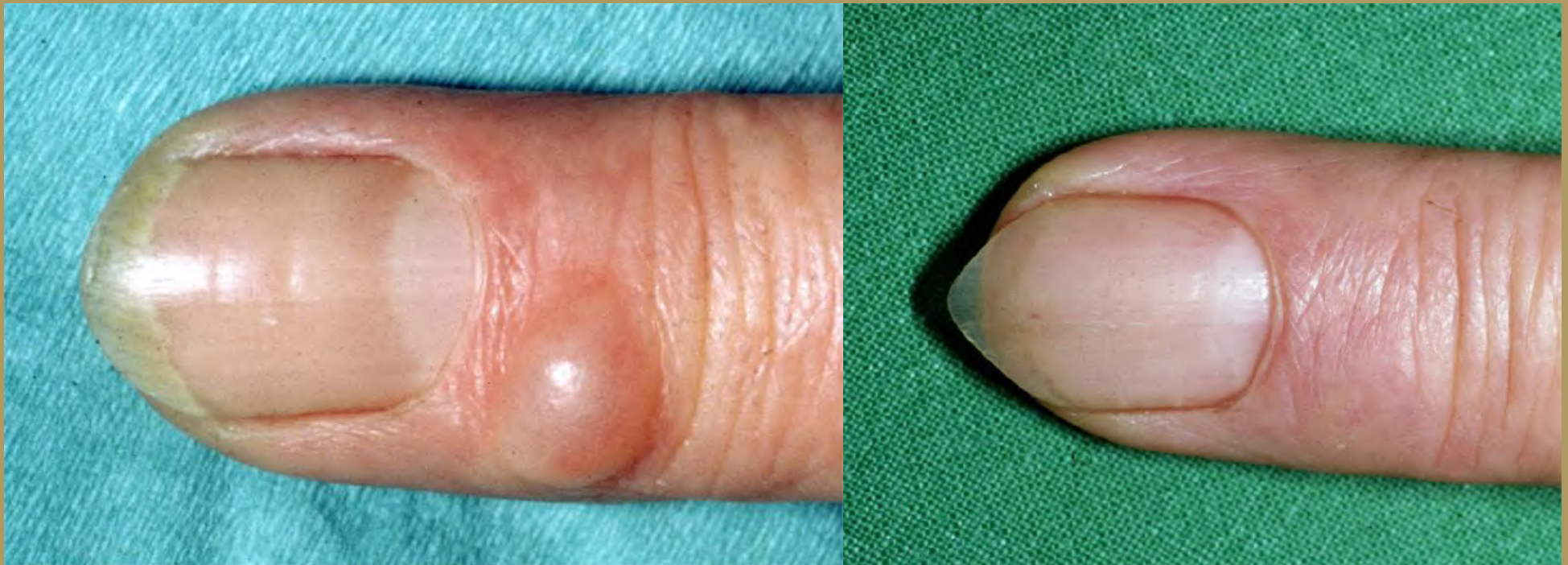Venous lake



Wart

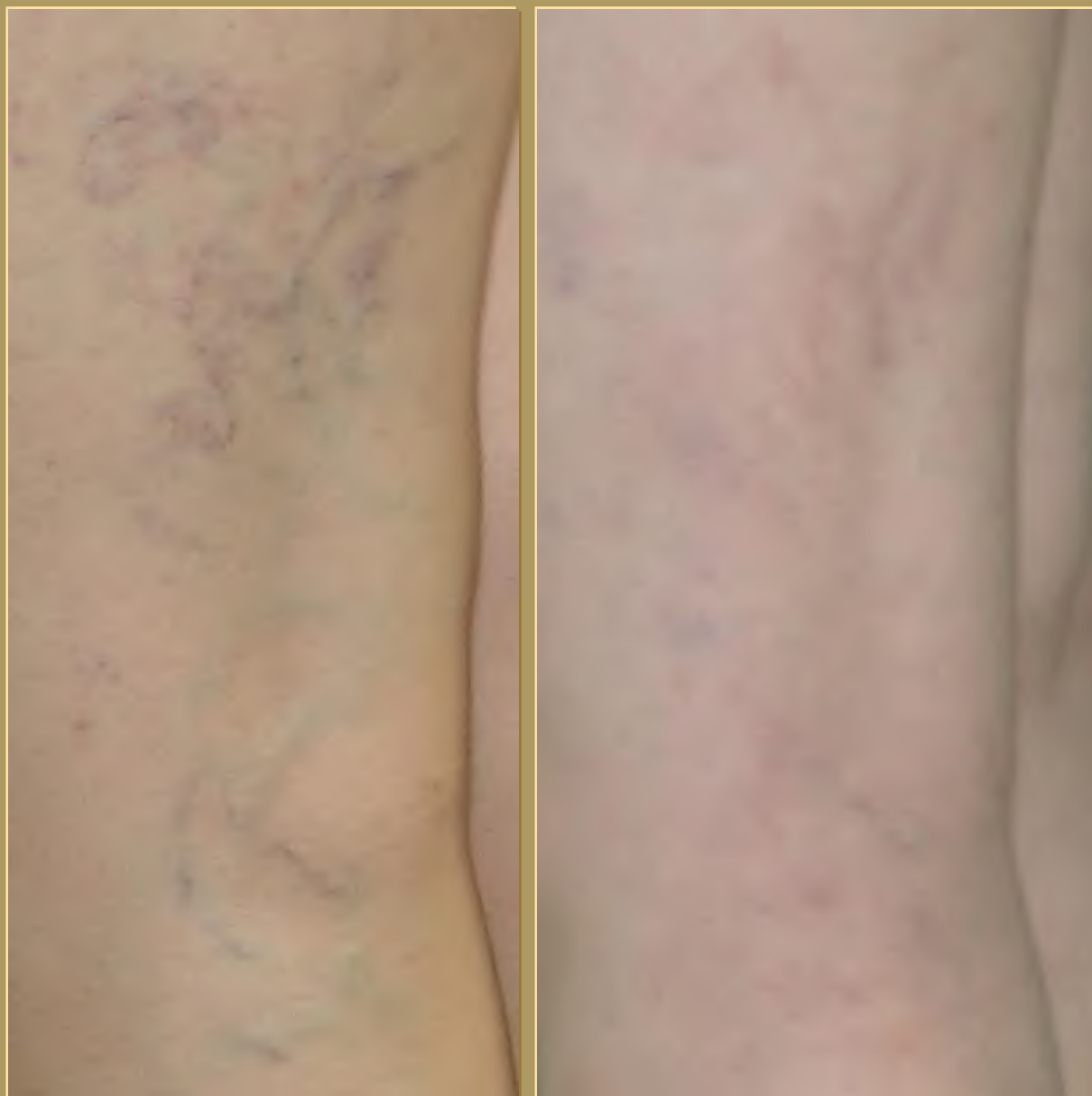

Dorsal cyst

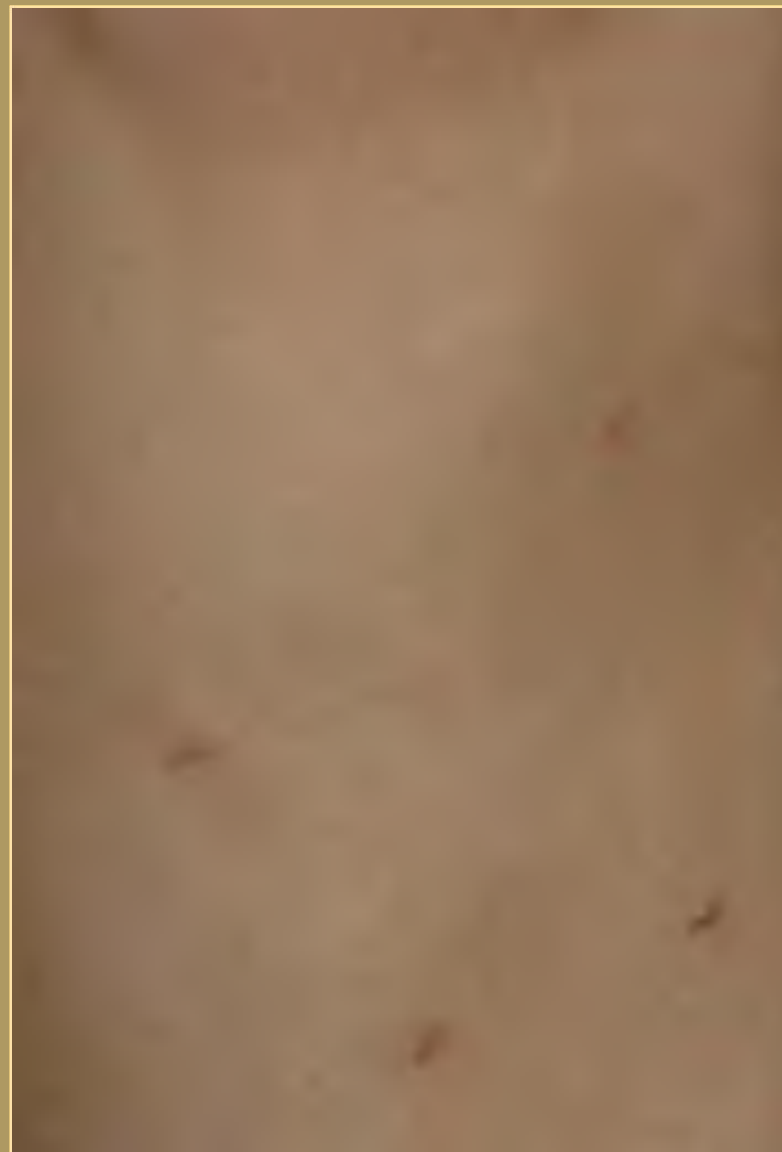
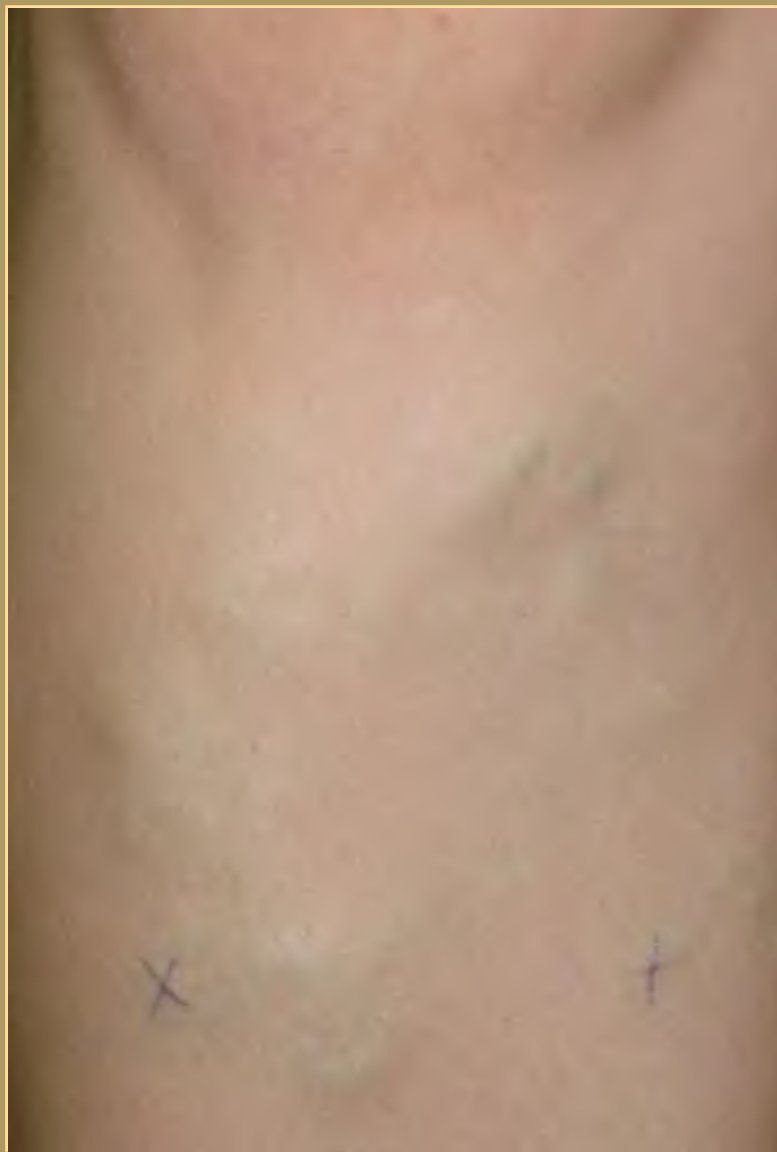
QuadroStarPRO⁹⁴⁰ (940 nm)

EVLT

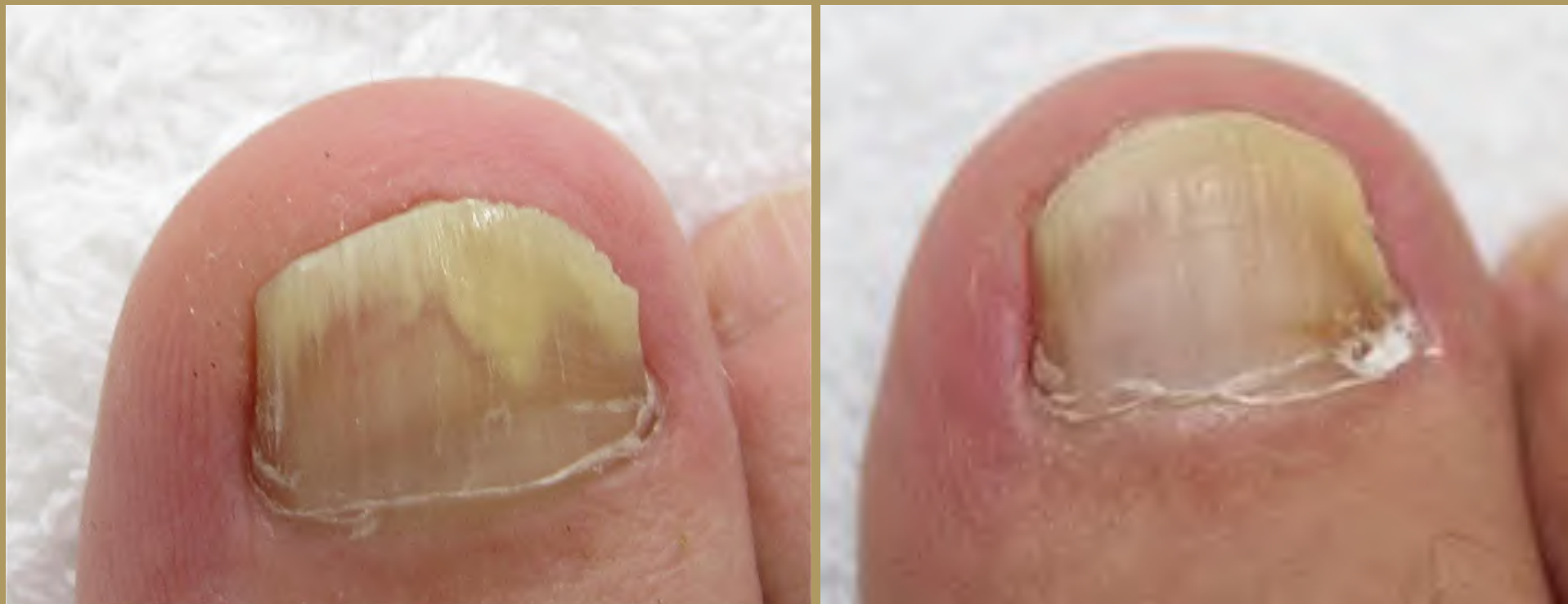

EVLT

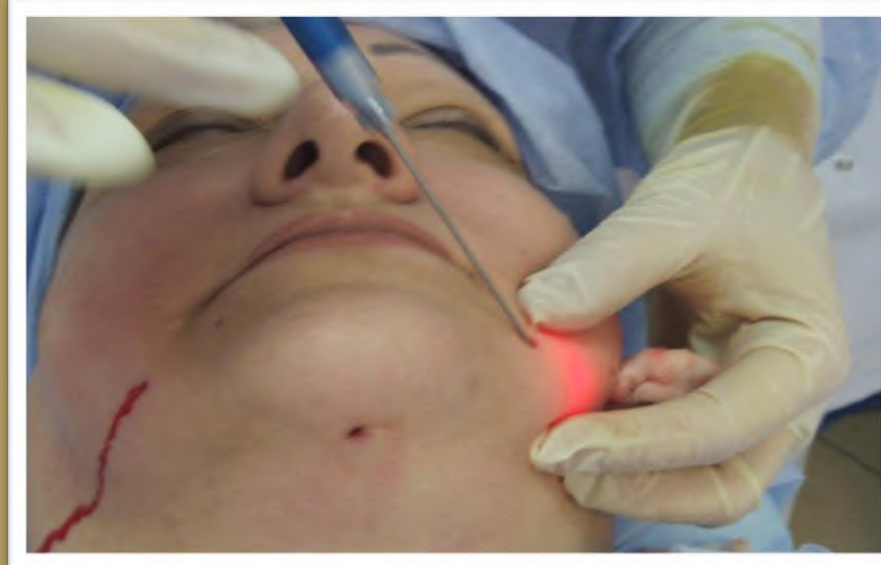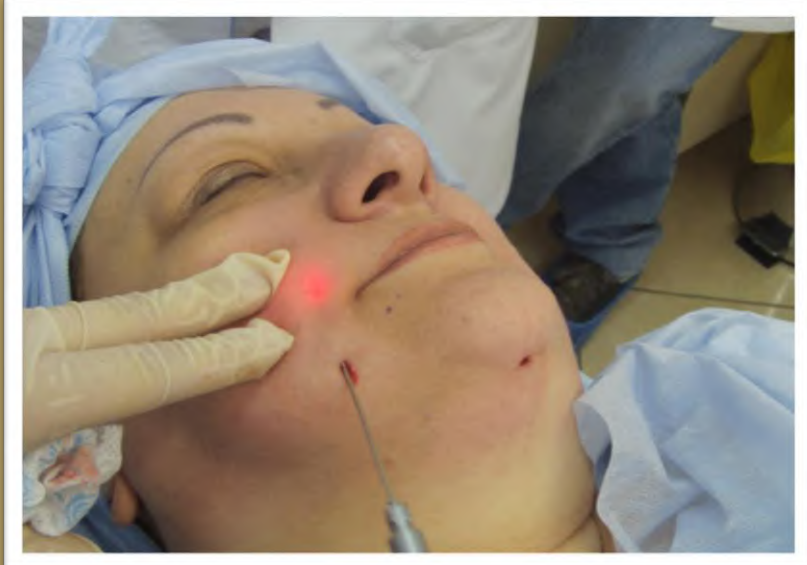
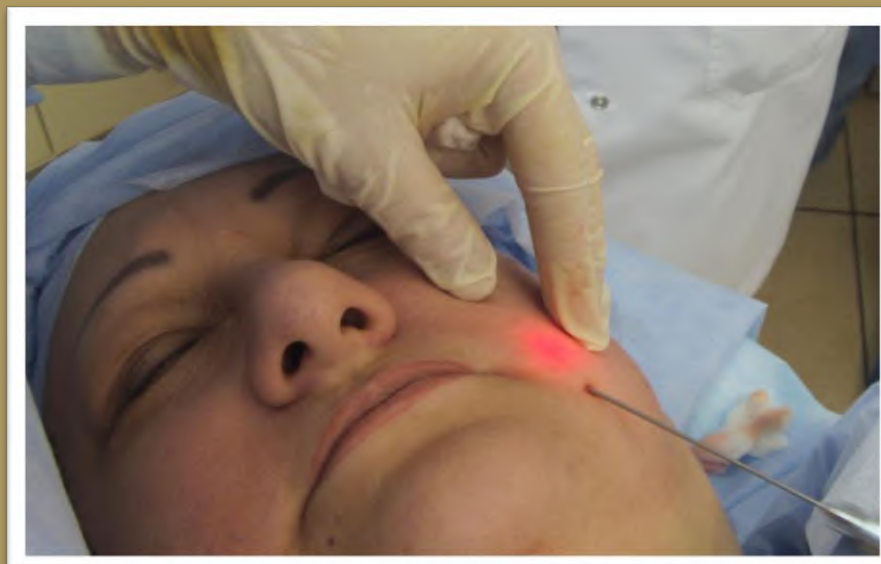
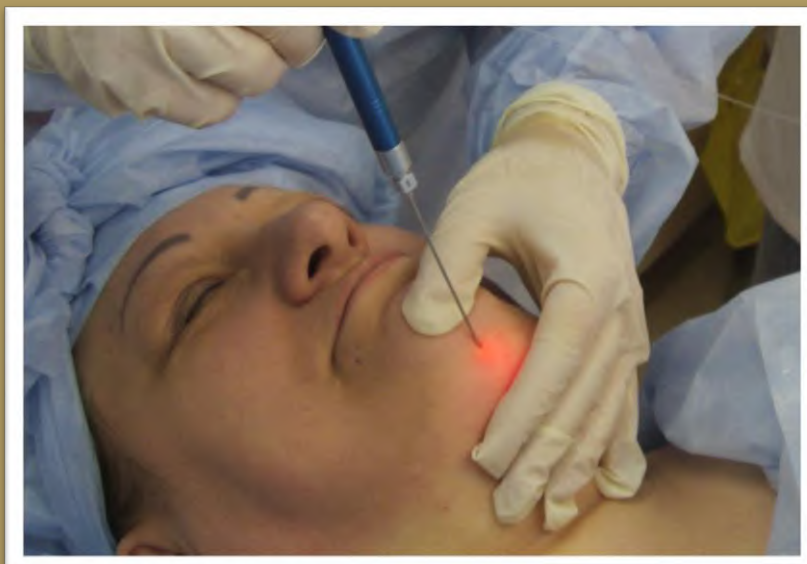


QuadroStarPRO⁹⁸⁰ (980 nm)

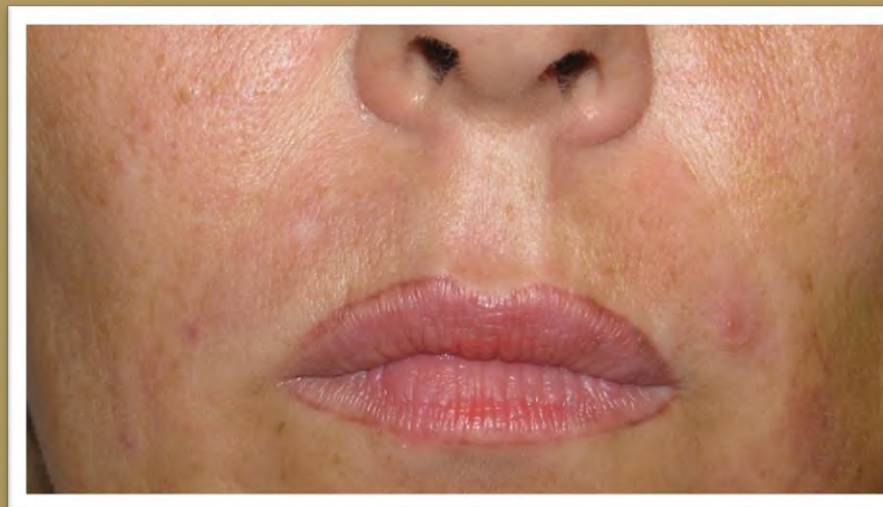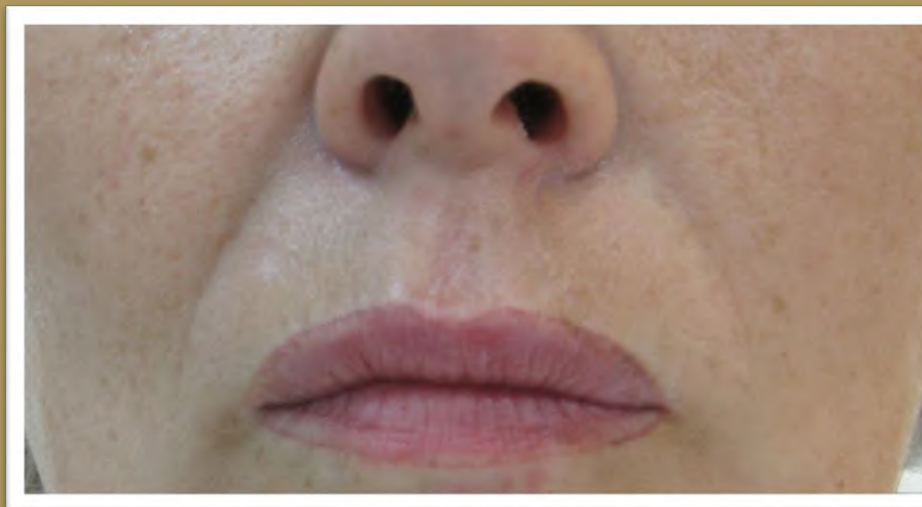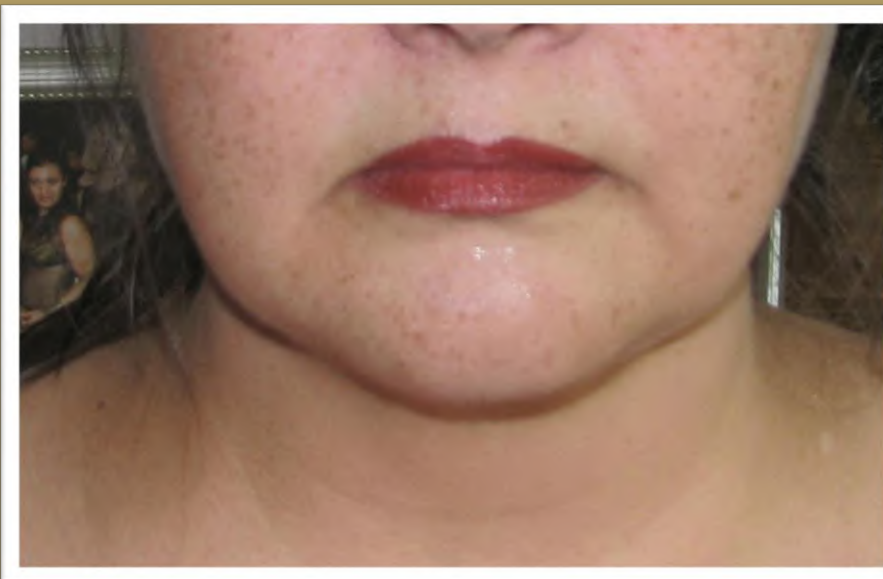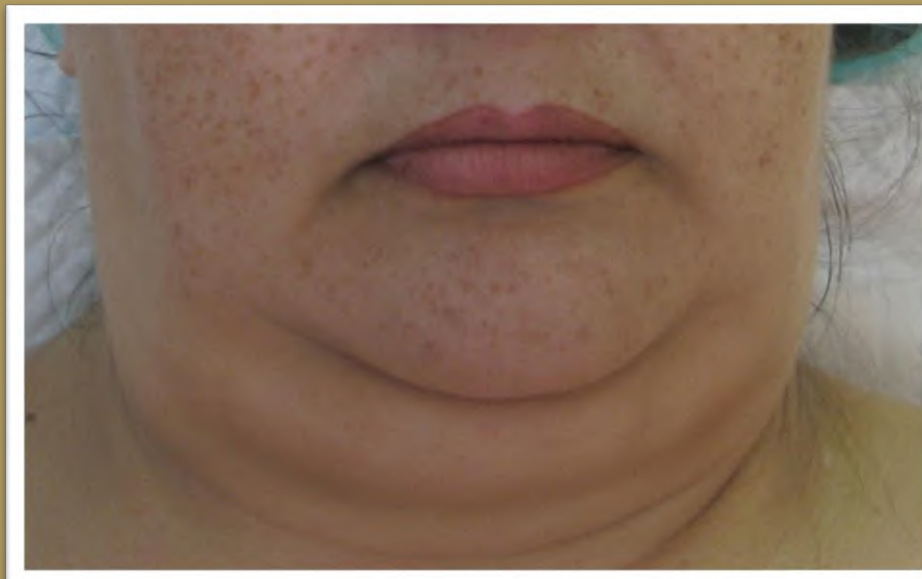
Onychomycosis




Laser assisted lipolysis



Laser assisted lipolysis



Laser assisted lipolysis



Copyright © Asclepion Laser Technologies GmbH.

All rights reserved.

Asclepion Laser Technologies GmbH

Brüsseler Str. 10 | 07747 Jena | Germany

www.aclepion.com

