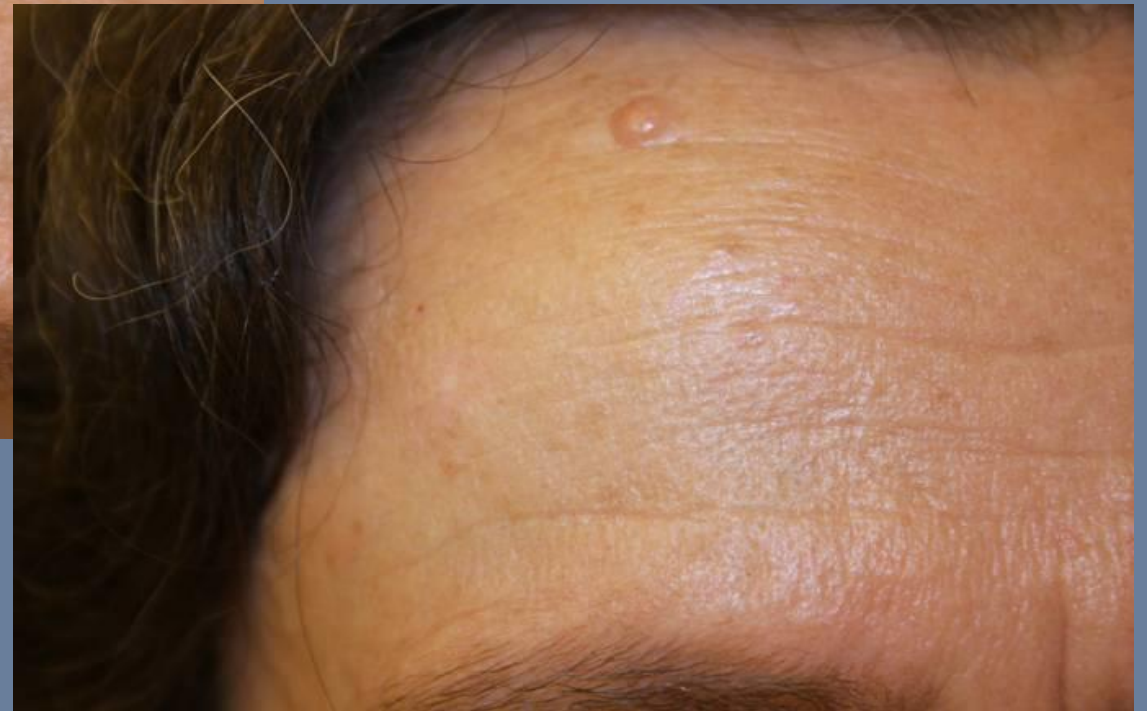
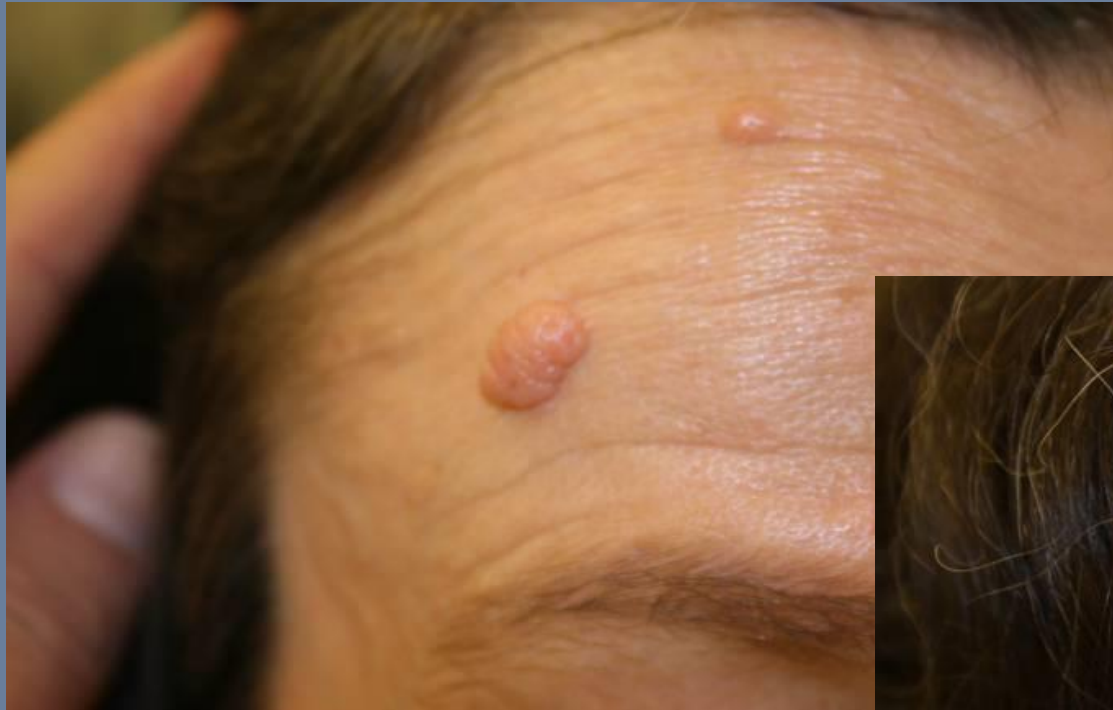Clinical Case Book

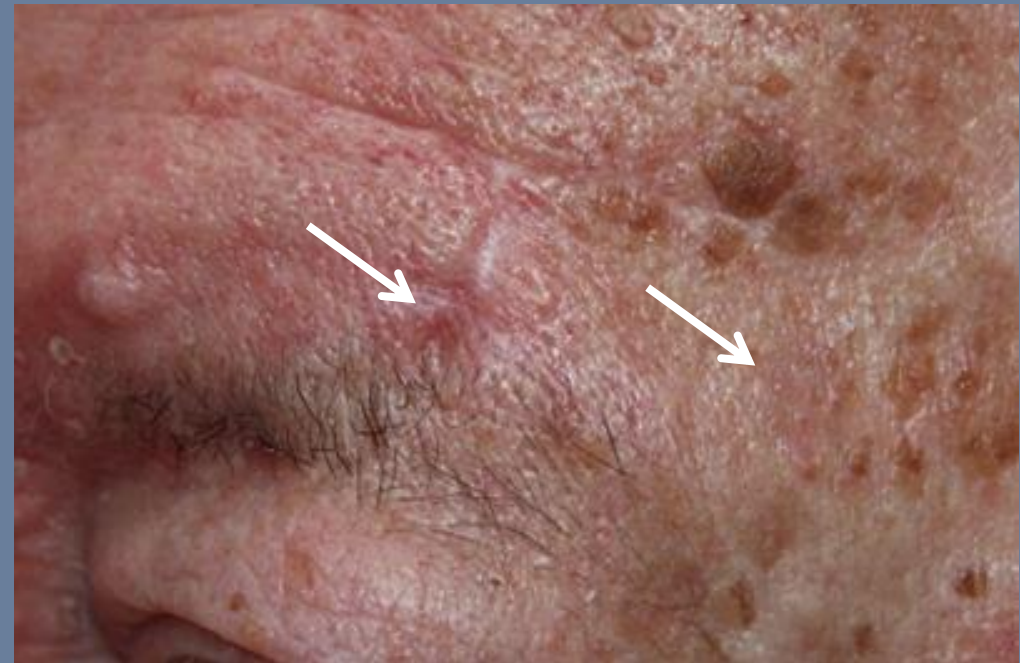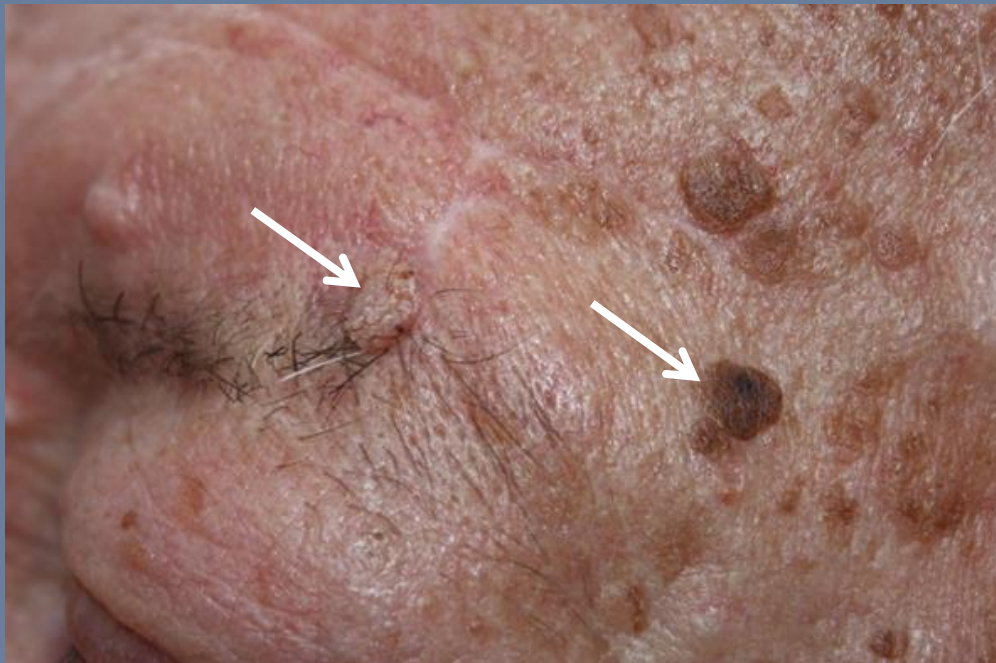Dermablade® Family

Er:YAG Ablation

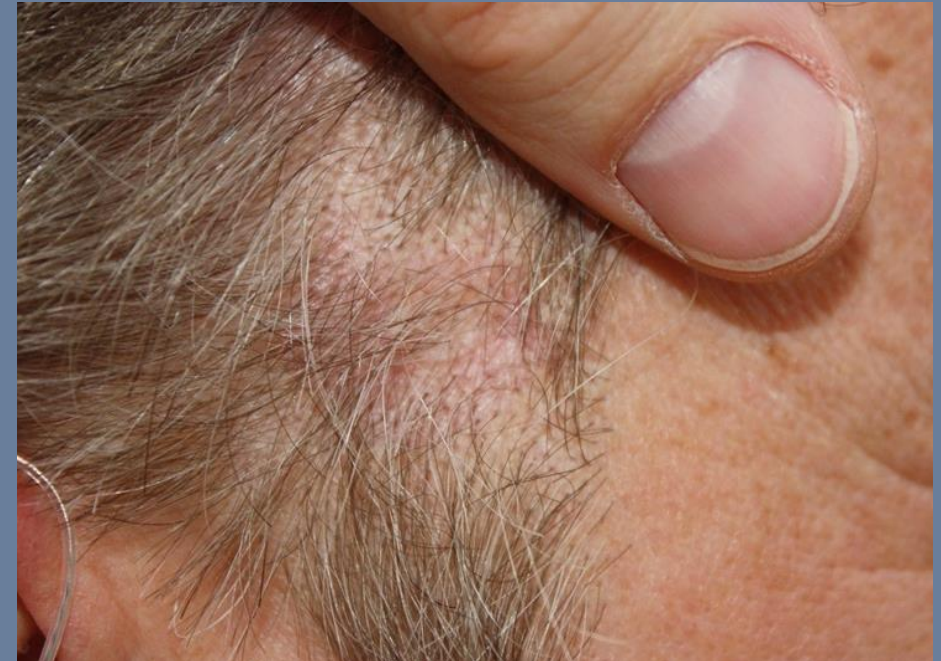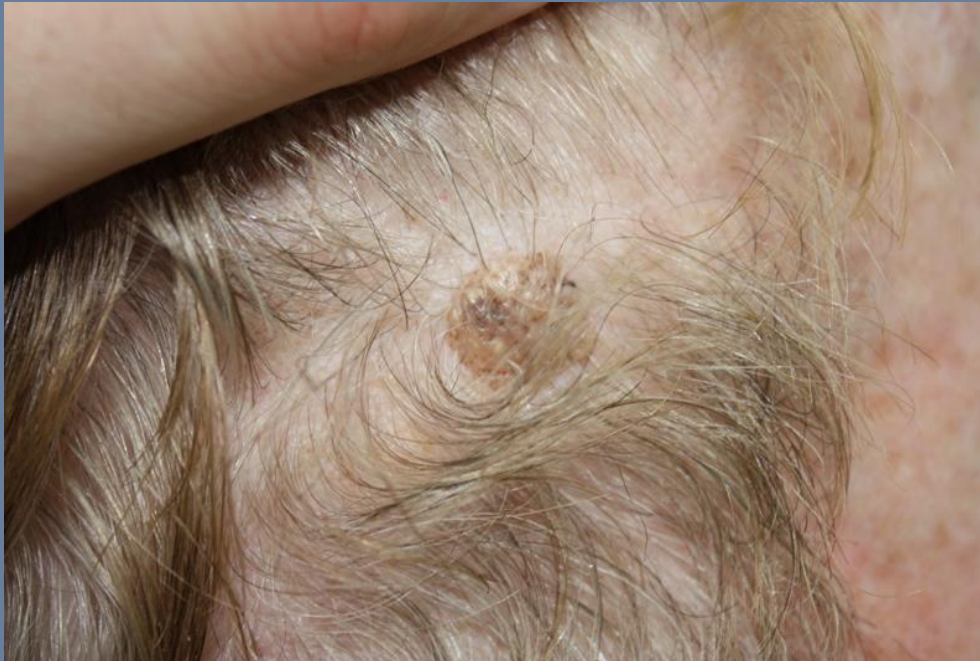Dermal nevus



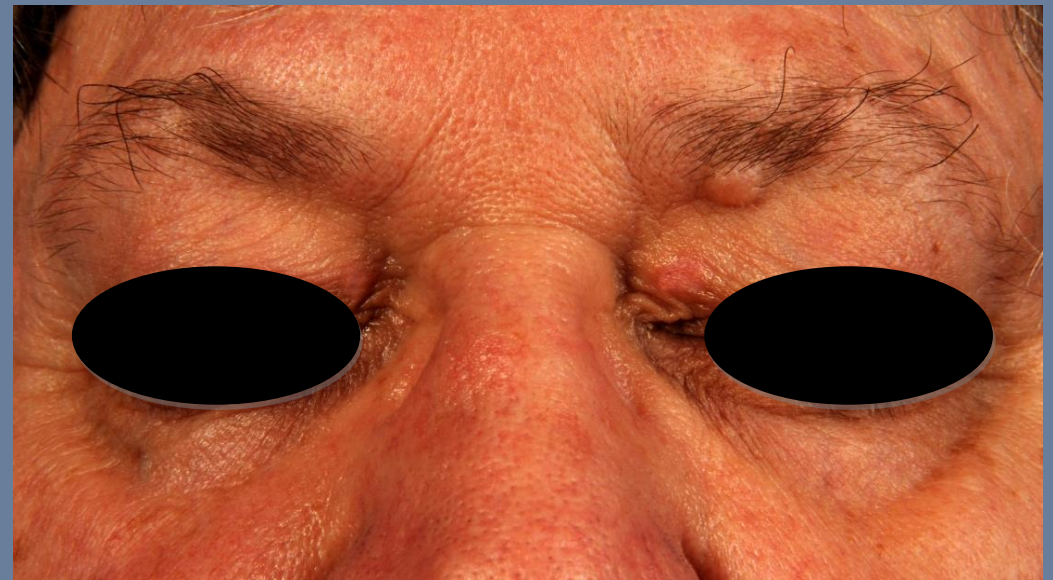
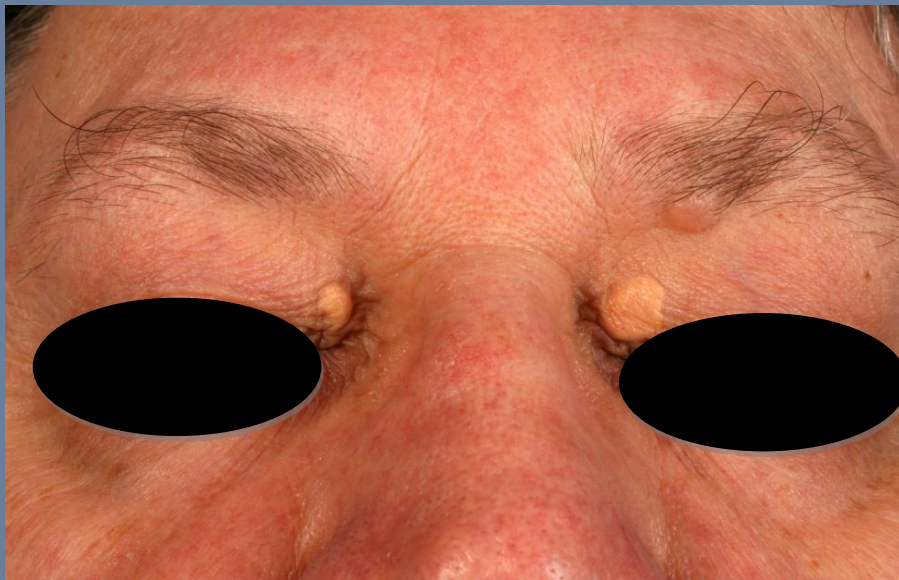Wart & Verruca seborrhoica



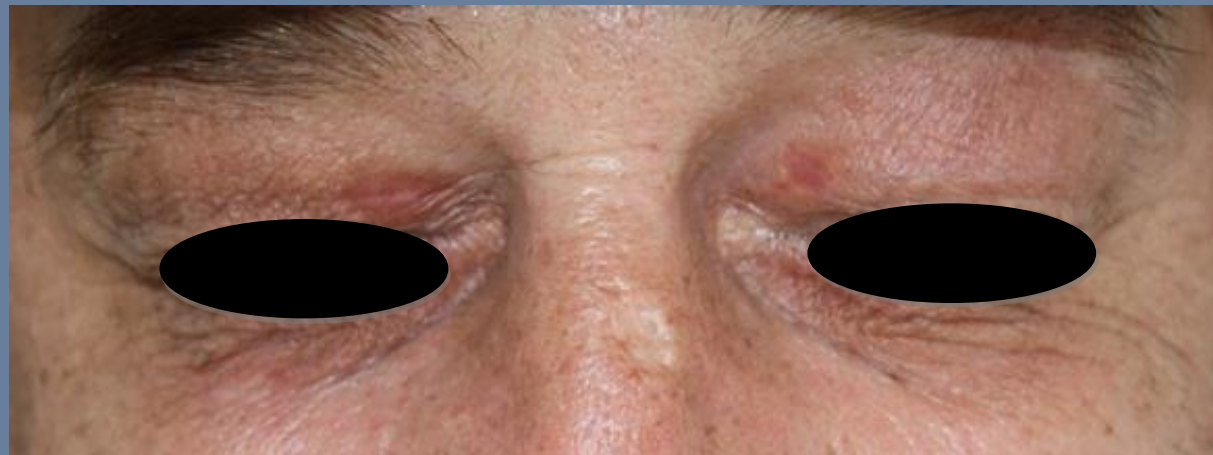
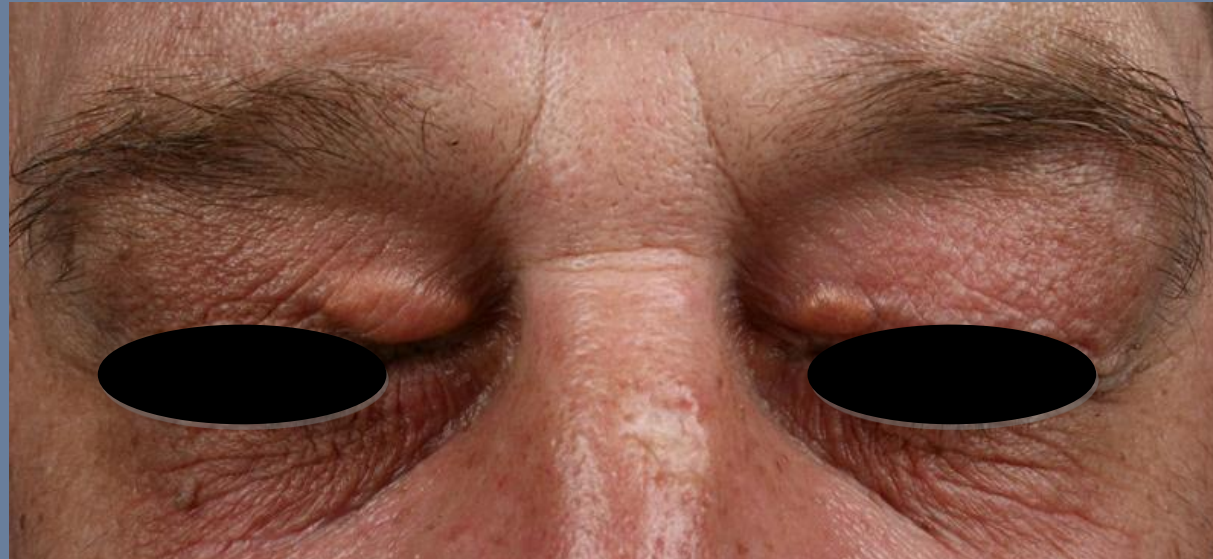Verruca seborrhoica



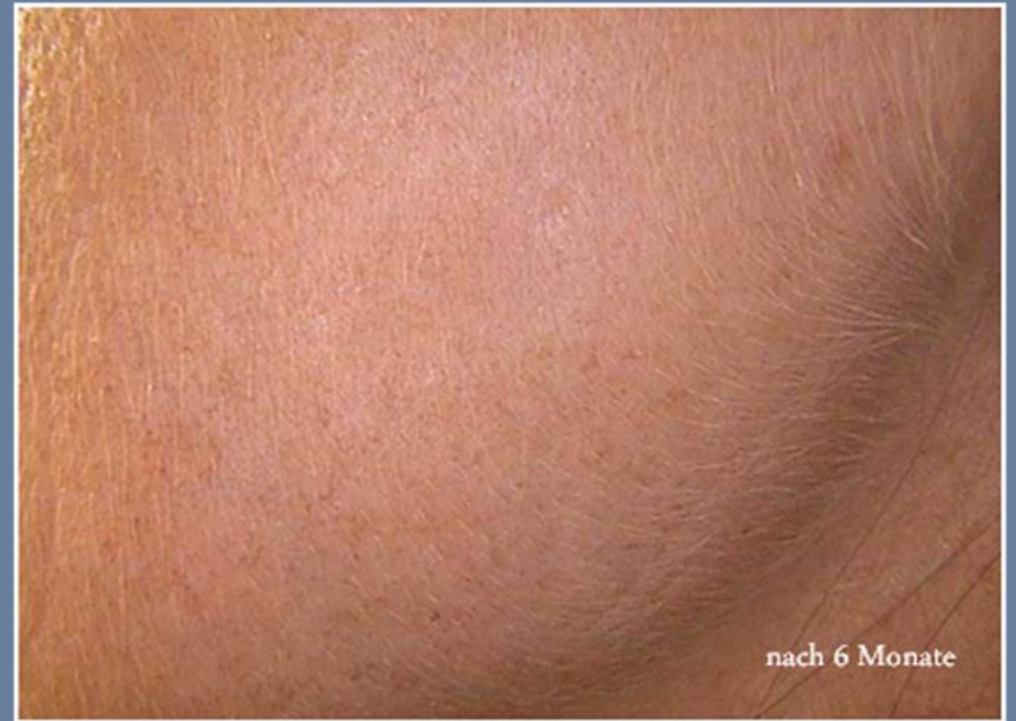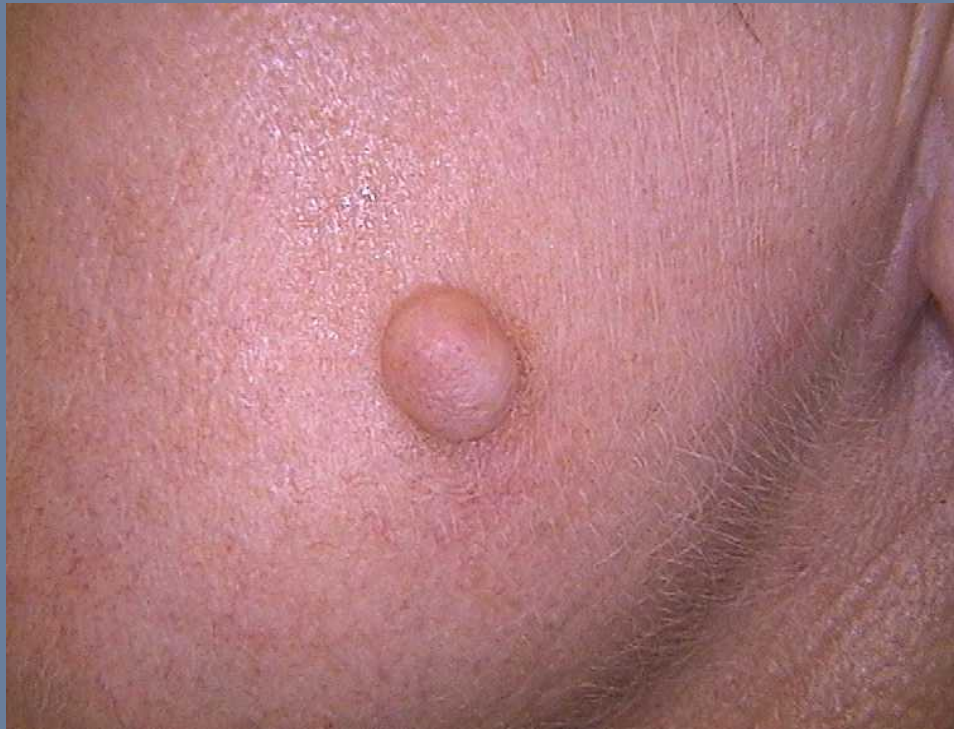Xanthelasma



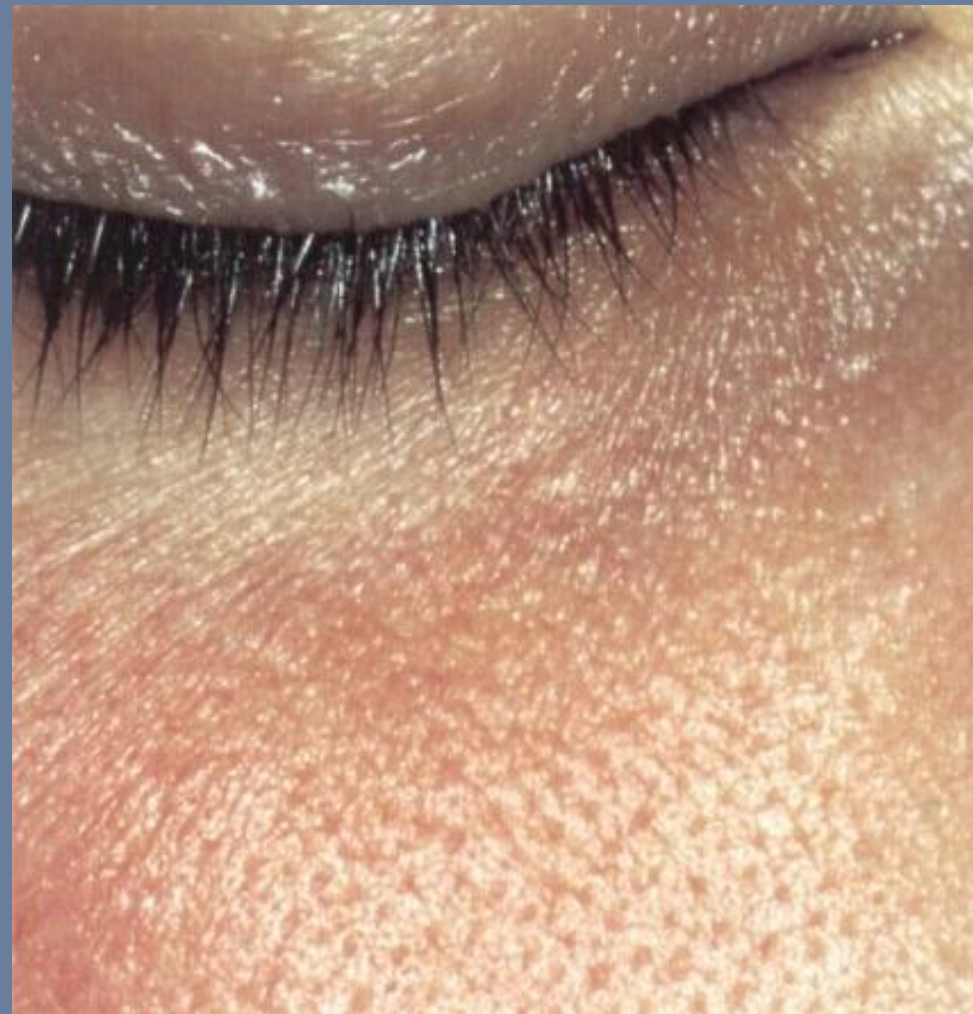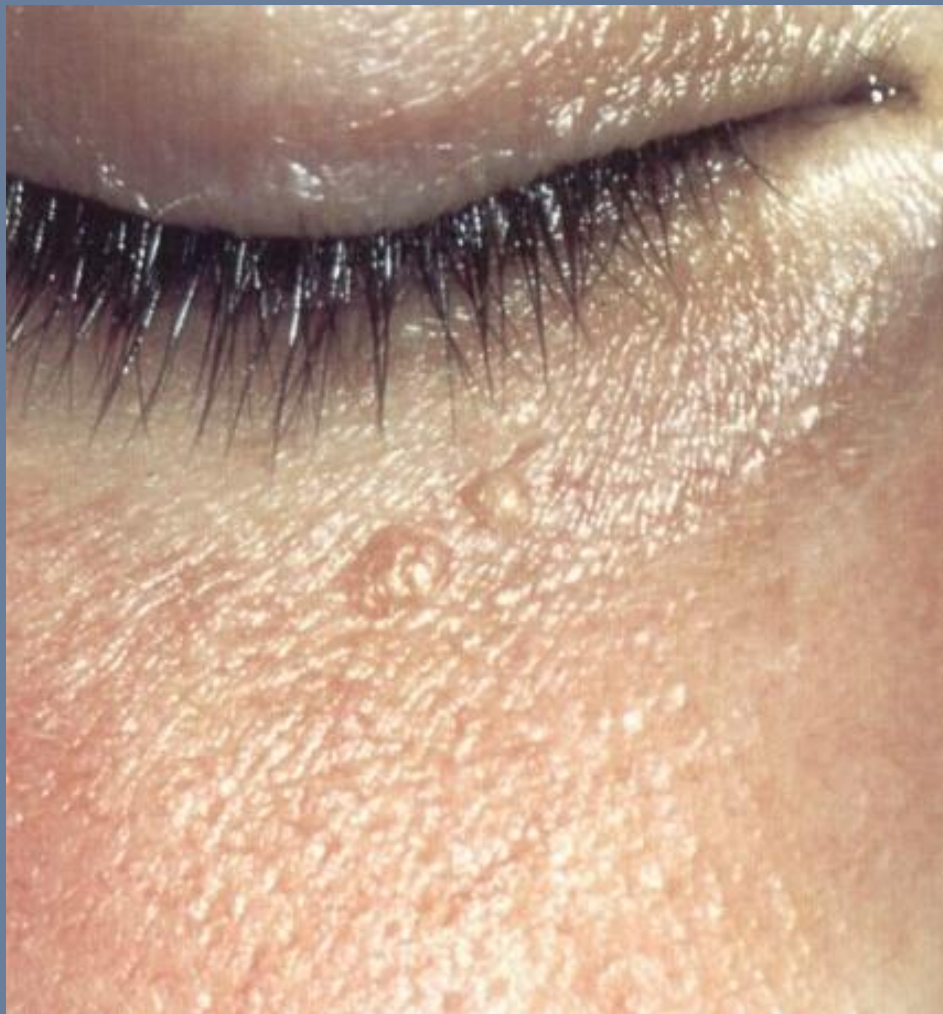Xanthelasma



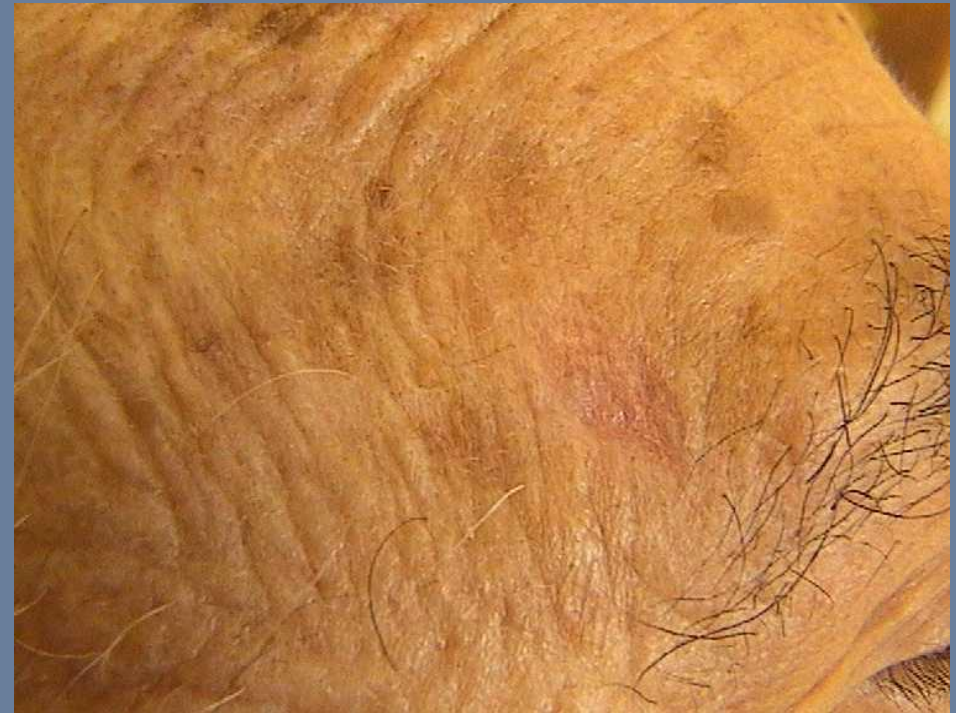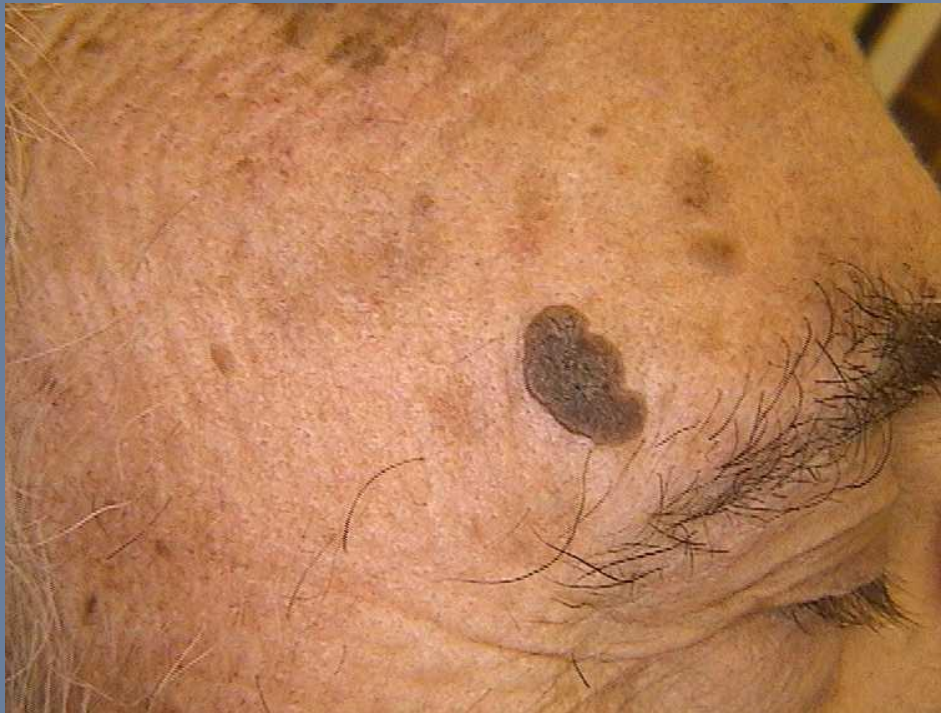Dermo-epidermal nevus



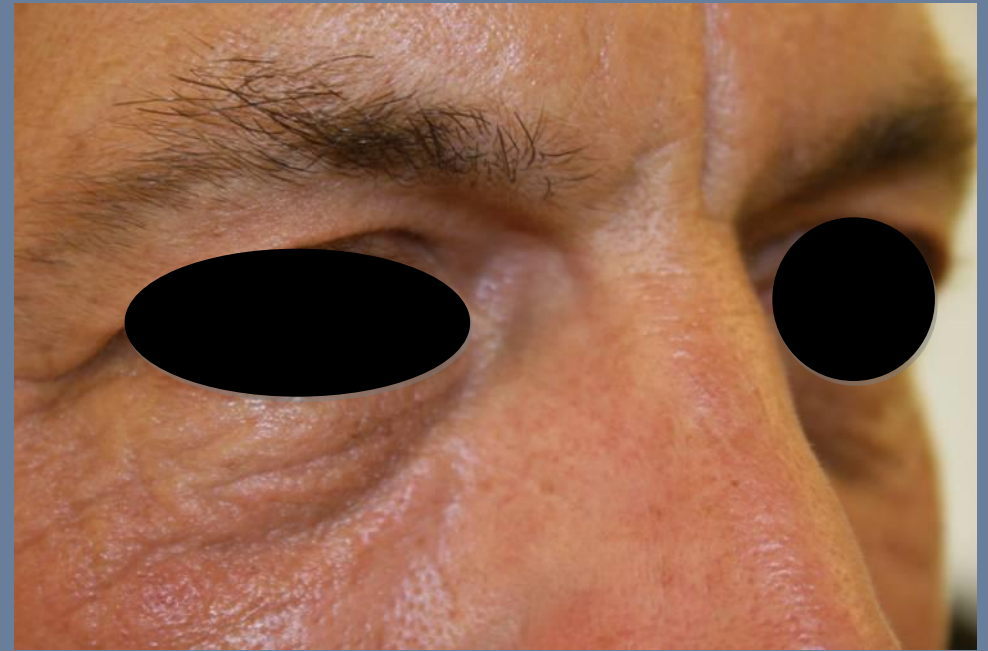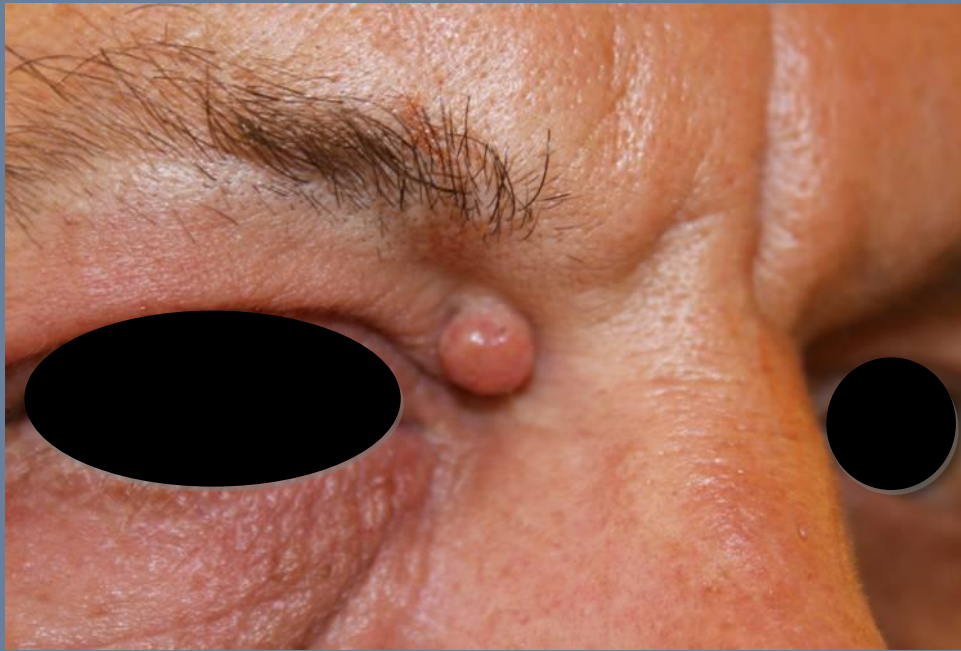Syringoma



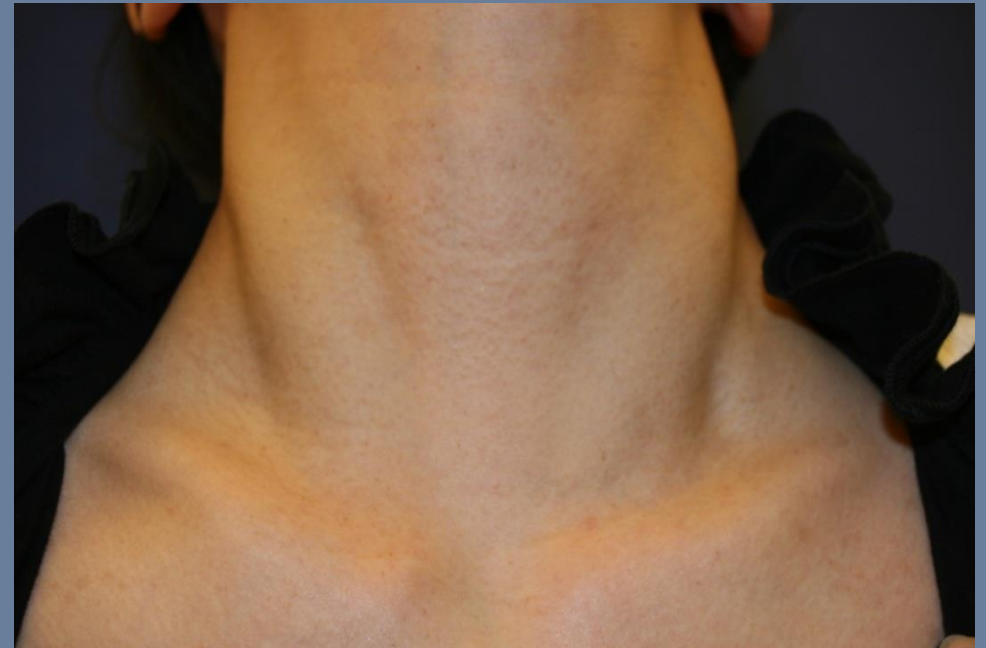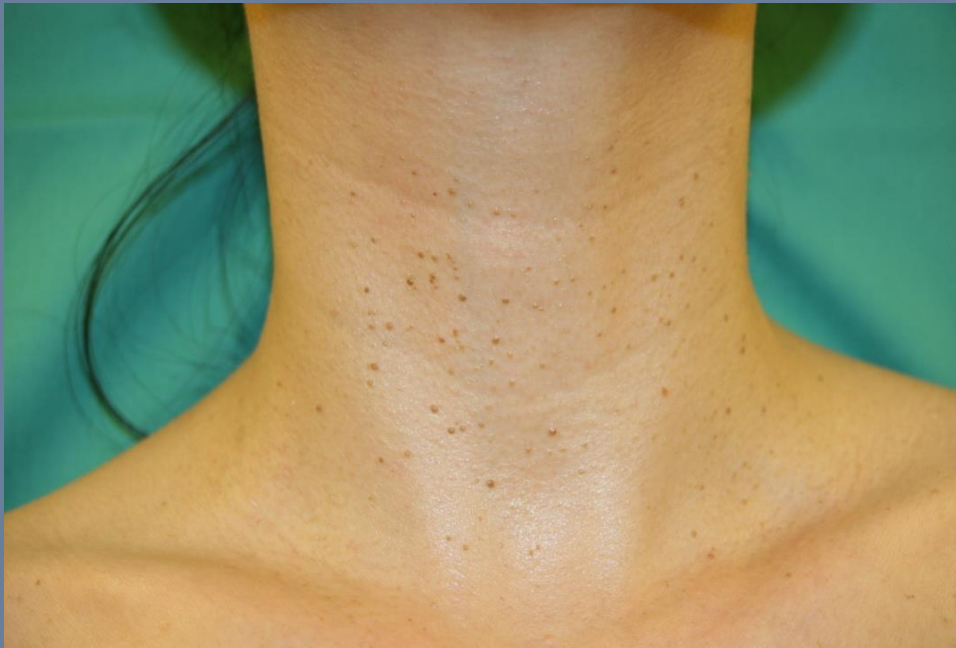Seborrheic Keratosis



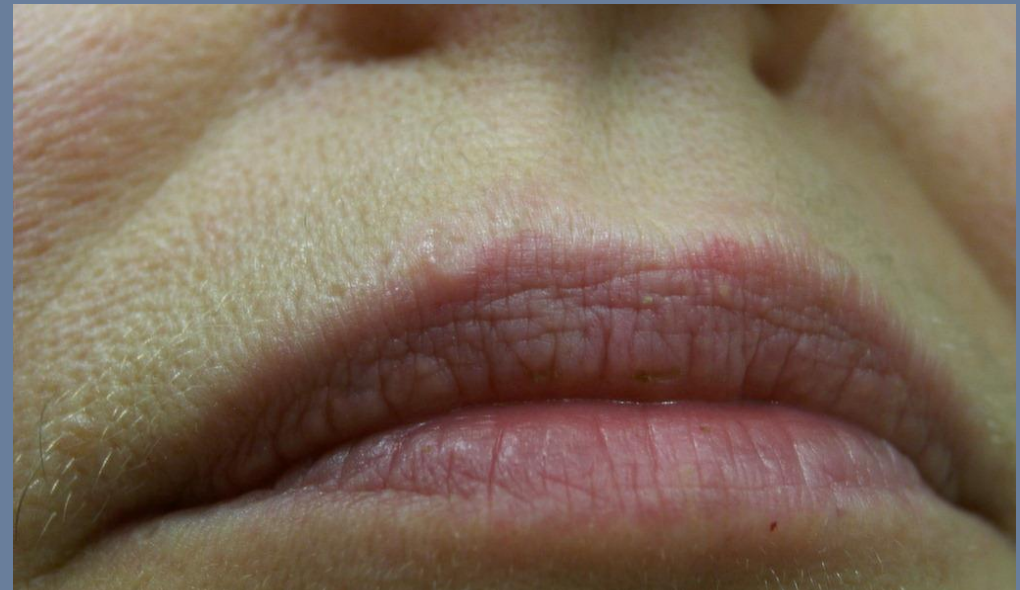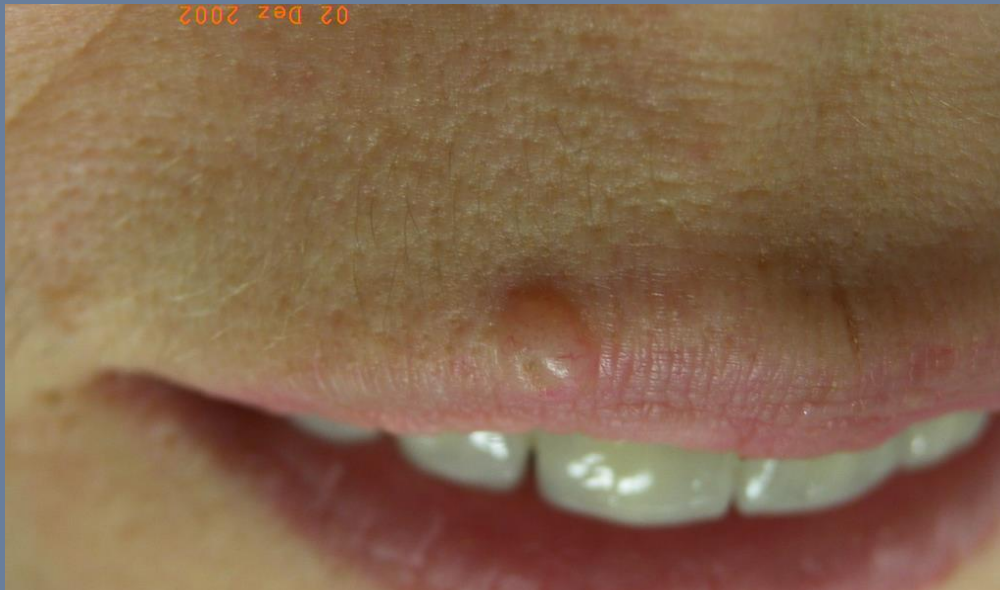Fibroma



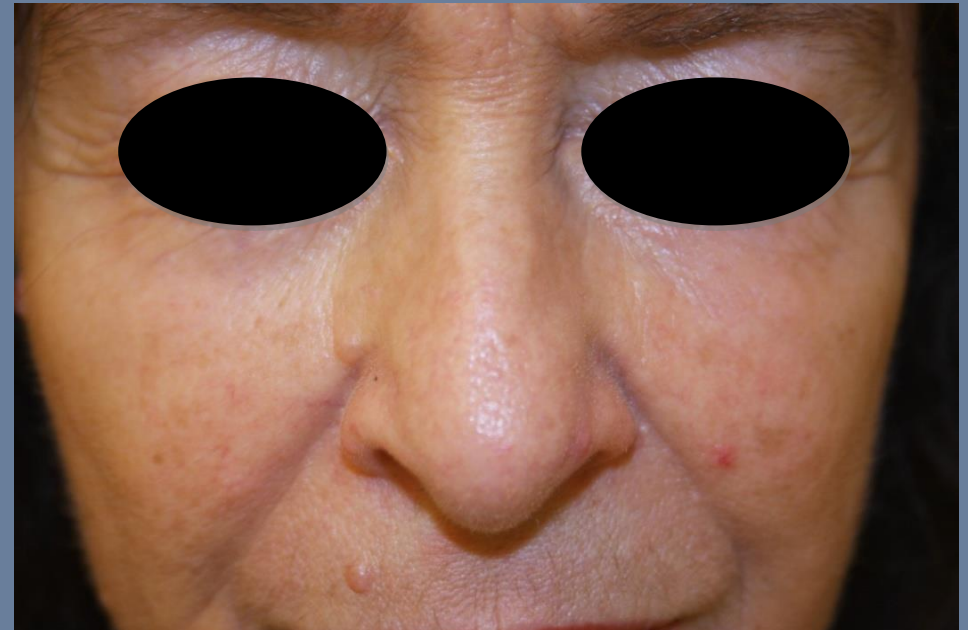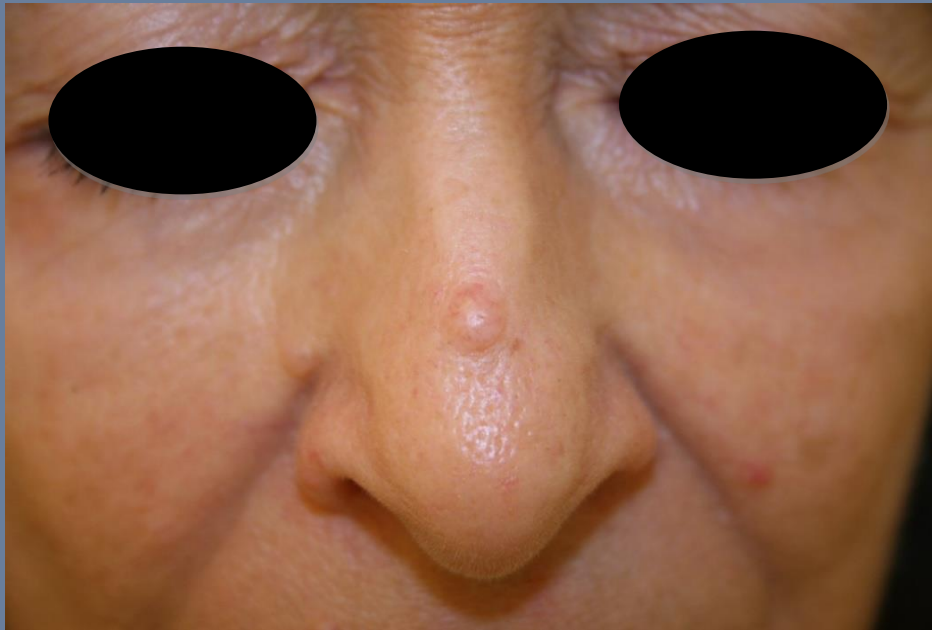Fibroma



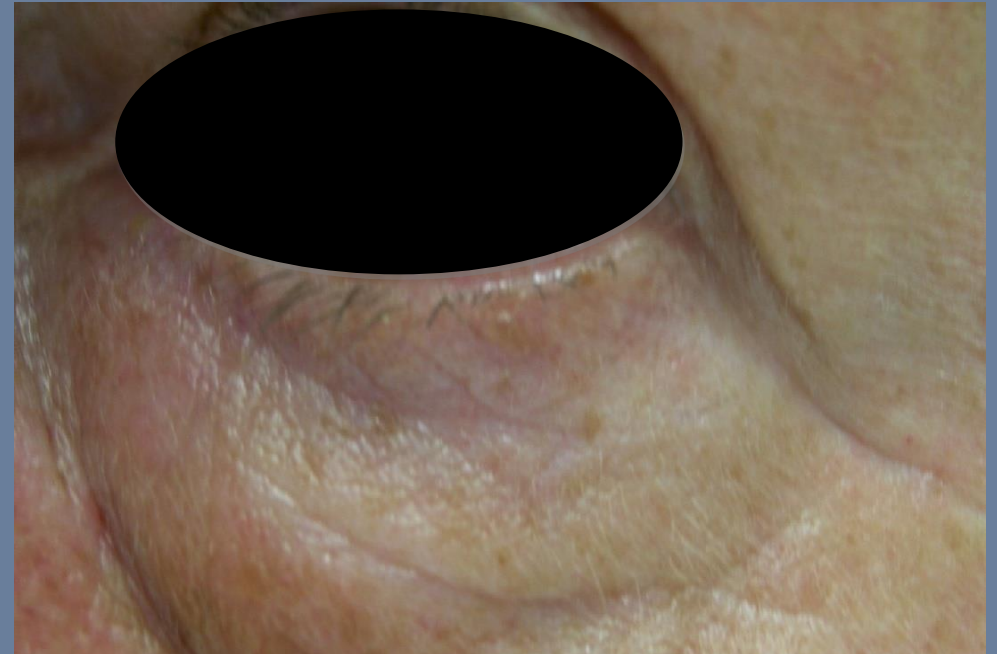
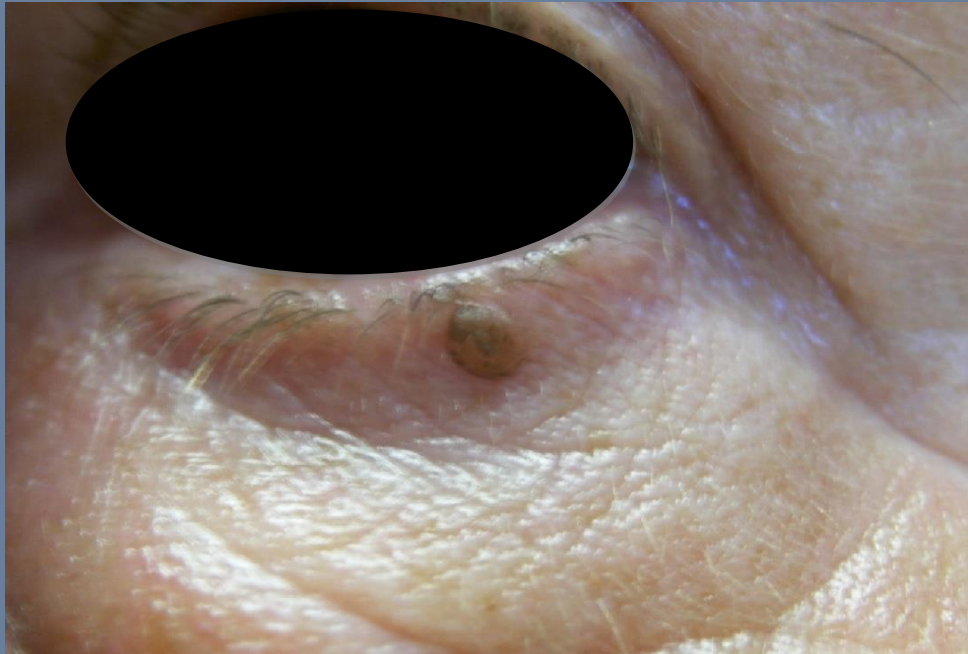
Fibroma



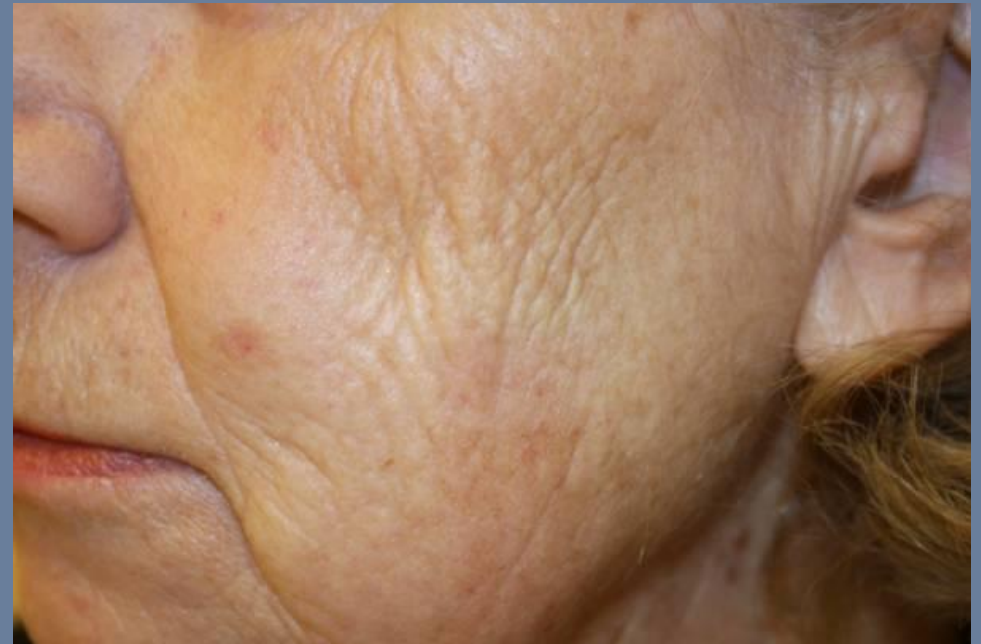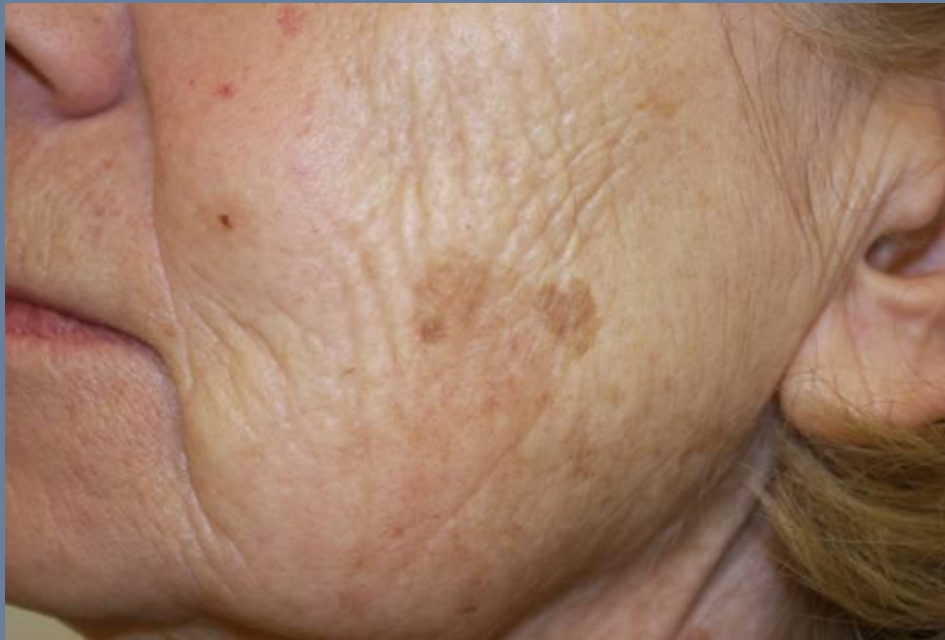Fibrous papule



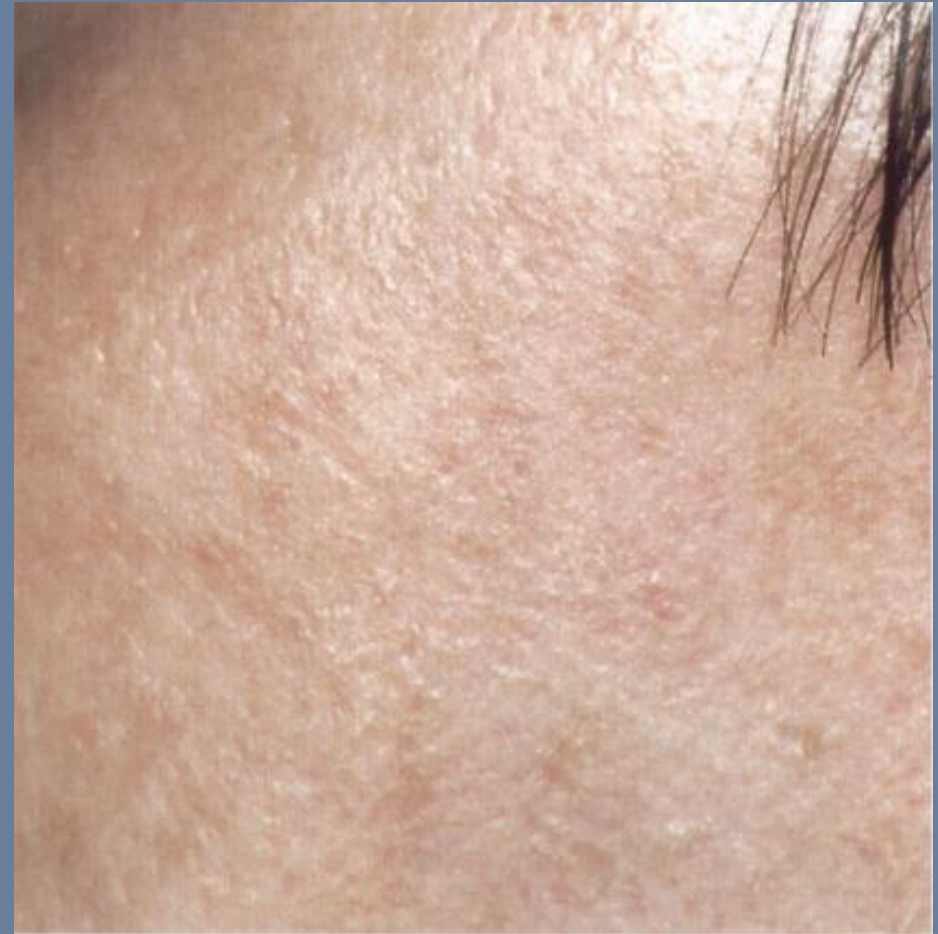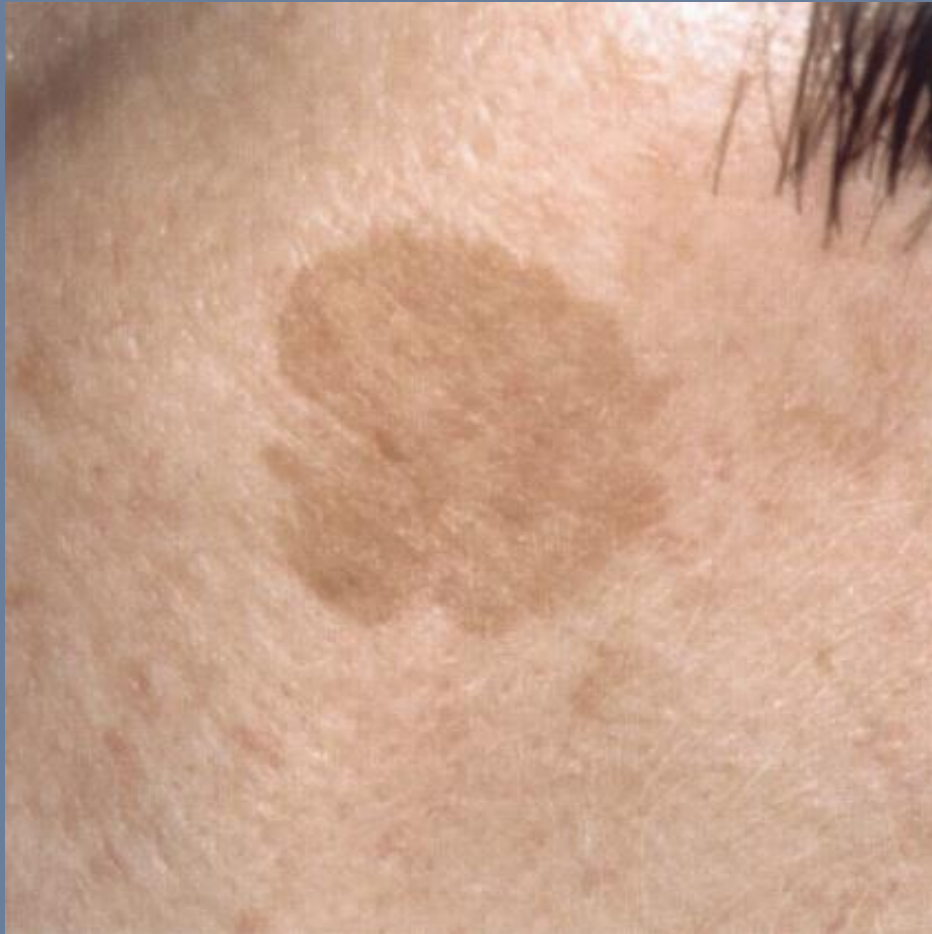Fibroadenoma



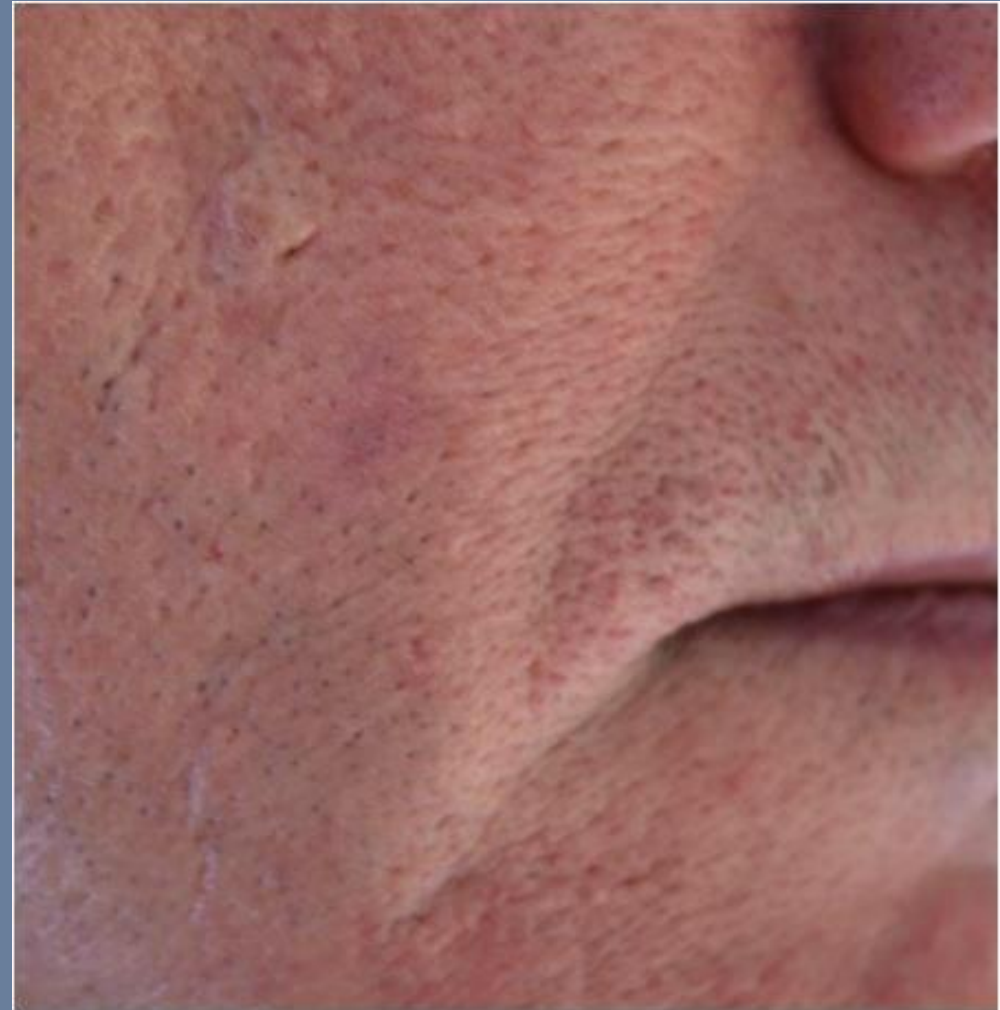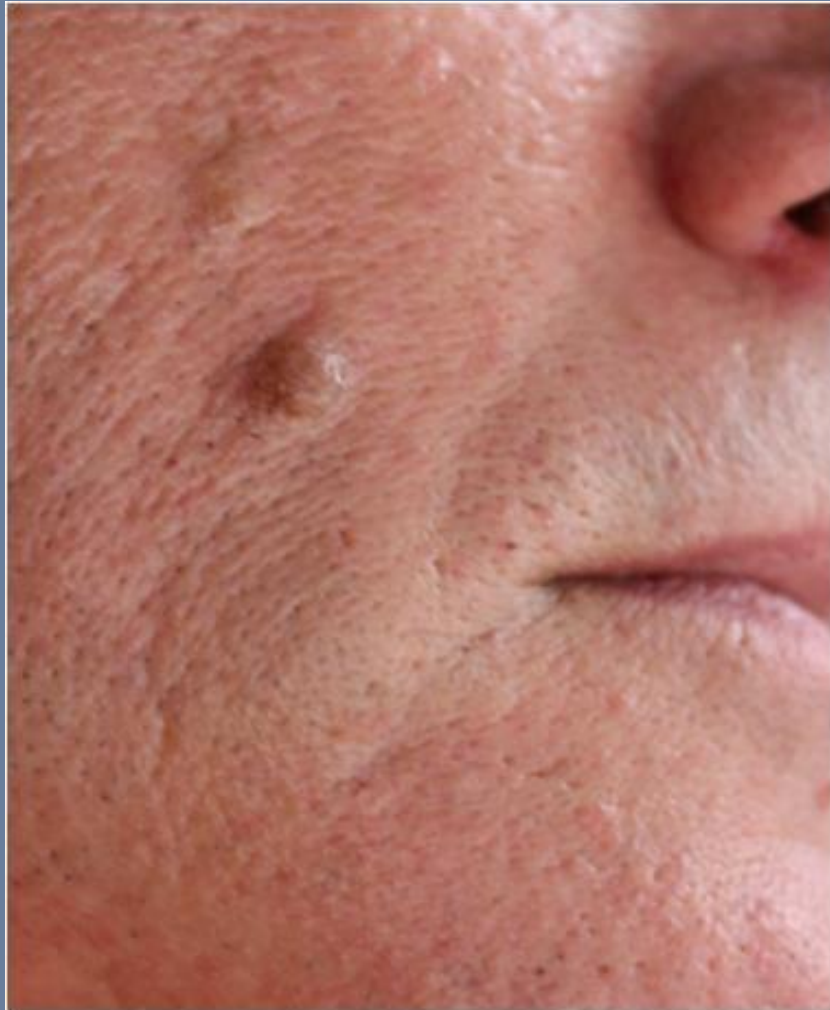Lentigo senilis (Altersflecken)



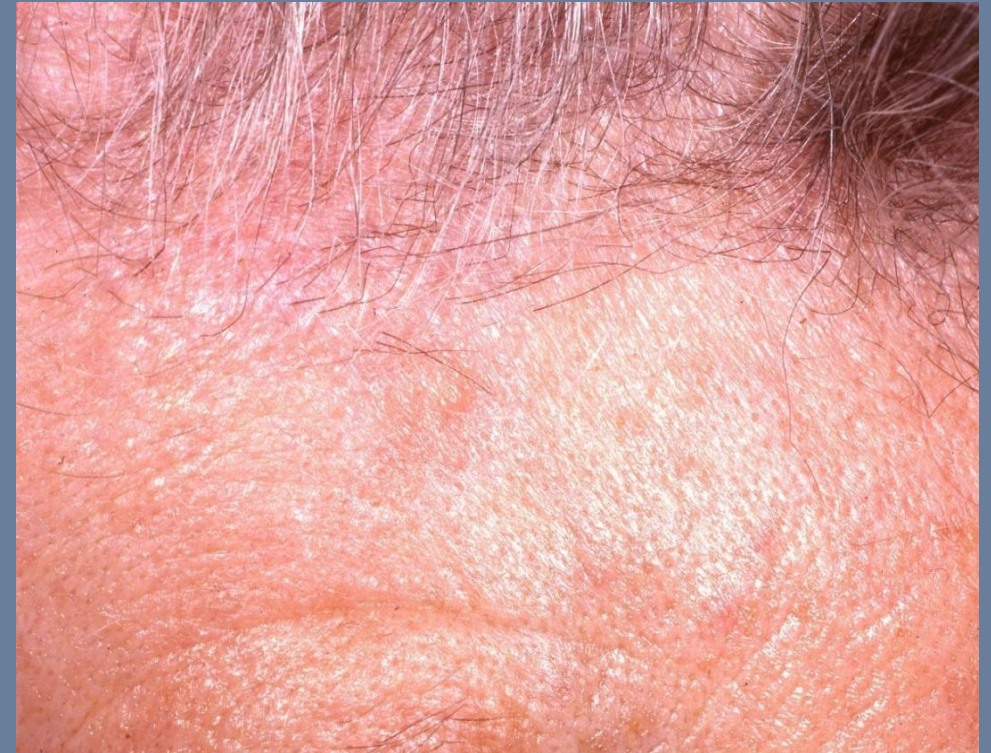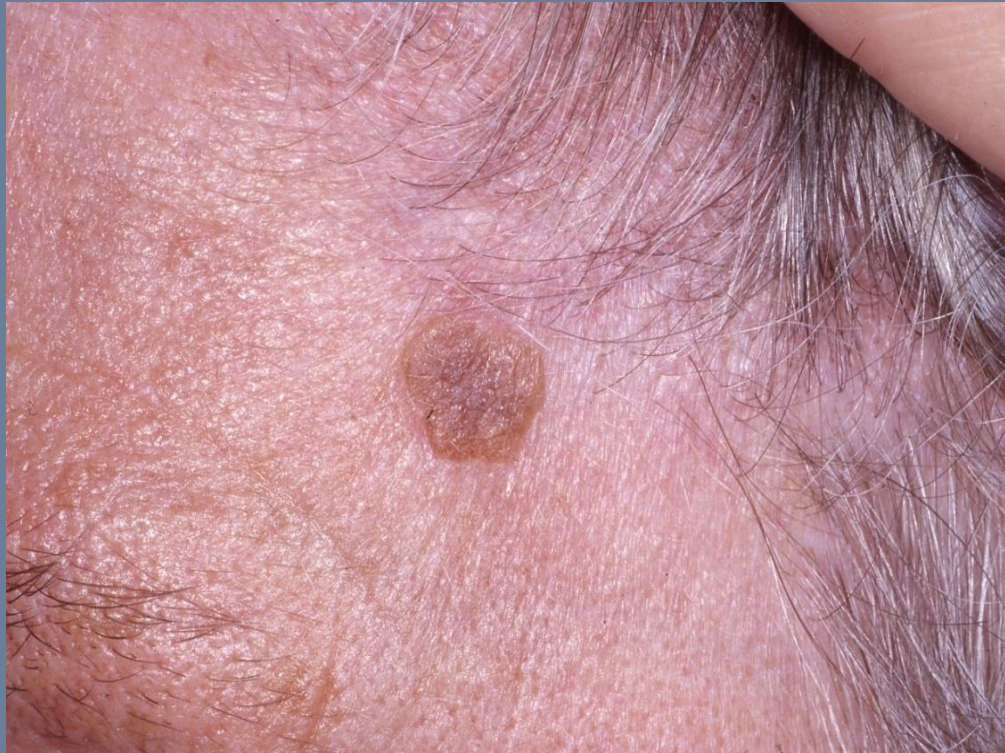Lentigo senilis (Altersflecken)



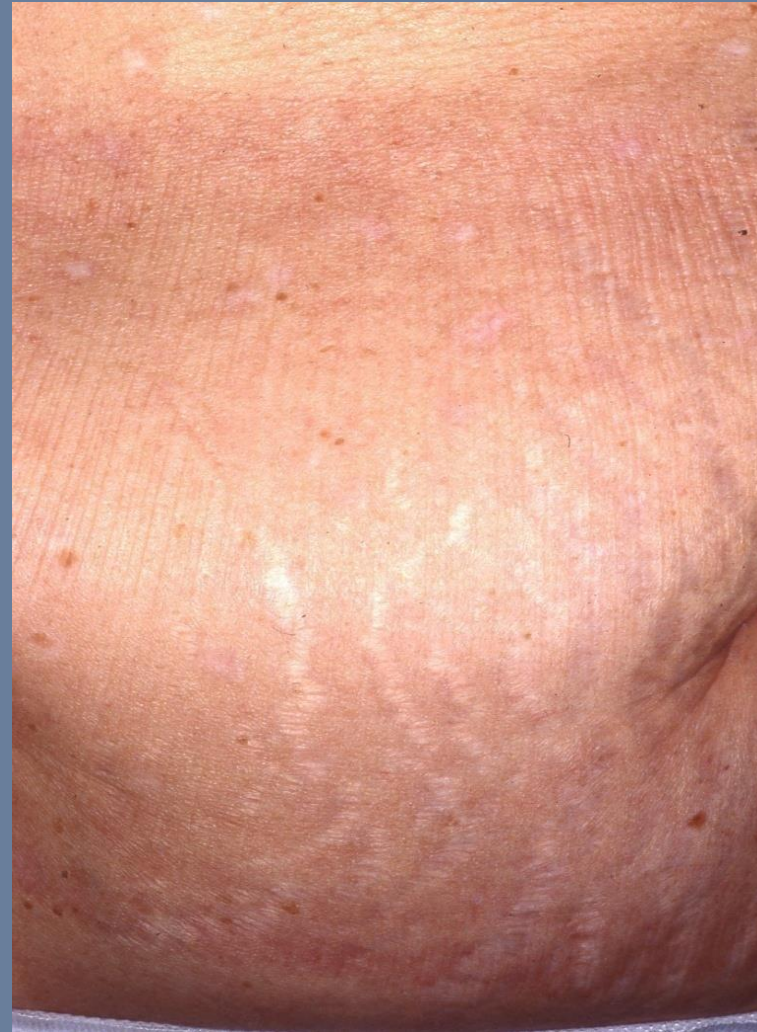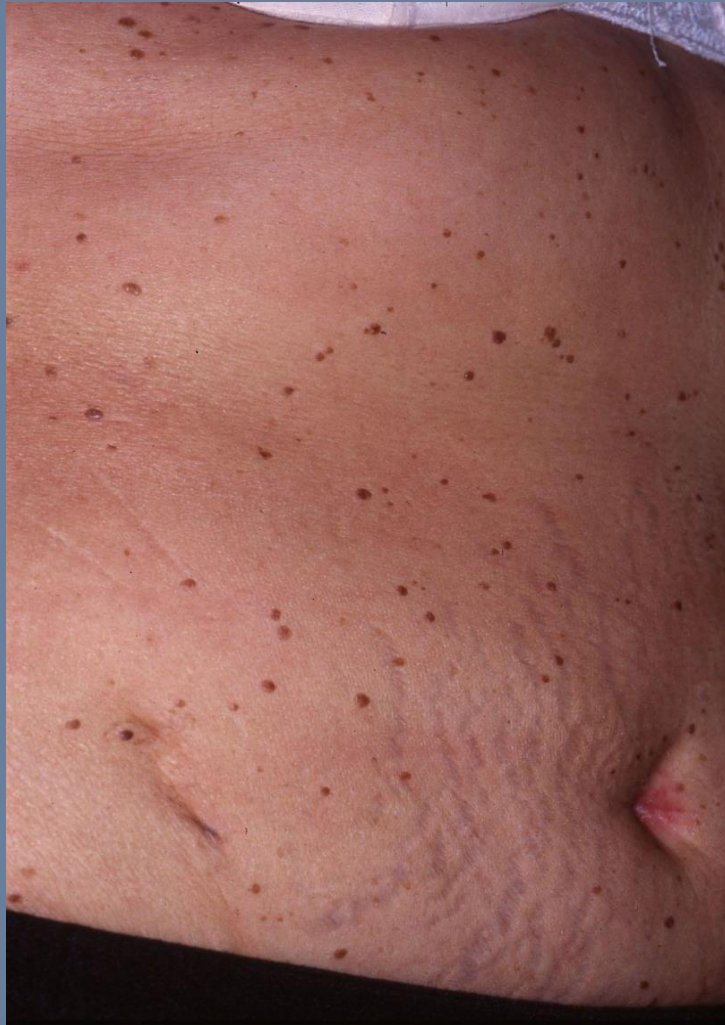Compound nevus



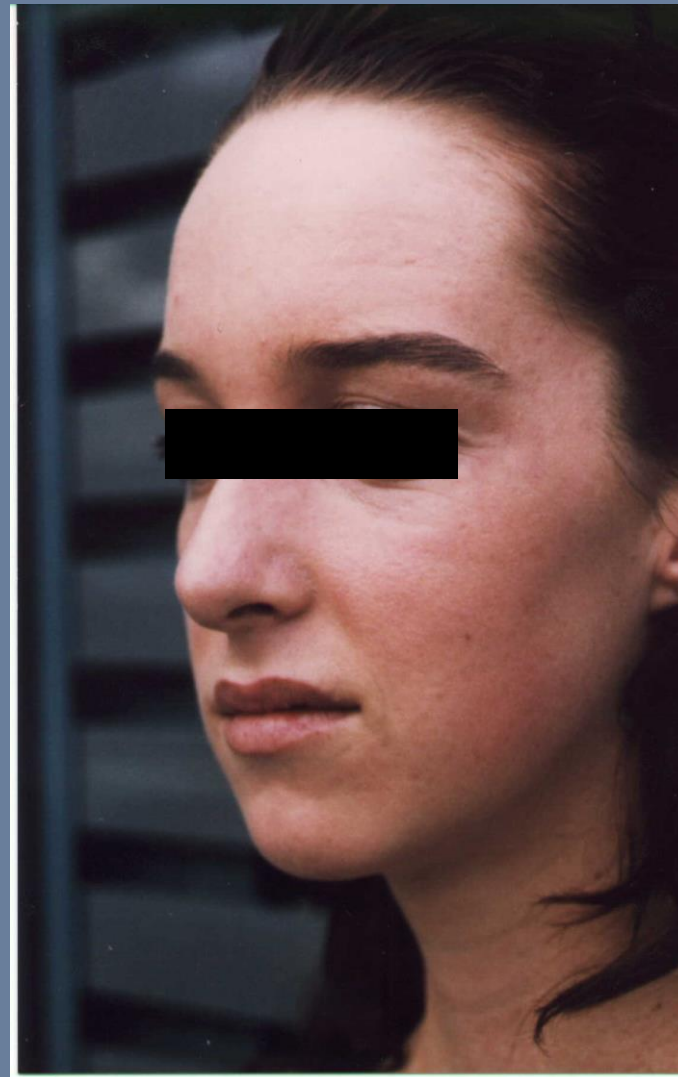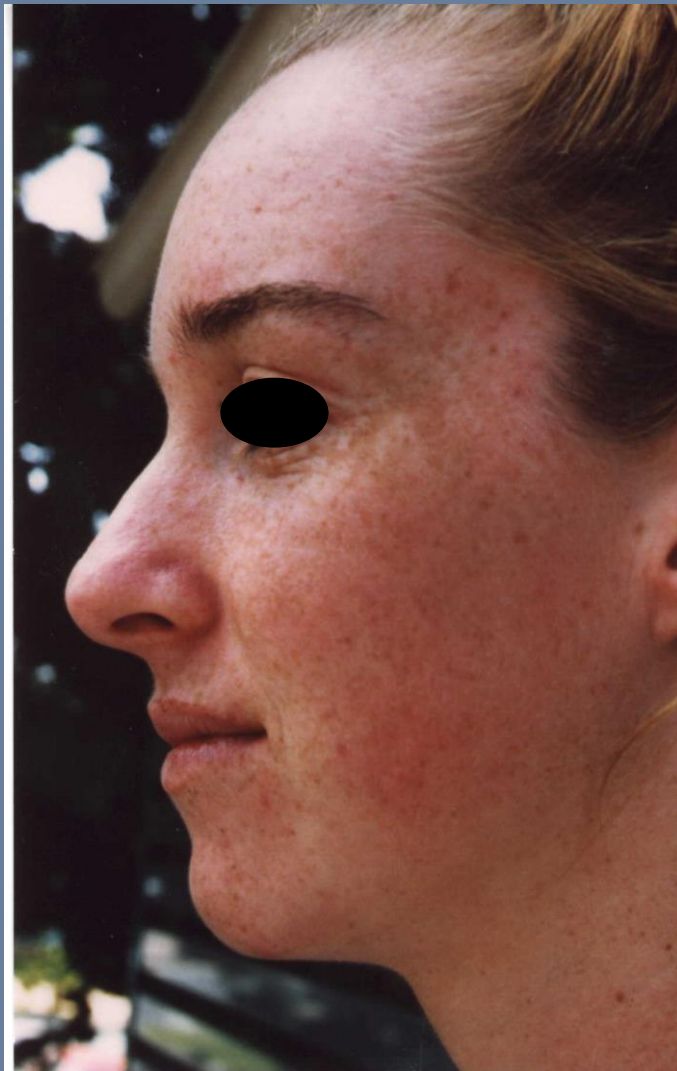Verruca seborrhoica pigmentosa



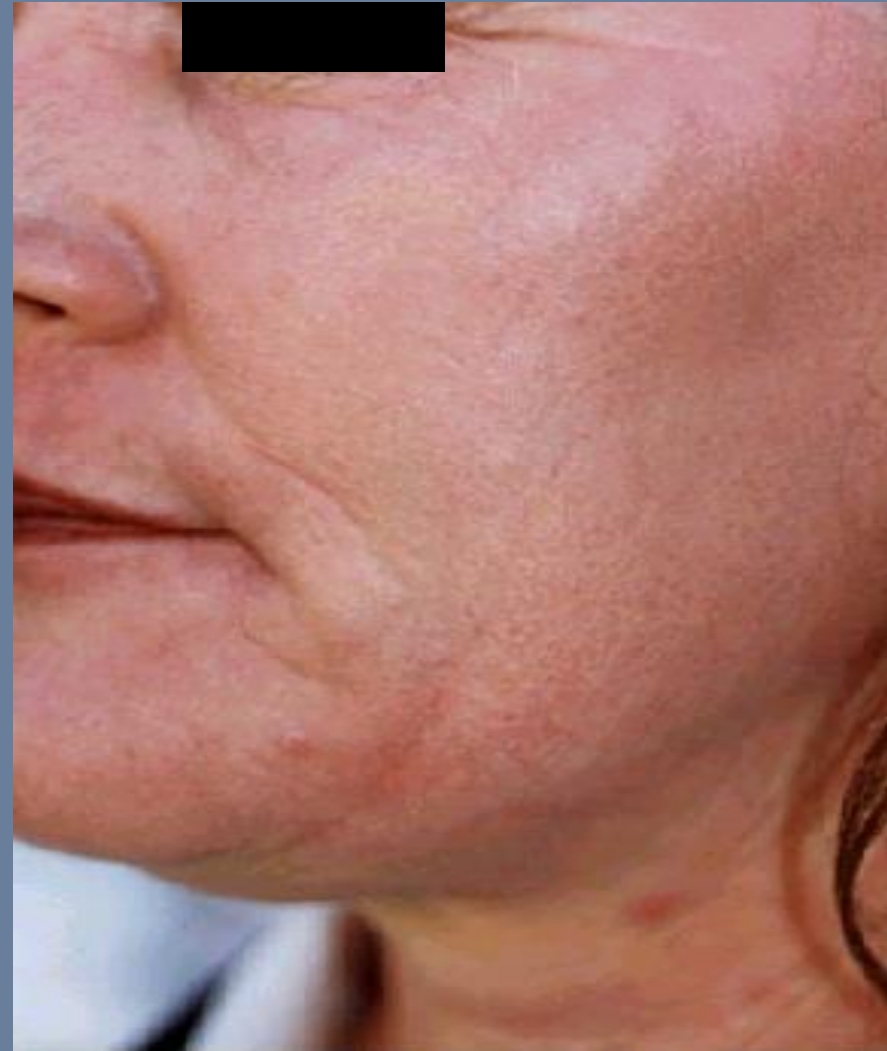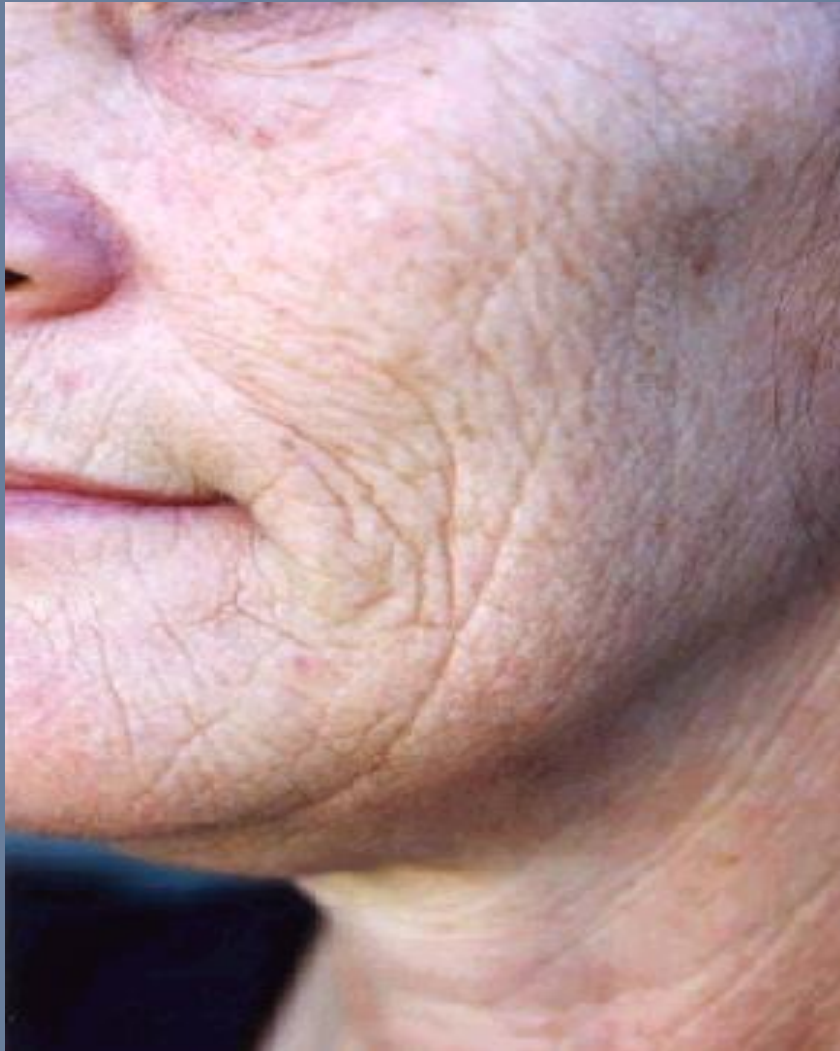Verruca seborrhoica pigmentosa



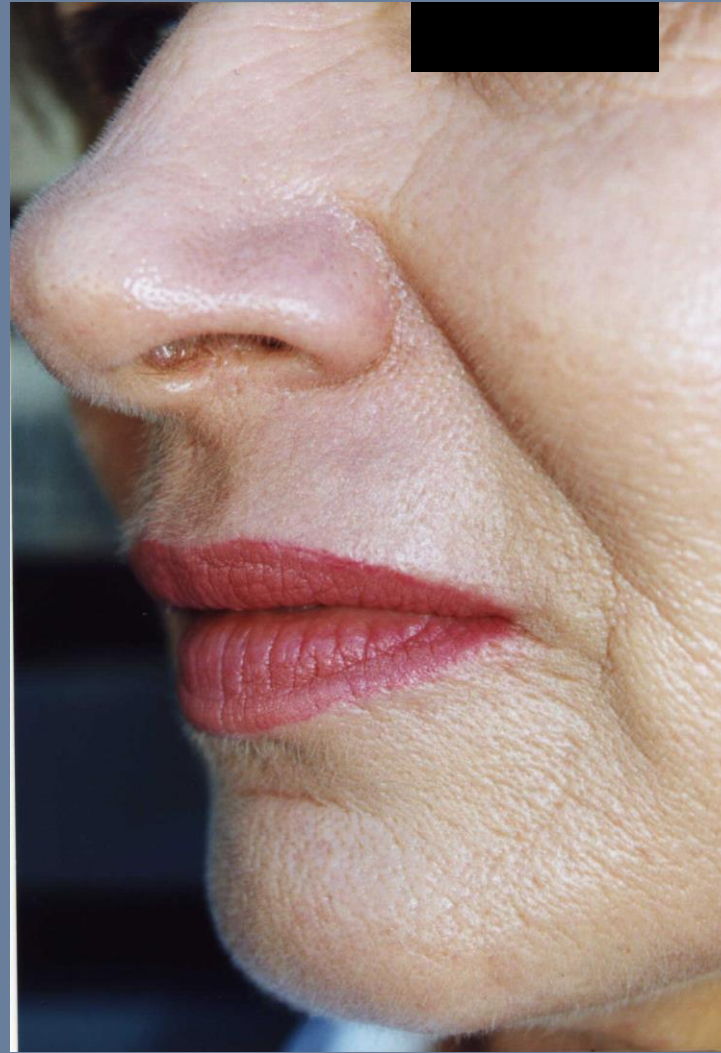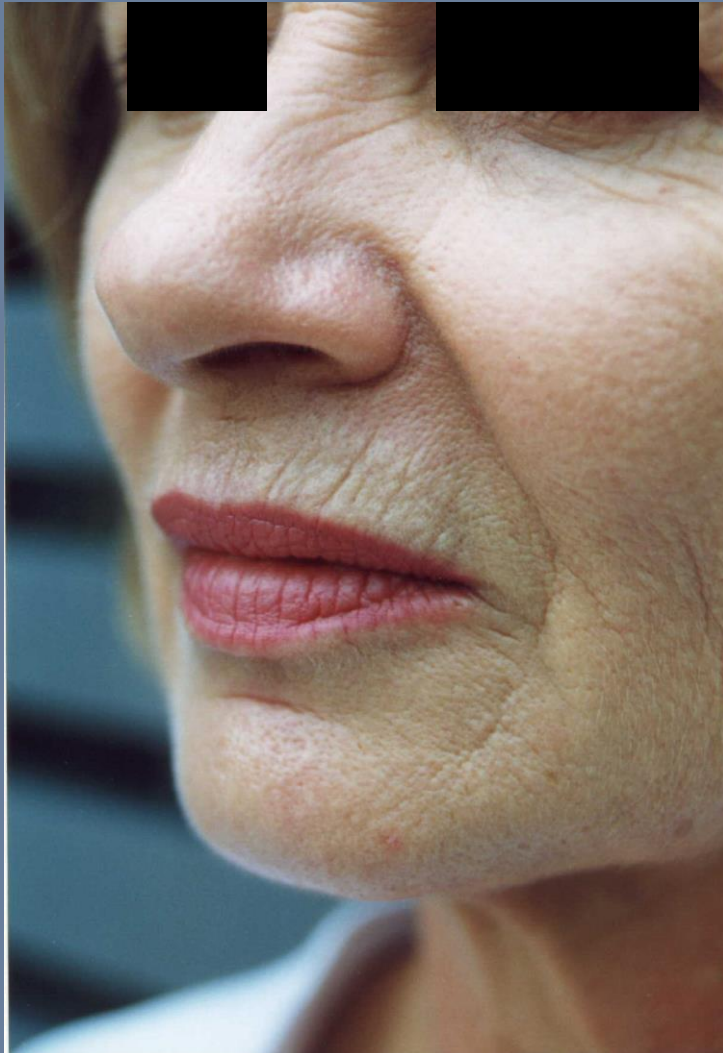Freckles (Sommersprossen)



Full Skin Resurfacing

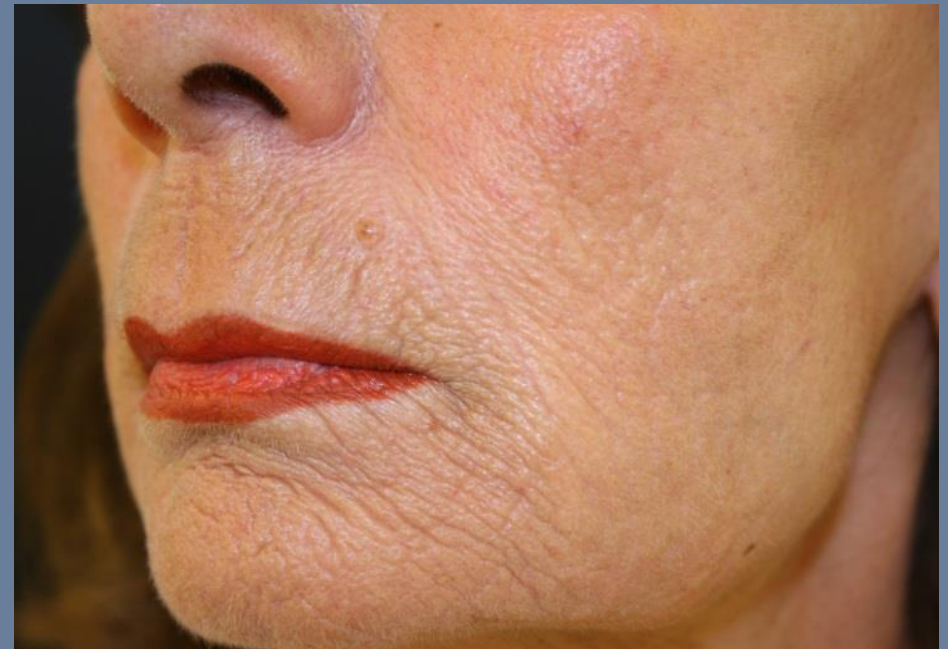
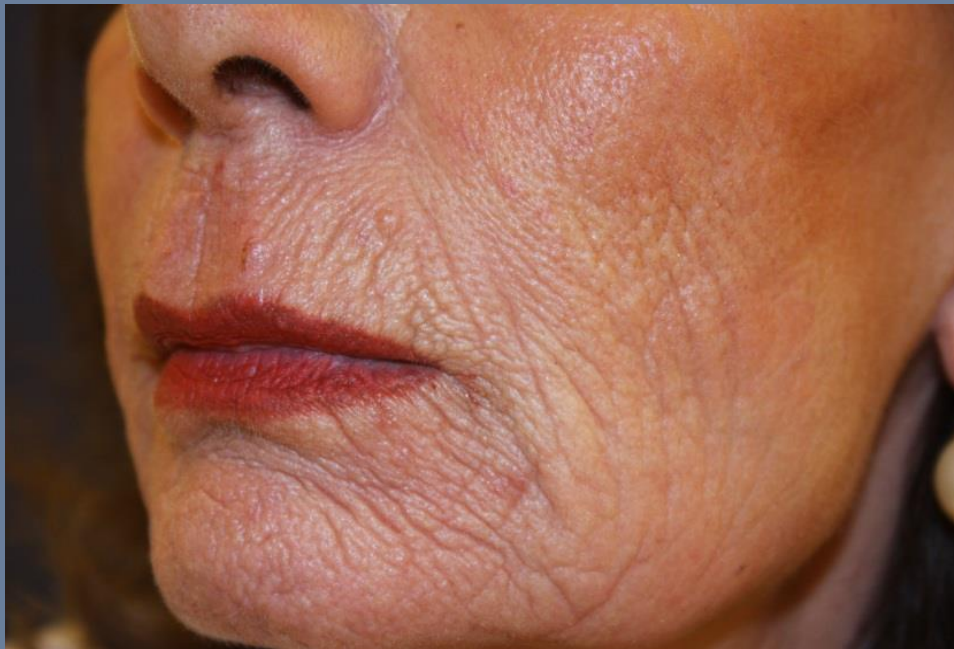
Full Skin Resurfacing

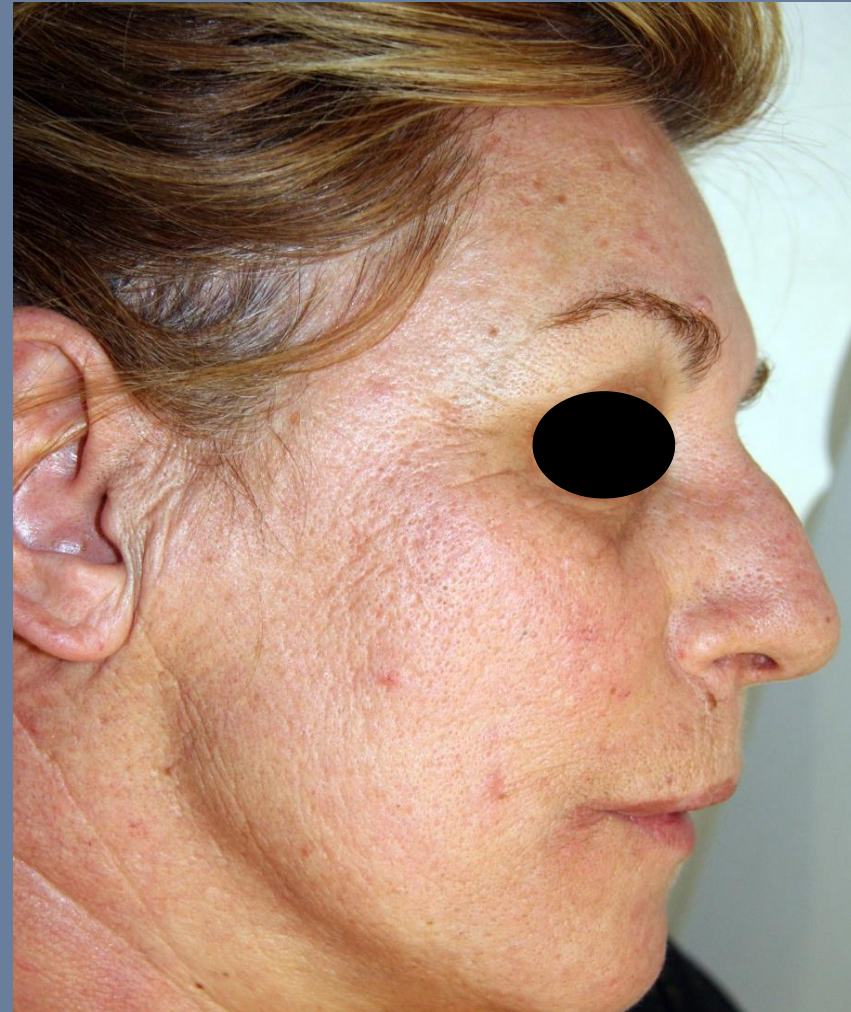
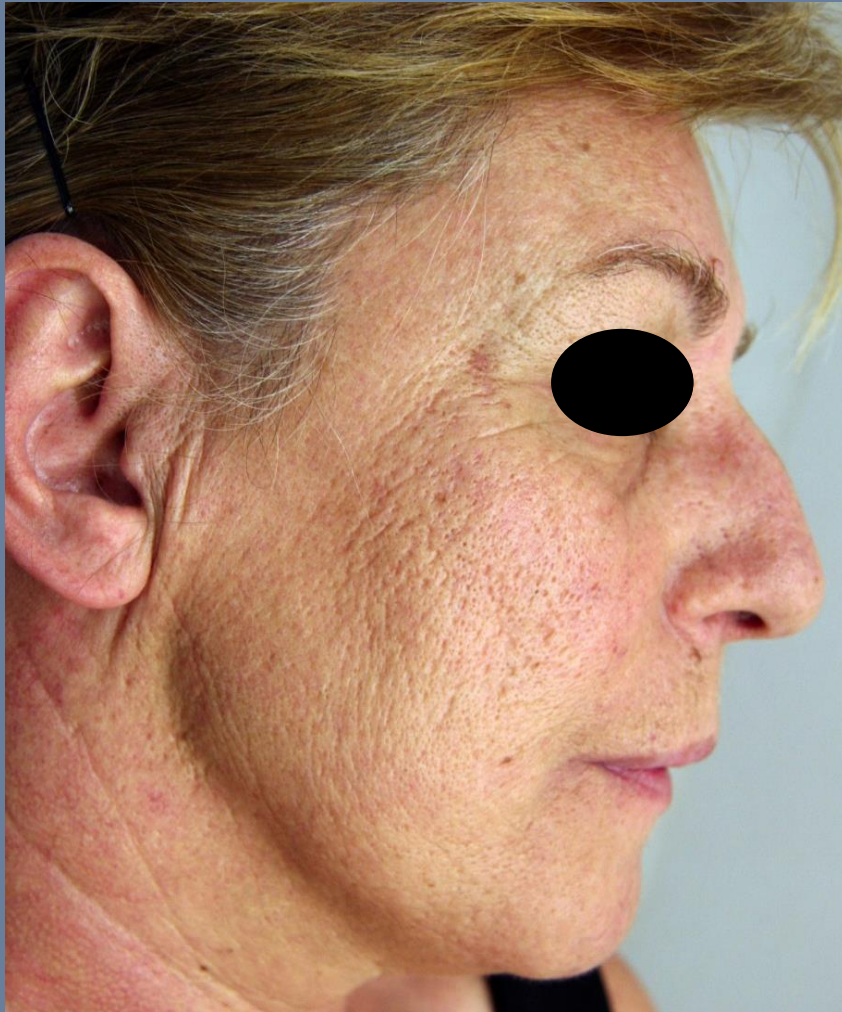
Er:YAG Fractional

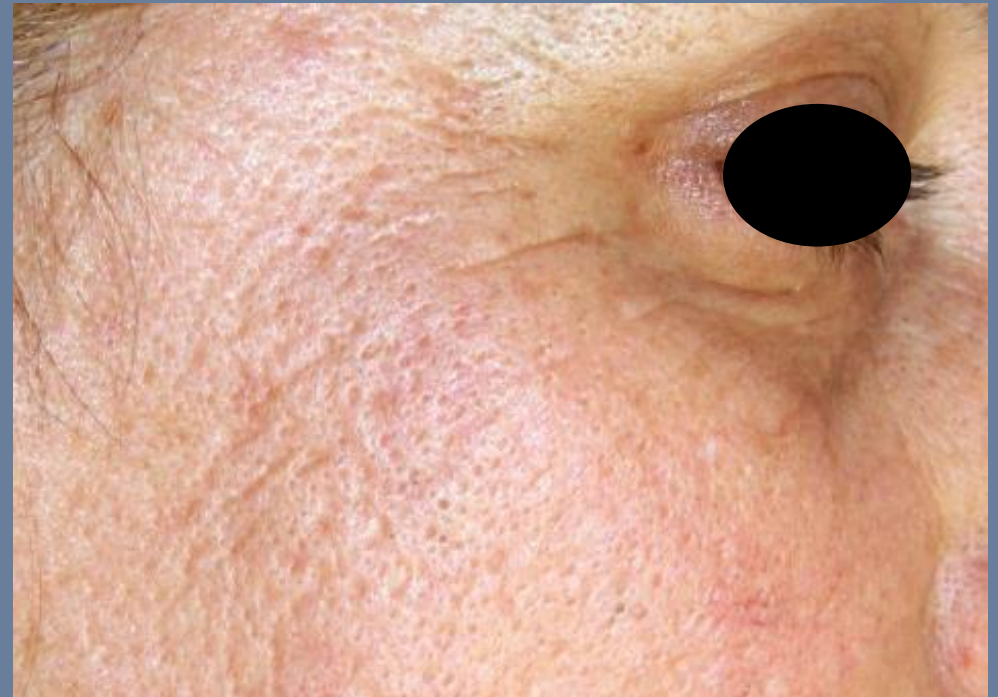
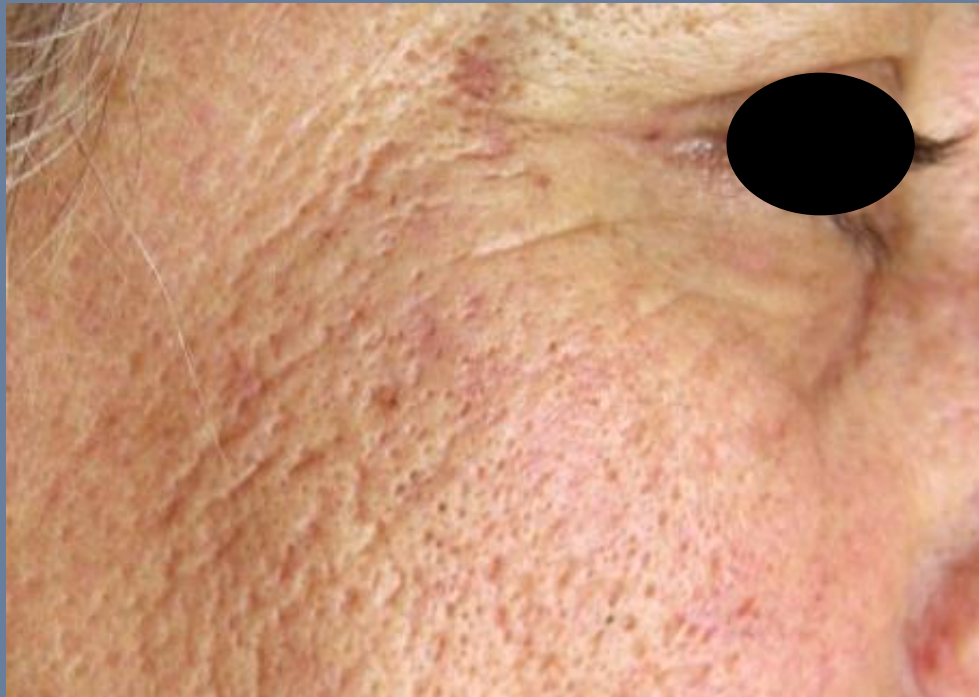
Fractional Skin Resurfacing



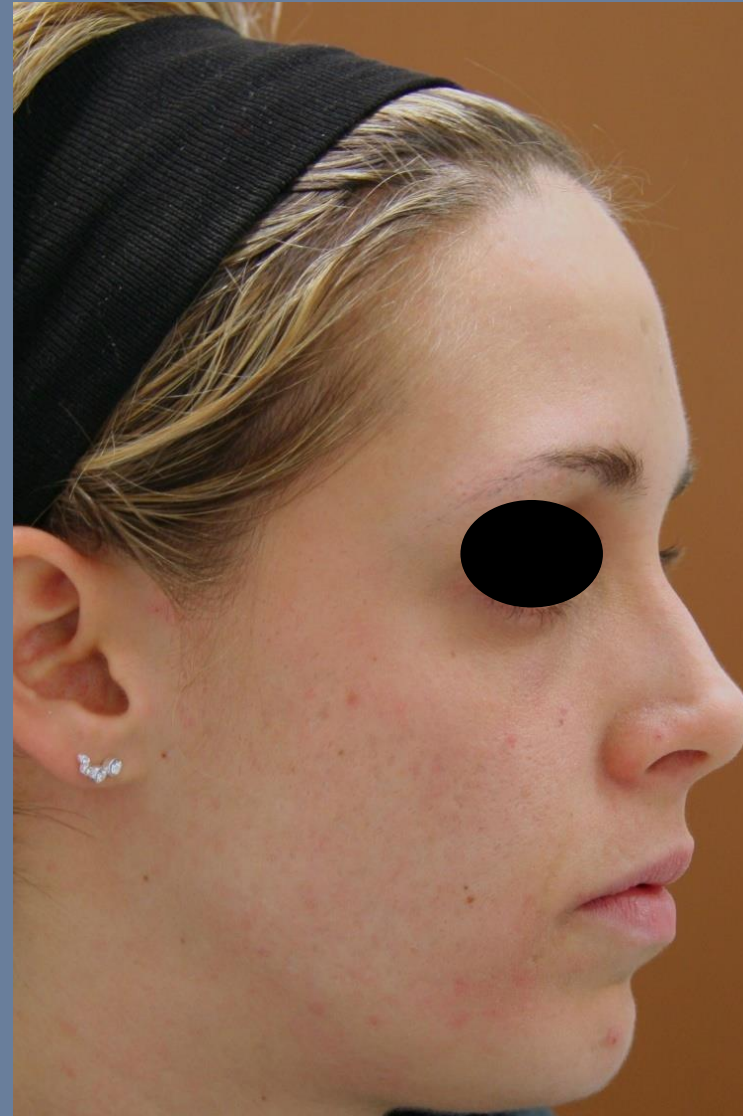
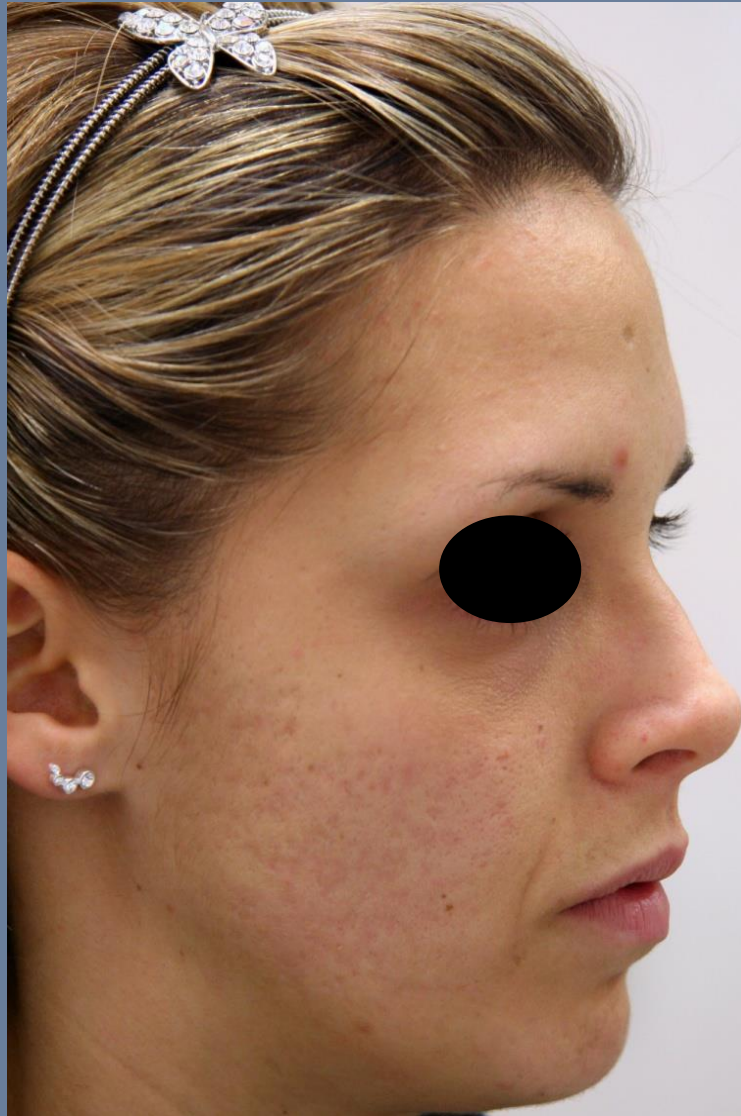Acne scars (Aknenarben)



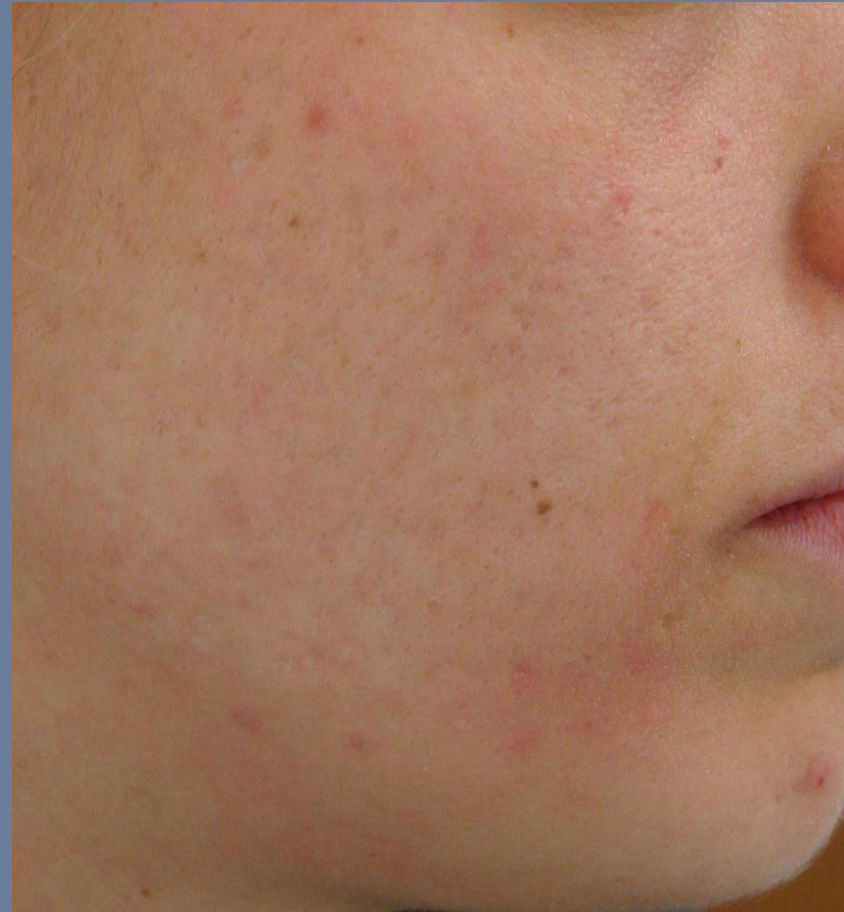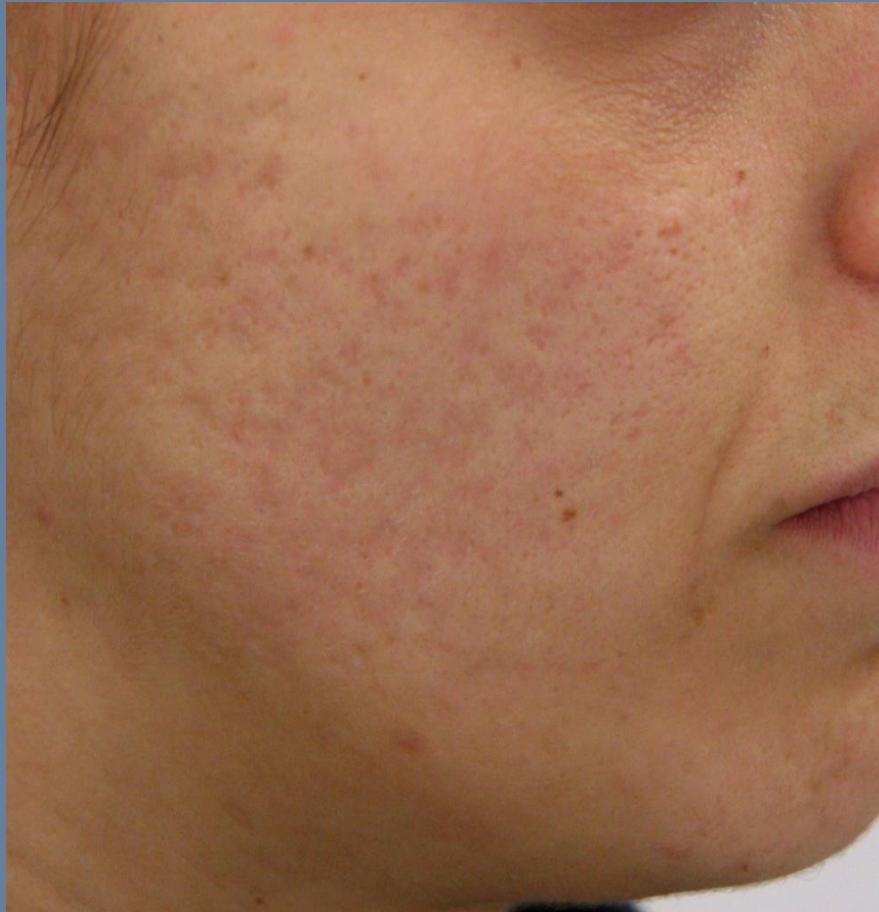Acne scars (Aknenarben)



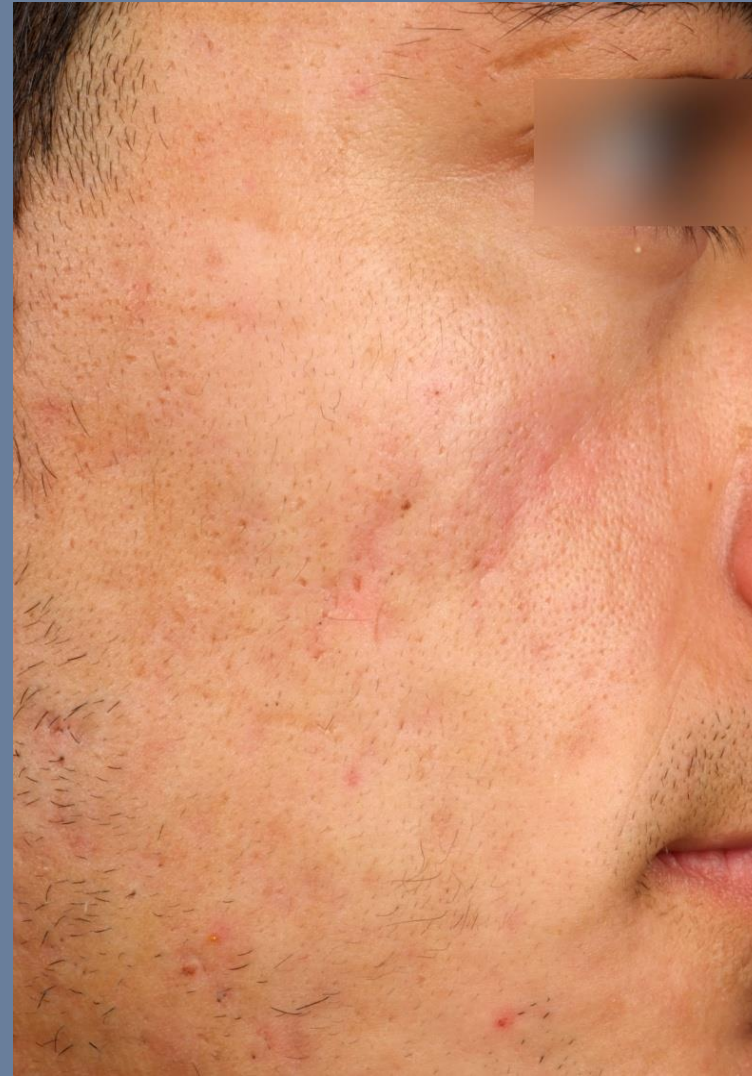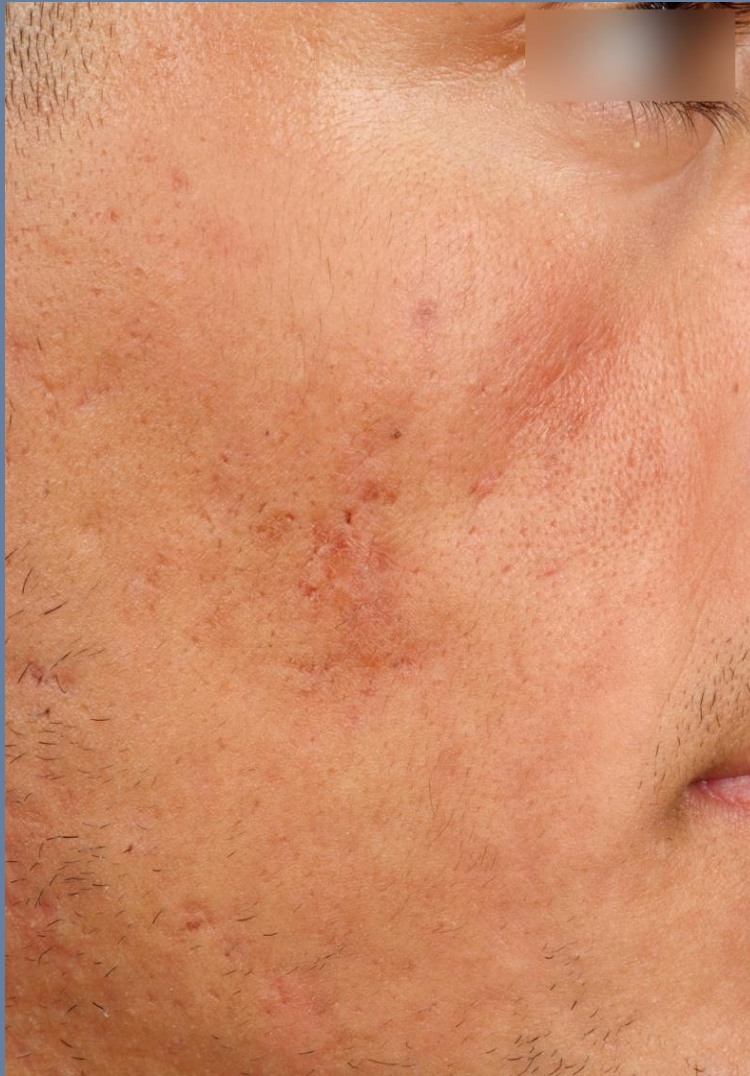Acne scars (Aknenarben)



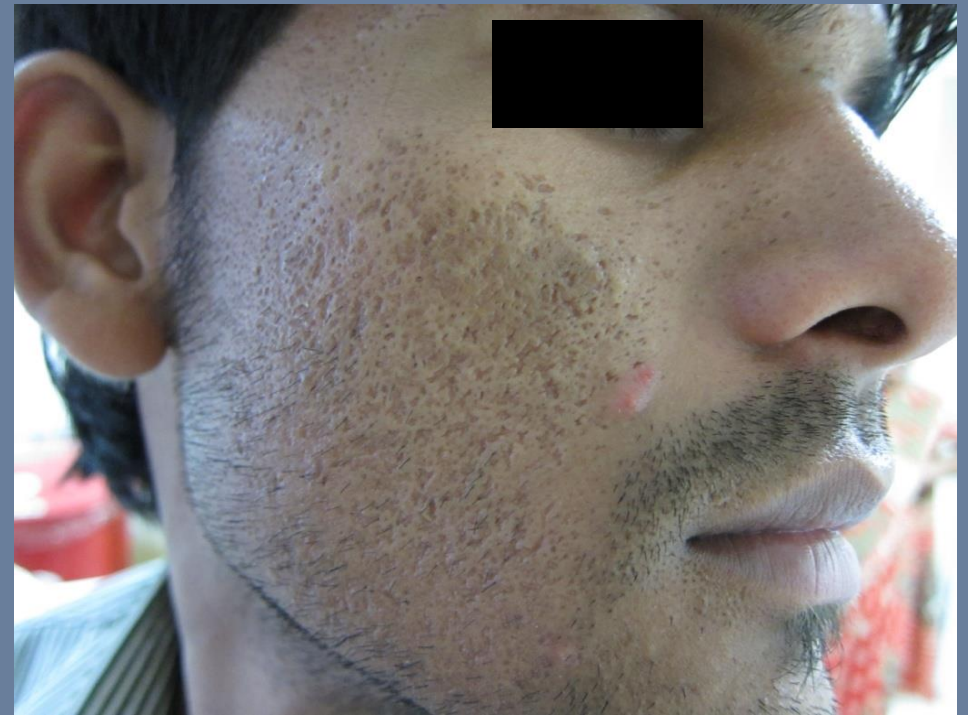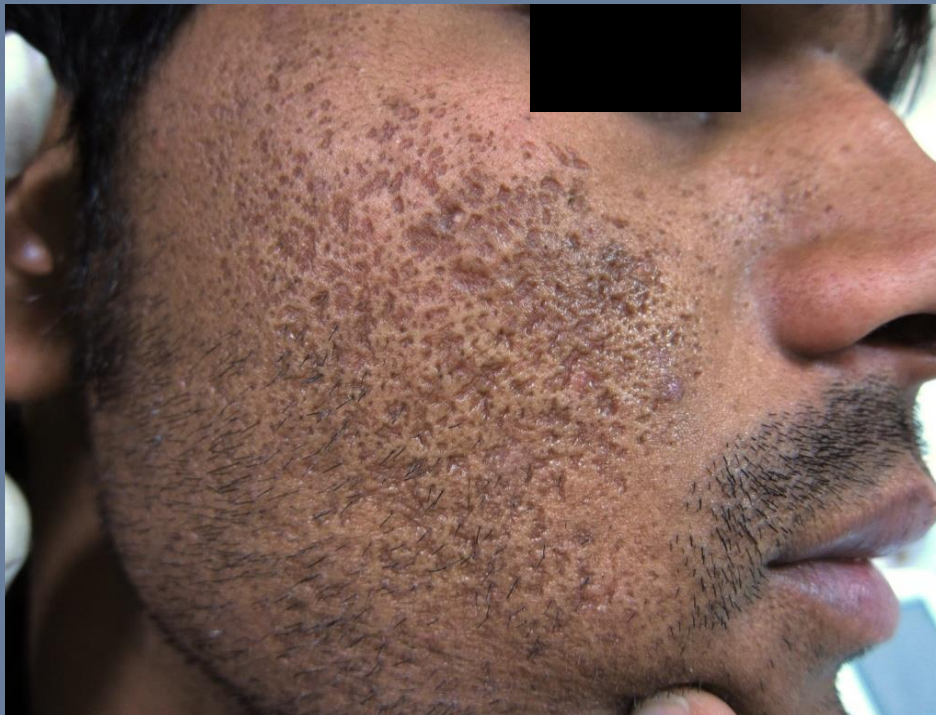Acne scars (Aknenarben)



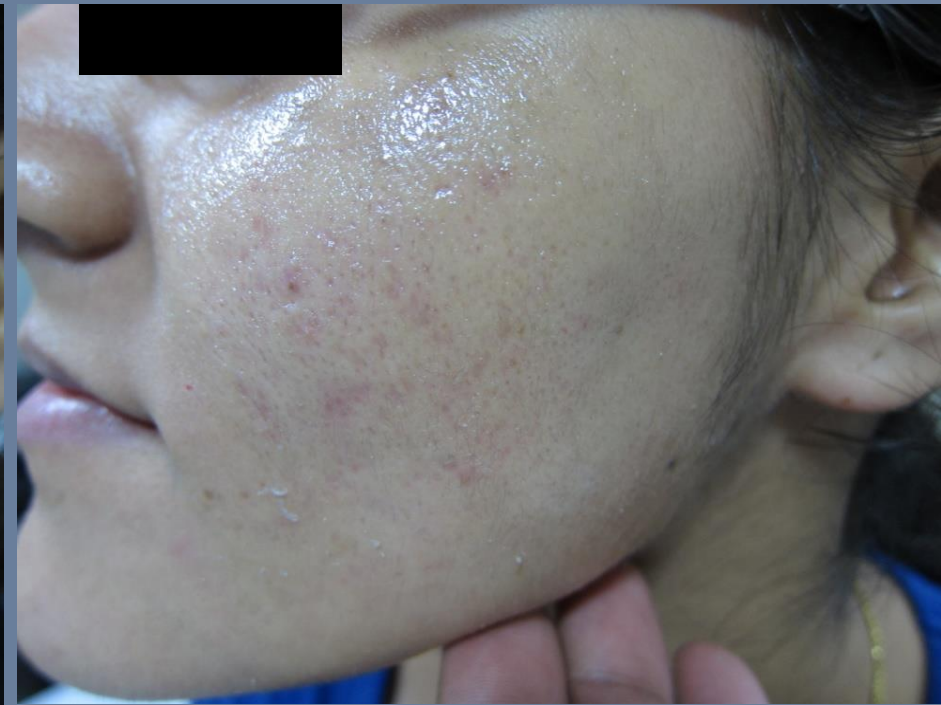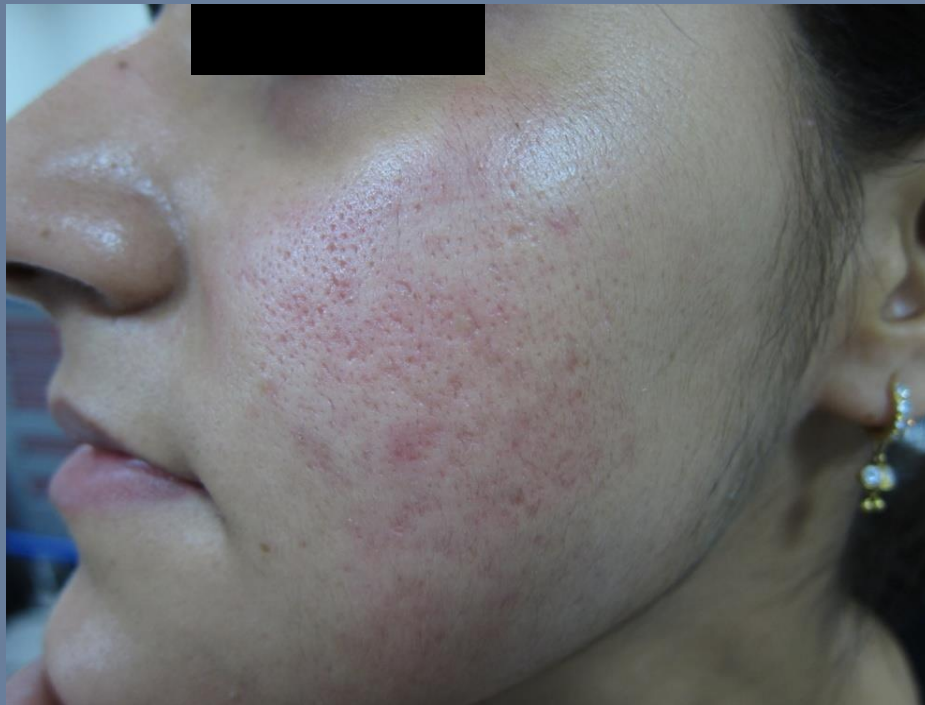Acne scars (Aknenarben)



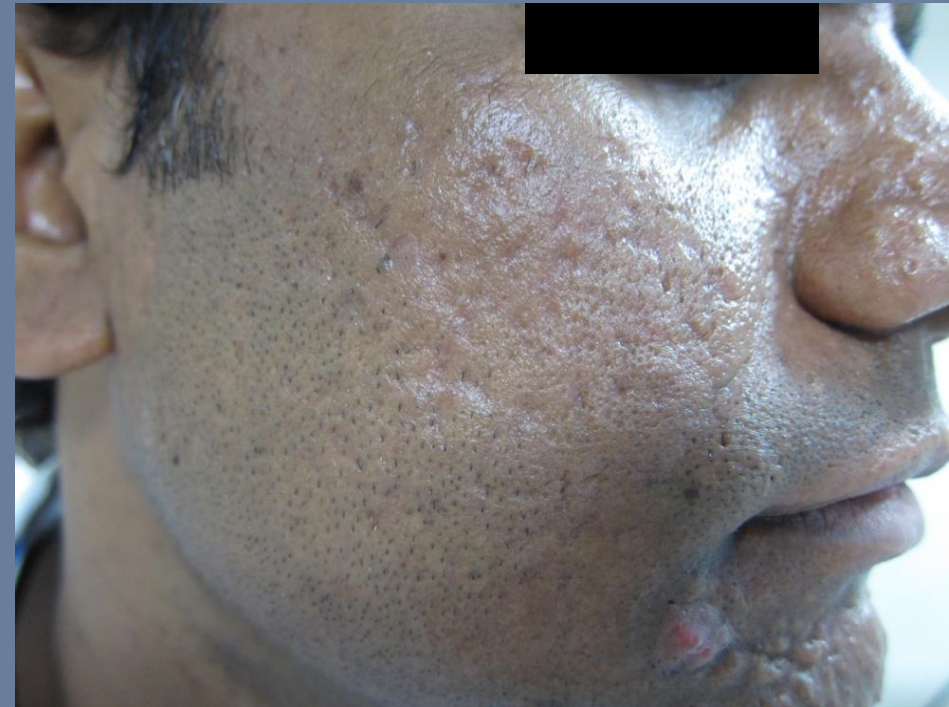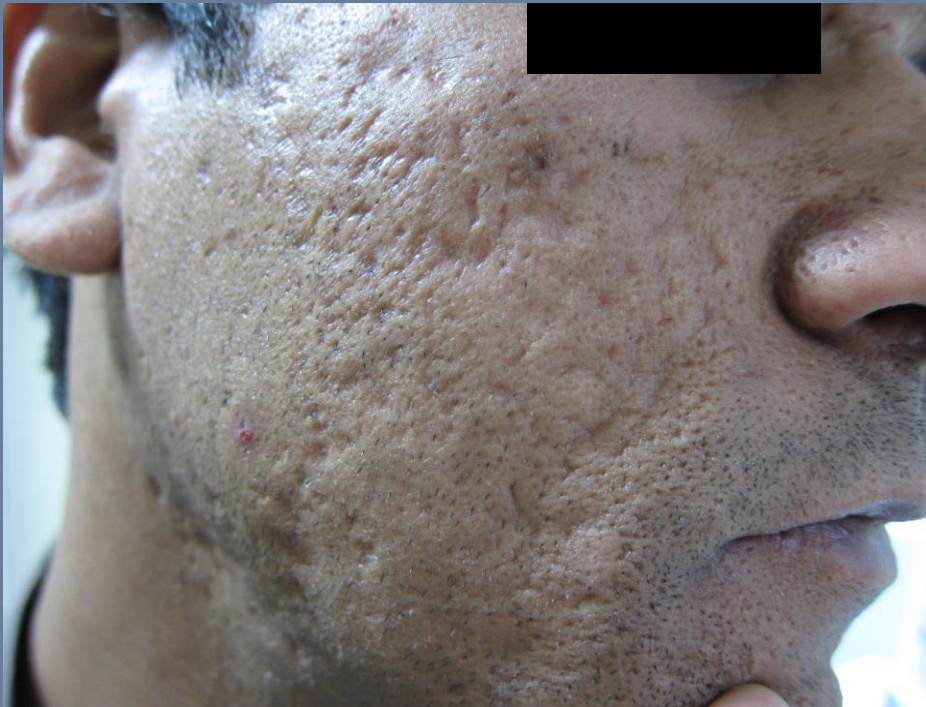Acne scars (Aknenarben)



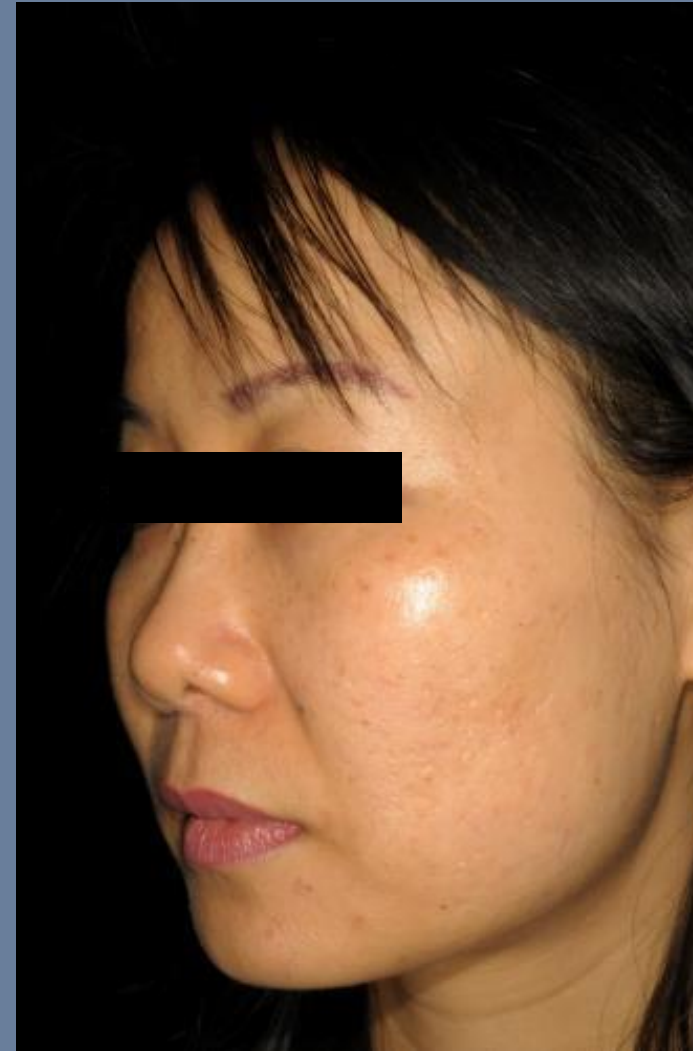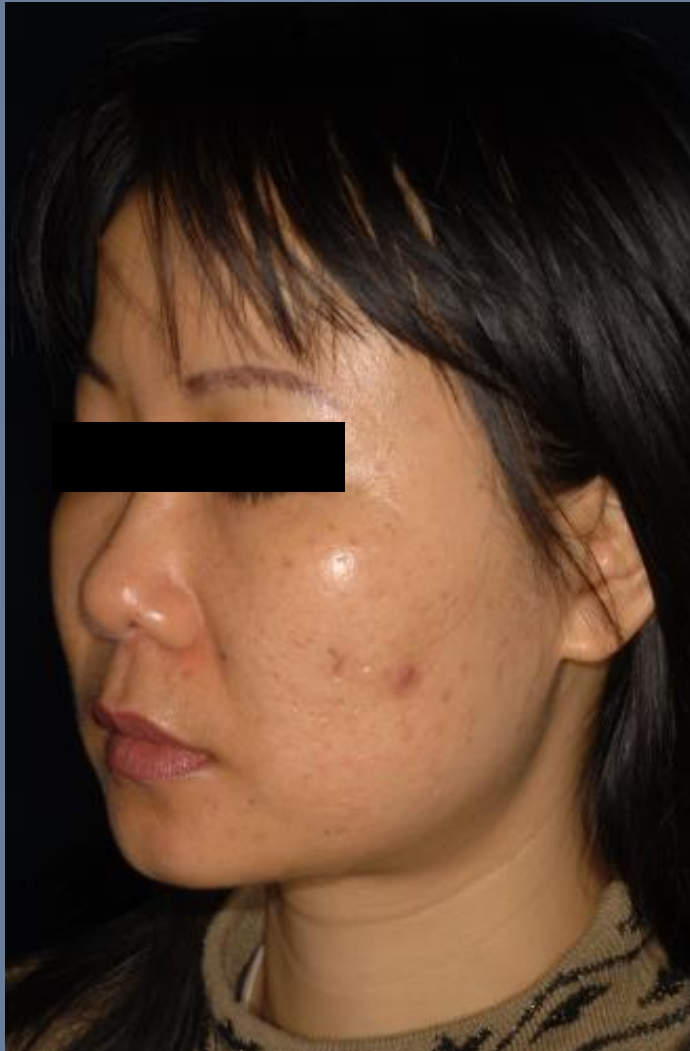
Acne scars (Aknenarben)



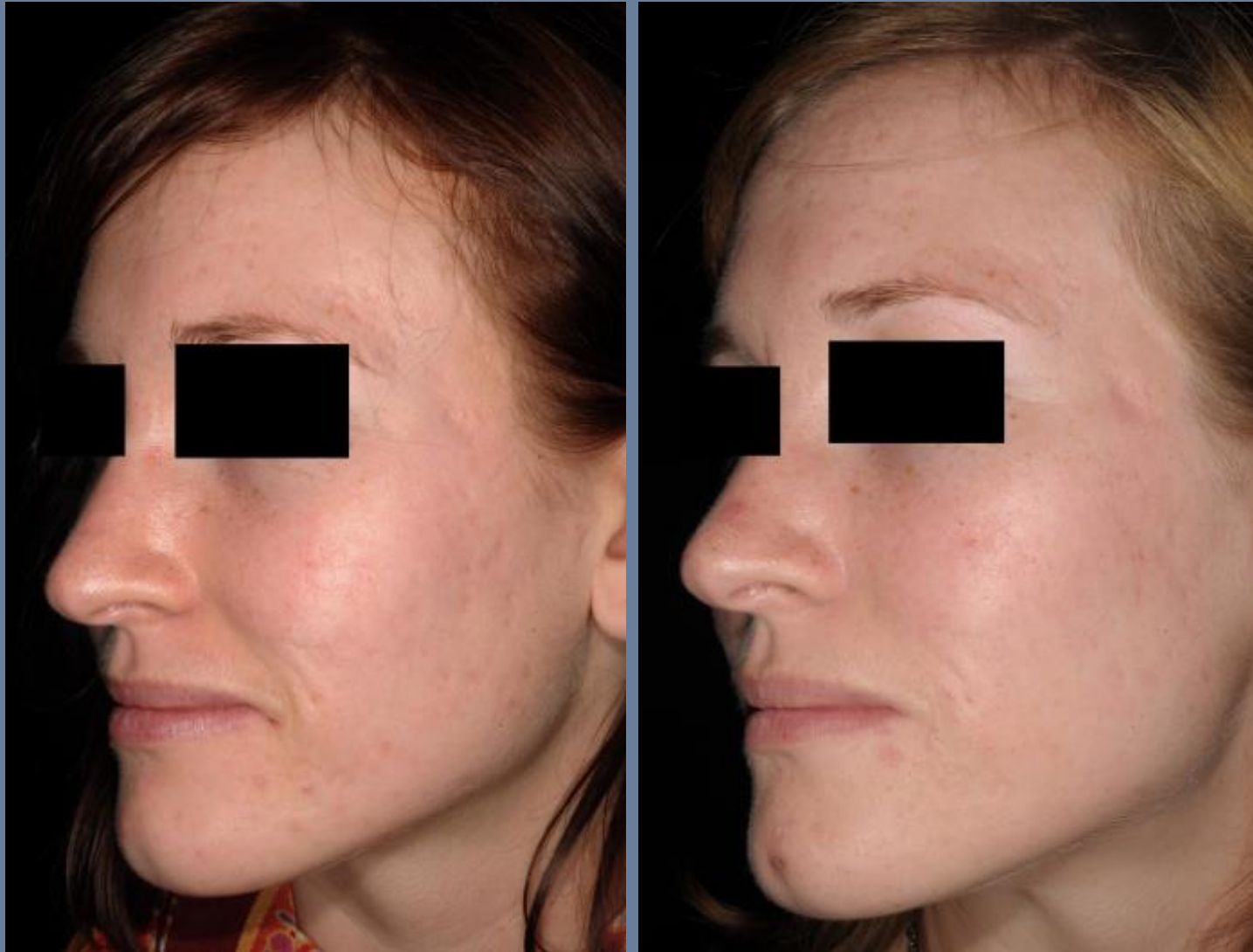Acne scars (Aknenarben)



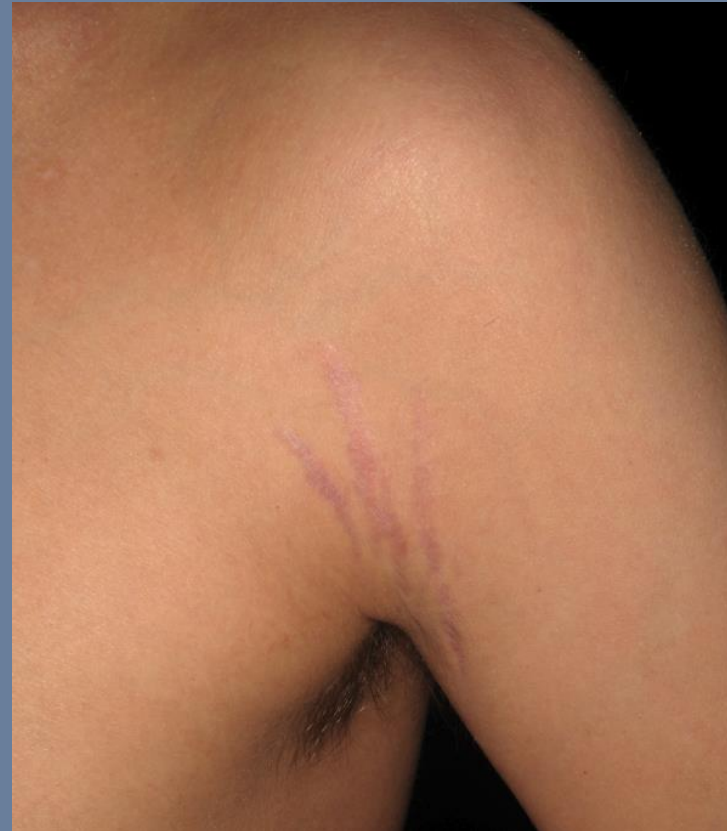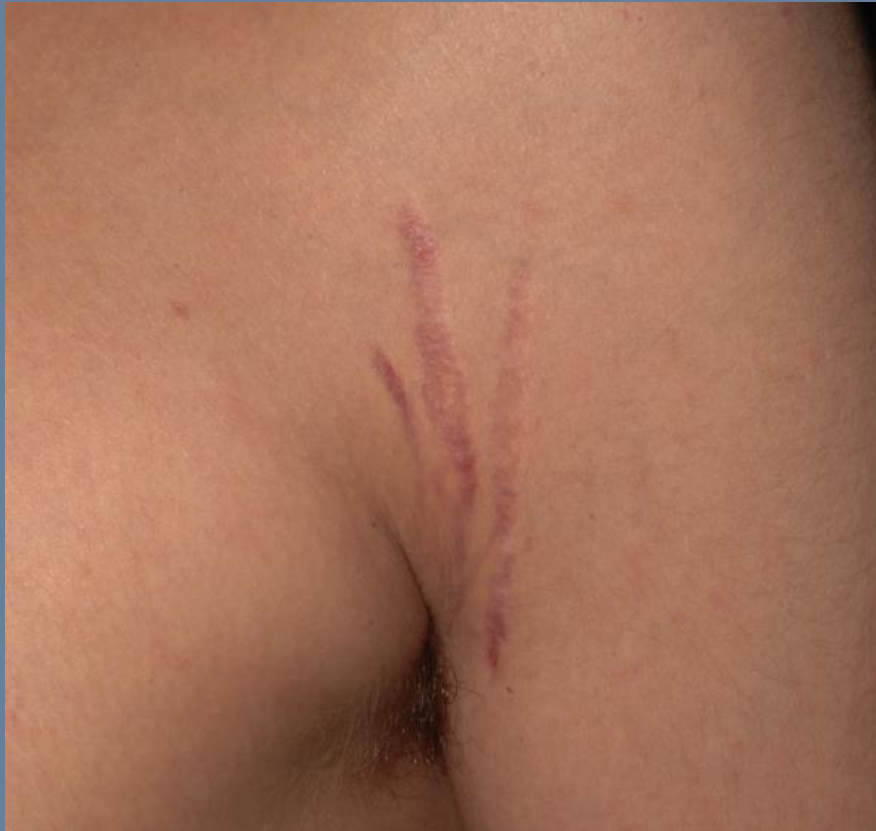Acne scars (Aknenarben)



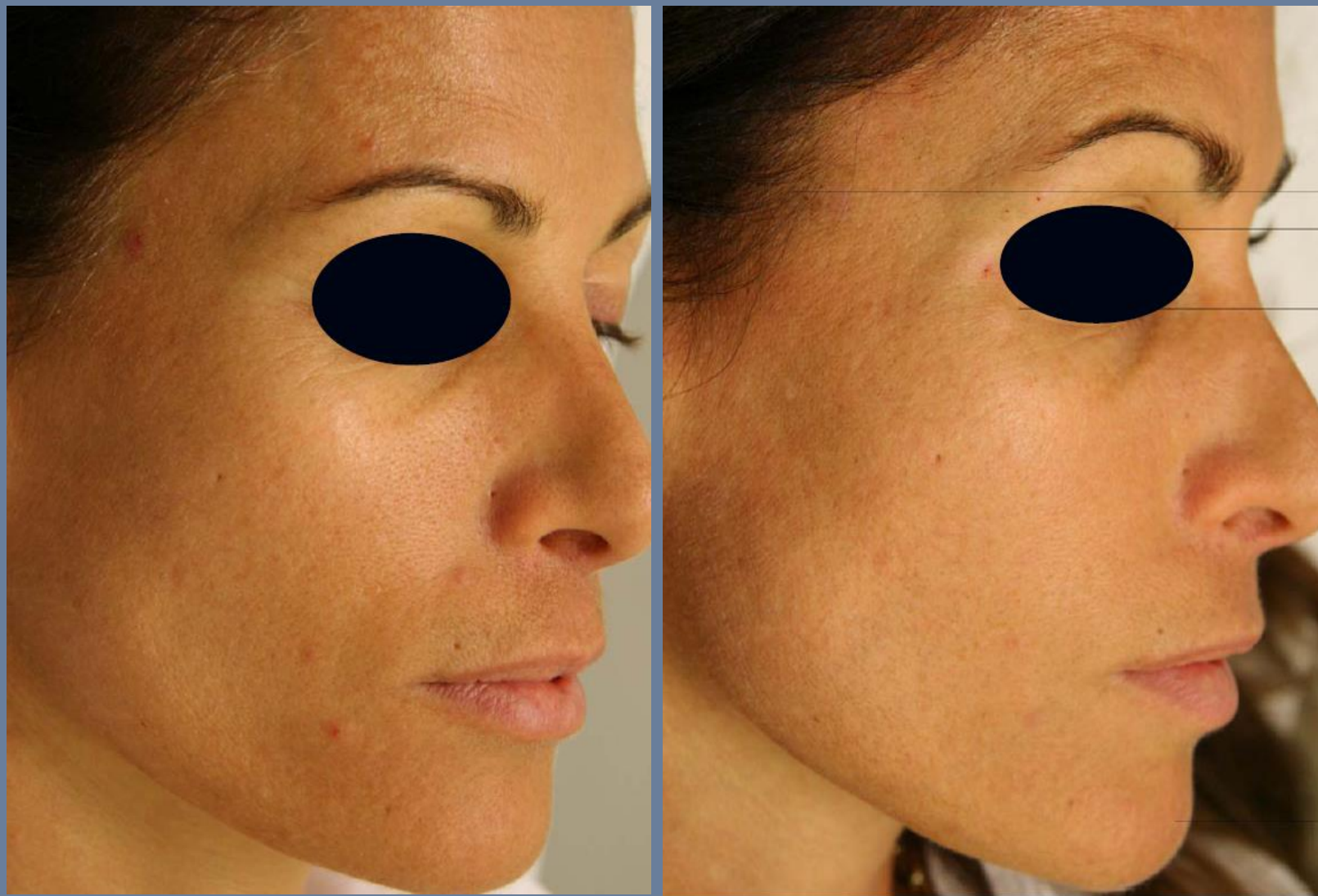Acne scars (Aknenarben)



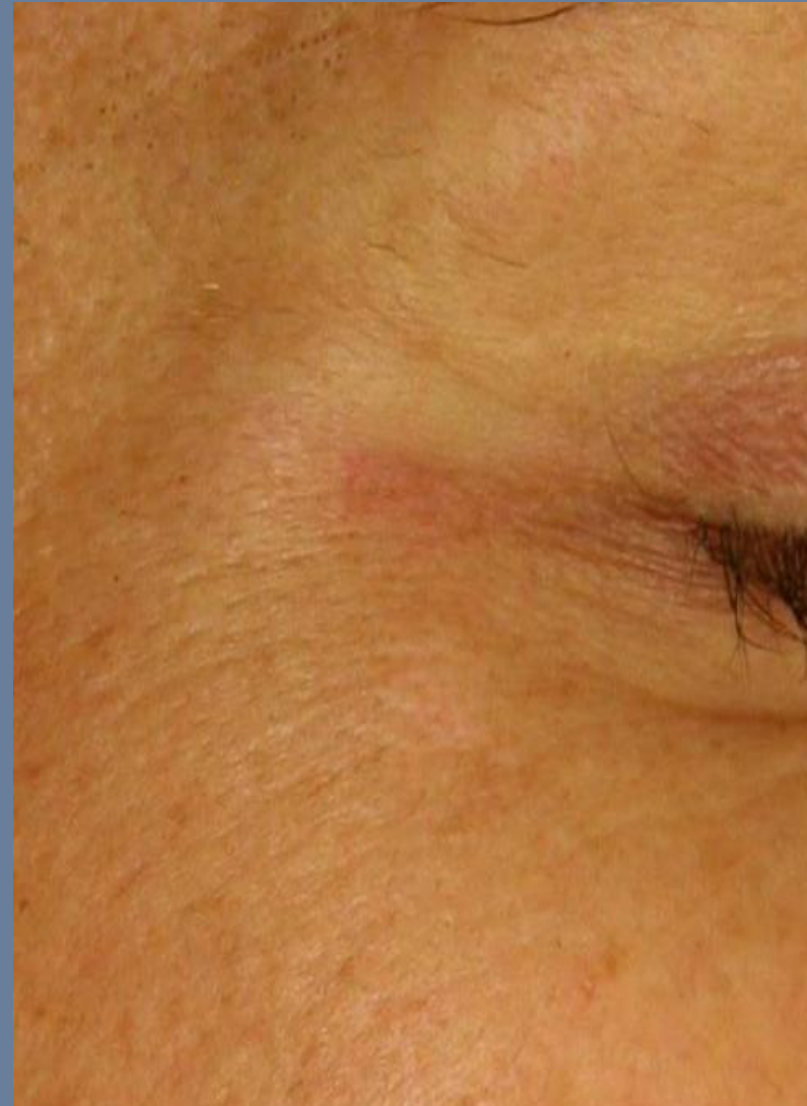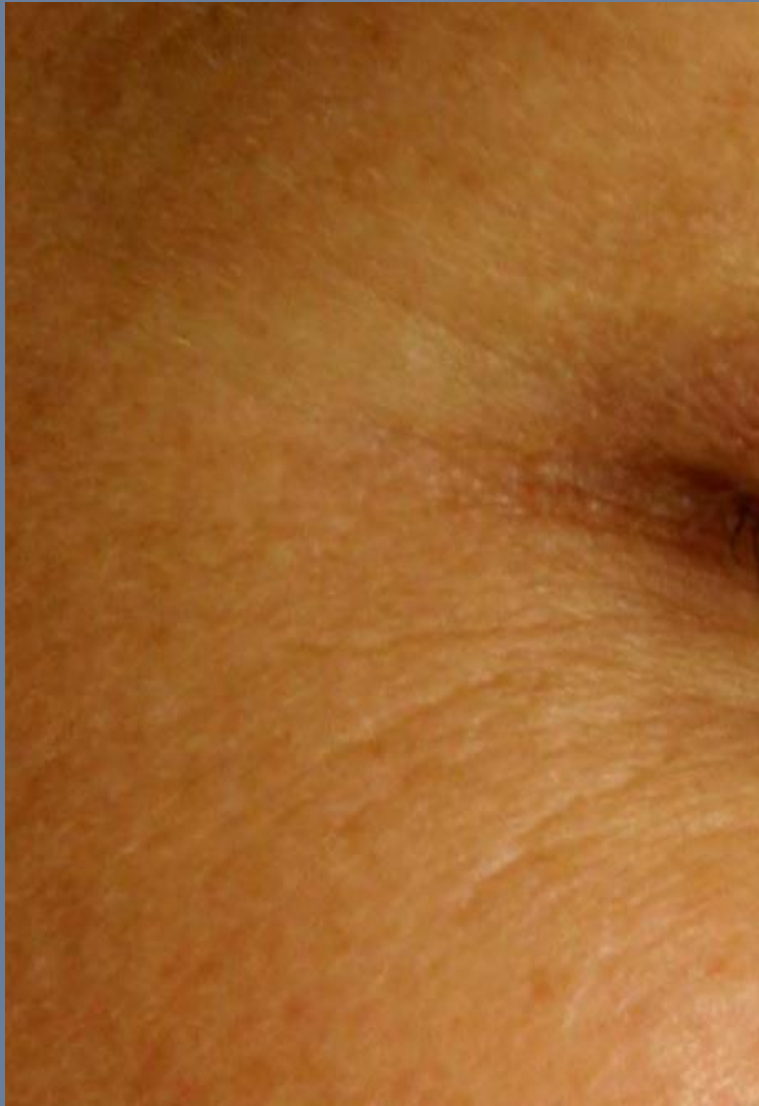Striae



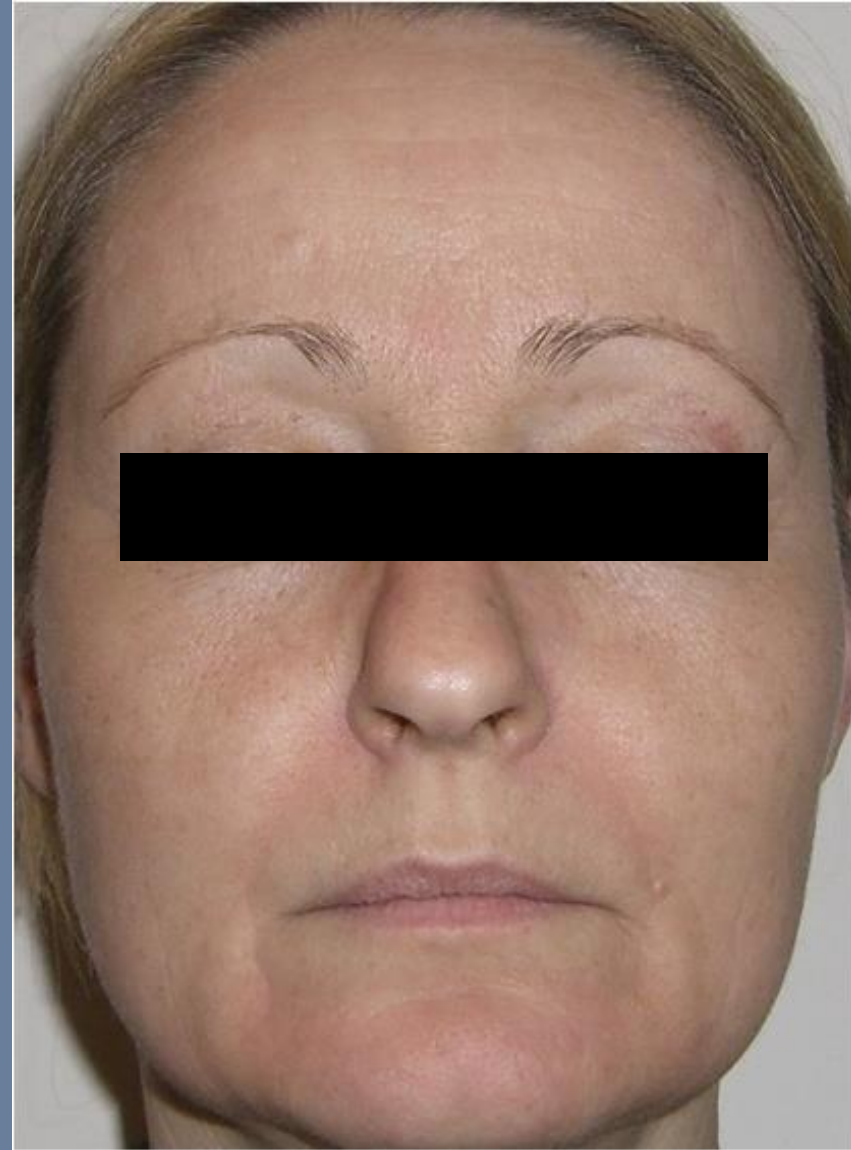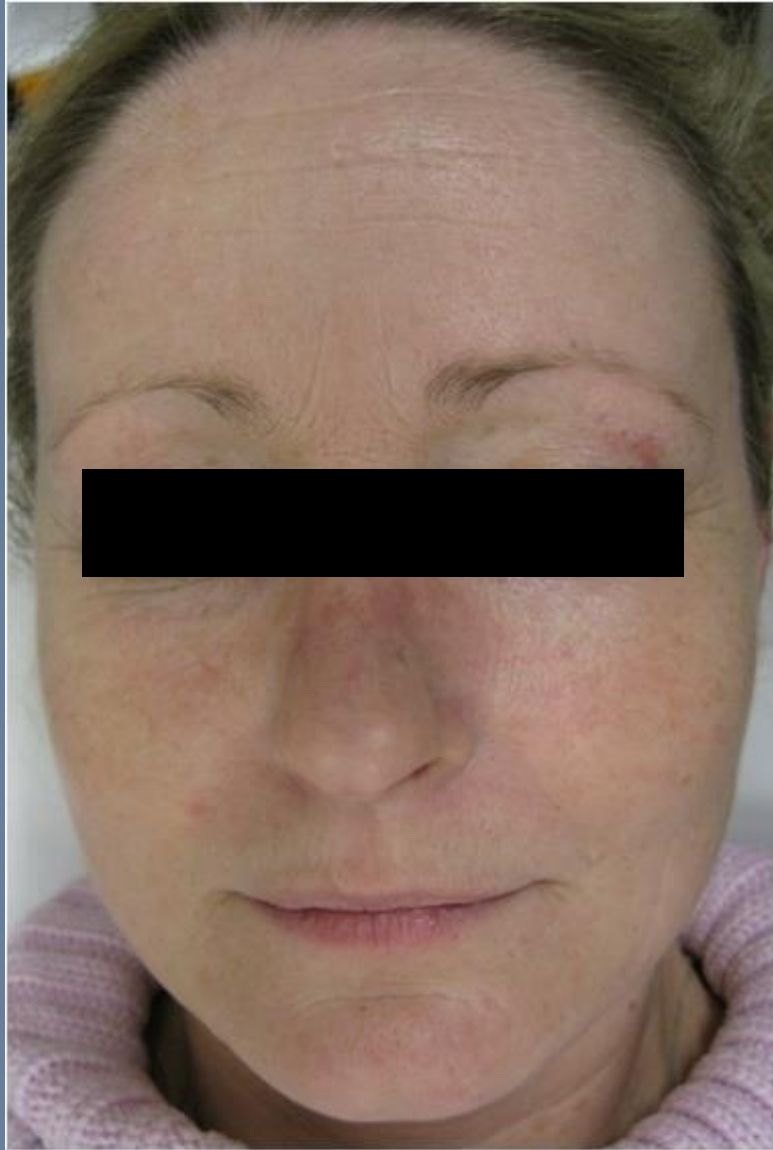Skin rejuvenation



Skin rejuvenation



Skin rejuvenation



Copyright © Asclepion Laser Technologies GmbH.

All rights reserved.

Asclepion Laser Technologies GmbH

Brüsseler Str. 10 | 07747 Jena | Germany

www.aclepion.com

