



Juliet[®]
the feminine laser

Studies Book
Juliet


Asclepion
Laser Technologies

Content

VVA, SUI & GSM.....	5
An innovative dual-phase protocol for pulsed ablative vaginal Erbium: YAG laser treatment of urogynecological symptoms.....	6
Ablative dual-phase Erbium:YAG laser treatment of atrophy-related vaginal symptoms in post-menopausal breast cancer survivors omitting hormonal treatment.....	8
Application of laser technologies for treatment of urinary stress incontinence in women of reproductive age.....	9
Efficacy of Erbium:YAG laser treatment compared to topical estriol treatment for symptoms of genitourinary syndrome of menopause	15
Treatment of the genitourinary syndrome of menopause	24
Laser therapy for the restoration of vaginal function.....	25
Genitourinary syndrome of menopause: an overview of clinical manifestations, pathophysiology, etiology, evaluation, and management.....	26
Vaginal erbium laser: the second-generation thermotherapy for the genitourinary syndrome of menopause.....	34
Genitourinary syndrome of menopause and the use of laser therapy.....	35
Rationale and design for the Vaginal Erbium Laser Academy Study (VELAS): an international multicenter observational study on genitourinary syndrome of menopause and stress urinary incontinence	36
First assessment of short-term efficacy of Er:YAG laser treatment on stress urinary incontinence in women: prospective cohort study.....	37
Minimally invasive laser procedure for early stages of stress urinary incontinence (SUI)	38
Erbium laser in gynecology	39
Laser procedure for female urinary stress incontinence: A review of the literature	40
Effect of non-ablative laser treatment on overactive bladder symptoms, urinary incontinence and sexual function in women with urodynamic stress incontinence	41
Laser therapy for the genitourinary syndrome of menopause. A systematic review and meta-analysis.....	42
Light and Energy Based Therapeutics for Genitourinary Syndrome of Menopause: Consensus and Controversies.....	43
 VULVODYNIA & LICHEN SCLEROSUS	 45
Erbium:YAG Laser for the Treatment of Vulvodynia. A Pilot Study	46
The Er:YAG role in vulvar lichen sclerosus: Report of two cases	47
A minimally invasive treatment method for lichen sclerosus.....	50
 AESTHETIC GYNECOLOGY & VAGINAL RELAXATION SYNDROME	 55
Fractional Erbium Laser for Vaginal Rejuvenation	56
Female intimate surgery: review of methods and trends.....	60
Laser Vaginal Tightening (LVT) – evaluation of a novel noninvasive laser treatment for vaginal relaxation syndrome	70
Treatment of Vaginal Relaxation Syndrome with an Erbium:YAG Laser Using 90° and 360° Scanning Scopes: A Pilot Study & Short-term Results	71
Novel Minimally Invasive VSP Er:YAG Laser Treatments in Gynecology.....	72
 FAQ.....	 73
Frequently asked questions about the Juliet procedure	74

VVA, SUI & GSM

An innovative dual-phase protocol for pulsed ablative vaginal Erbium: YAG laser treatment of urogynecological symptoms

European Journal of Obstetrics & Gynecology and Reproductive Biology 229 (2018) 167–171

Anke R. Mothes, Marion Runnebaum, Ingo B. Runnebaum

Abstract

Objectives: To evaluate a dual-phase protocol for vaginal ablative Erbium:YAG laser treatment in pelvic floor medicine. **Study design:** Data from consecutive patients undergoing vaginal Erbium:YAG laser for first-degree pelvic floor complaints at a certified university urogynecological unit were analyzed. Fractional ablative and thermal treatment with adjustable pulse duration, fluence, and pulse interval was performed in single ten-minute treatment course. Followed up interval was 6 weeks including interviews on expectations, goal setting, goal achievement, and satisfaction (EGGS), vaginal pH, and determination of the Gloria- Bachmann-Index (VHI). Post-procedural complications were classified according to definition and classification of the Clavien-Dindo system. **Results:** Of 84 patients treated, 71 (21% pre-, 79% post-menopausal) were evaluated. 27% had single urogynecological symptoms, 35% had three or more combined symptoms. Minor post-procedural complications occurred in three patients (CD I, n = 1; CD II, n = 3). The ranges of fluence, determined according to the atrophy state, in the first and second phases were 15–35 and 3–12 J/cm², respectively. In patients with genitourinary syndrome of menopause, pre- and post-treatment VHI and pH differed significantly [15.3 ± 4.5 vs. 19.9 ± 2.8 (p < 0.001, Student's t test) and 5.2 ± 0.6 vs. 4.8 ± 0.4 (p = 0.024, respectively)]. Overall, 82% (n = 58; mean age, 58 ± 12 years) of patients were satisfied with the treatment, 84% (47/56) post-menopausal patients were satisfied. **Conclusions:** Vaginal ablative Erbium:YAG laser dual-phase protocol for early urogynecological symptoms was successful and safe, with high patient satisfaction and few, minor complications. Prospective studies are needed to confirm our first data.

Introduction

In urogynecological units in Germany, patients with mild pelvic floor symptoms seek advice regarding non-surgical treatment approaches to increase quality of life (QoL) and to avoid or delay surgery for progressing pelvic organ prolapse (POP). Special attention should be given to patients with an increased risk of POP [1]. With the aging of western populations, health care systems will face enormous increases in the number of patients with age-related diseases, such as pelvic floor disorders and QoL impairment [1,2]. This development, and consideration of the costs entailed [3,4], has led some western governments to support and strengthen preventive medicine, mirrored by medical prevention laws [5]. Our group has examined risk constellations eventually leading to the indication for pelvic floor surgery [1], revealing key roles of difficult obstetric history, aging processes, long-term postmeno-pausal hormone deficiencies, obesity, and familial signs of connective tissue weakness [1,6]. Many affected patients do not have diagnoses necessitating surgery, but they should do every- thing possible to strengthen the connective tissue and pelvic floor. The importance of conservative treatment options for the tissue laxity underlying many urogynecological complaints, which can result from aging or inherited connective tissue weakness, is obvious. According to epidemiological data from the United States, one in three women between the ages of 50 and 59 years and one in two women aged 80 years or older suffers from one or more pelvic floor problems [2]. Abbreviations: CD, Clavien-Dindo; EGGS, expectations, goal setting, goal achievement, and satisfaction; Er:YAG, erbium: yttrium aluminum garnet; GSM, genitourinary syndrome of menopause; POP, pelvic organ prolapse; QoL, quality of life; SUI, stress urinary incontinence; VHI, vaginal health index. * Corresponding author at: Department of Gynecology and Reproductive Medicine, Jena University Hospital, Am Klinikum 1, D-07747, Jena, Germany. E-mail address: mothes@med.uni-jena.de (A.R. Mothes). <https://doi.org/10.1016/j.ejogrb.2018.08.010> 0301-2115/© 2018 Elsevier B.V. All rights reserved. European Journal of Obstetrics & Gynecology and Reproductive Biology 229 (2018) 167–171 Contents lists available at ScienceDirect European Journal of Obstetrics & Gynecology and Reproductive Biology journal homepage: www.elsevier.com/locate/ejogrb Aside from non-surgical treatment options to address early risks related to pelvic floor conditions, such as pelvic floor exercises and the use of topical estrogens, biofeedback, and pessaries, thermal tissue remodeling (hyperthermia) with laser technologies was introduced recently. Although various laser techniques and protocols have been developed for use in urogynecology [7–14], few data are available on their indications, and few studies have compared these technologies or sought to define an ideal laser protocol. In laser techniques employing erbium: yttrium aluminum garnet (Er:YAG) crystals, the laser has a defined wavelength of 2940 nm at the peak of water absorption, which avoids coagulation and tissue necrosis. This paper presents a dual-phase Er:YAG laser protocol for vaginal application to address early urogynecological symptoms.

The innovative dual Er:YAG laser protocol using a fractional ablative mode and a thermal mode right after another was evaluated. By combining the two modes in an Er:YAG laser protocol the advantages of an Erbium laser with its low complication rates and painlessness due to the absence of coagulation are combined with fractional ablation. Pilot data were gathered from patients during interviews using the expectation, goal setting, goal achievement, and satisfaction (EGGS) approach [15], and procedural complications were registered according to the validated classification system of Clavien and Dindo (CD) [16–18].

References

- [1] Mothes A.R., Radosa MP, Altendorf-Hofmann A, Runnebaum IB. Risk index for pelvic organ prolapse based on established individual risk factors. *Arch Gynecol Obstet* 2016;293:617–24. [2] Wu JM, Vaughan CP, Goode PS, Redden DT, Burgio KL, Richter HE, et al. Prevalence and trends of symptomatic pelvic floor disorders in U. S. women. *Obstet Gynecol.* 2014;123:141–8. [3] Barber MD, Maher C. Epidemiology and outcome assessment of pelvic organ prolapse. *Int Urogynecol J.m* 2013;24:1783–90. [4] Subak LL, Waetjen LE, van den Eeden S, Thom DH, Vittinghoff E, Brown JS. Cost of pelvic organ prolapse surgery in the United States. *Obstet Gynecol* 2013;98:646–51. [5] Gesetz zur Stärkung der Gesundheitsförderung und der Prävention; 1368 Bundesgesetzblatt Jahrgang 2015 Teil I Nr. 31, Bonn 24. Juli 2015. [6] Jelovsek JE, Maher C, Barber MD. Pelvic organ prolapse. *Lancet* 2007;369:1027–38. [7] Gaspar A, Brandi H, Gomez V, Luque D. Efficacy of Erbium:YAG laser treatment compared to topical estriol treatment for symptoms of genitourinary syndrome of menopause. *Laser Surg Med* 2017;49:160–8. Table 3 Clavien-Dindo classification of post-treatment complications occurring in the study cohort. CD grade Post-treatment (n = 84) Complication I 1 (1.2 %) Vaginal spotting 2 days post-treatment, lower abdominal discomfort II 3 (3.5 %) Urinary tract infection (n = 1), need for painkiller (n = 2) III - V 0 (0%) None CD, Clavien-Dindo. 170 A.R. Mothes et al. / *European Journal of Obstetrics & Gynecology and Reproductive Biology* 229 (2018) 167–171 [8] Gaspar A, Brandi H. Non-ablative erbium YAG laser for the treatment of type III stress urinary incontinence (intrinsic sphincter deficiency). *Lasers Med Sci* 2017;32:685–91. [9] Salvatore S, Nappi RE, Zerbinati N, Calligaro A, Ferrero S, Origoni M, et al. A 12-week treatment with fractional CO2 laser for vulvovaginal atrophy: a pilot study. *Climacteric* 2014;17:363–9. [10] Leshunov EV, Martov AG. Application of laser technologies for the treatment of urinary stress incontinence in women of reproductive age. *Urologia* 2015;1:36–40. [11] Gambacciani M, Levancini M, Cervigni M. Vaginal erbium laser: the second-generation thermotherapy for the genitourinary syndrome of menopause. *Climacteric* 2015;18:757–63. [12] Gambacciani M, Palacios S. Laser therapy for the restoration of vaginal function. *Maturitas* 2017;99:10–5. [13] Fistonì _c N, Fistonì _c I, Lukanovi9c A, Š. Findri Guštek, Sorta Bilajac Turina I, Frani _c D. First assessment of short-term efficacy of Erb:YAG laser treatment on stress urinary incontinence in women: prospective cohort study. *Climacteric* 2015;18:37–42. [14] Vizintin Z, Lukac M, Kazic M, Tettamanti M. Erbium laser in gynecology. *Climacteric* 2015;18:4–8. [15] Brubaker L, Shull B. EGGS for patient-centered outcomes. *Int Urogynecol J Pelvic Floor Dysfunct* 2005;16:171–3. [16] Dindo D, Demartines N, Clavien PA. Classification of surgical complications: a new proposal with evaluation in a cohort of 6336 patients and results of a survey. *Ann Surg* 2004;240:205–13. [17] Dindo D, Clavien PA. What is a surgical complication? *World J Surg* 2008;32:939–41. [18] Dindo D, Clavien PA. Interest in morbidity scores and classification in general surgery. *Cir Esp* 2009;86:269–71. [19] Bump RC, Mattiasson A, Bo K, Brubaker LP, DeLancey JO, Klarskov P, et al. The standardization of terminology of female pelvic organ prolapse and pelvic floor dysfunction. *Am J Obstet Gynecol* 1996;175:10–7. [20] Hutchinson-Colas J, Segala S. Genitourinary syndrome of menopause and the use of laser therapy. *Maturitas* 2015;82:342–5. [21] Palacios S, Mejia A, Neyro L. Treatment of genitourinary syndrome of menopause. *Climacteric* 2015;18:23–9. [22] Gandhi J, Chen A, Dagur G, Suh Y, Smith N, Cali B, et al. Genitourinary syndrome of menopause: an overview of clinical manifestations, pathophysiology, etiology, evaluation, and management. *Am J Obstet Gynecol* 2016;215:704–11. [23] Mothes AR, Wanzke L, Radosa MP, Runnebaum IB. Bilateral minimal tension sacrospinous fixation in pelvic organ prolapse: an observational study. *Eur J Obstet Gynecol Reprod Biol* 2015;188:1–5. [24] Bachman GA, Notelovitz M, Gonzalez SJ, Thompson C, Morecraft BA. Vaginal dryness in menopausal women: clinical characteristics and nonhormonal treatment. *Clin Pract Sex* 1991;8:3–8. [25] Majaron B, Srinivas SM, Huang HE, Nelson JS. Deep coagulation of dermal collagen with repetitive Er:YAG laser irritation. *Lasers Surg Med* 2000;26:215–22. [26] Dmosek-Olup B, Beltram M, Pizern J. Repetitive Er:YAG laser irritation of human skin: a histological evaluation. *Lasers Surg Med* 2004;35:146–51. [27] Schmitt L, Amann PM, Marquardt Y, Heise R, Czaja K, Gerber PA, et al. Molecular effects of fractional ablative erbium:YAG laser treatment with multiple stacked pulses on standardized human three-dimensional organotypic skin models. *Lasers Med Sci* 2017;32:805–14. [28] Perino A, Cucinella G, Gugliotta G, Saitta S, Polito S, Adile B, et al. Is vaginal fractional CO2 laser treatment effective in improving overactive bladder symptoms in post-menopausal patients? Preliminary results. *Eur Rev Med Pharmacol Sci* 2016;20:2491–7. [29] Sardana K, Garg VK, Bansal S, Sandhu J, Daulaguphu T. Basics of laser-tissue interactions in Lasers in clinical practice. 2nd edition New Delhi, London, Philadelphia, Panama: Jaypee brothers medical publishers (P) LTD; 2018. [30] Alexiades-Armenakas MR, Dover JS, Arndt KA. Fractional laser skin resurfacing. *J Drugs Dermatol* 2012;11:1274–87. [31] Fisher JC. Photons, psychiatrists, and physicians: a practical guide to understanding laser light interaction with living tissue, part 1. *J Clin Laser Med Surg* 1992;10:419–26. [32] Tadir Y, Gaspar A, Lev-Sagie A, Alexiades M, Alinsod R, Bader A, et al. Light and energy based therapeutics for genitourinary syndrome of menopause: consensus and controversies. *Lasers Surg Med* 2017;49:137–59. [33] Mitropoulos D, Artibani W, Gaefen M, Remzi M, Rouprêt M, Truss M. Guidelines on reporting and grading of complications after urologic surgical procedures. *European Association of [88_TD\$DIFF]Urology*; 2012.

Ablative dual-phase Erbium:YAG laser treatment of atrophy-related vaginal symptoms in post-menopausal breast cancer survivors omitting hormonal treatment

Journal of Cancer Research and Clinical Oncology

Anke R. Mothes, Marion Runnebaum, Ingo B. Runnebaum

Abstract

Purpose First evaluation of dual-phase vaginal Er:YAG laser to omit hormonal treatment for atrophy-related symptoms in post-menopausal breast cancer survivors following prolapse surgery. **Methods** Patients with a history of breast cancer at the time of surgery for pelvic organ prolapse were offered non-hormonal vaginal Er:YAG laser treatment when complaining of atrophy-related genitourinary syndrome of menopause. A single 10-min course of dual-phase protocol of pulsed Er:YAG laser (2940 nm, fractional ablative and thermal mode, fluence according to tissue thickness). Follow-up included subjective satisfaction, vaginal pH, vaginal health index (VHI), and complications after 6 weeks.

Results

A total of 16 breast cancer survivors (age 71 years, SD 7) had been seeking treatment for pelvic floor symptoms related to vaginal atrophy at follow-up visits after prolapse surgery. All ablative vaginal Er:YAG laser outpatient procedures were successfully completed, all patients returned to daily activities without a need for analgetic medication. Evaluation was performed after 8.3 (SD 2.5) weeks. Pre-laser VHI scored 16 (SD 4.6) and post-laser VHI 20 (SD 3) with $p = 0.01$. Patients were satisfied in 94% ($n = 15$) regarding symptom relief. **Conclusions** Breast cancer survivors with atrophy-related complaints after pelvic floor surgery may benefit from vaginal application of this innovative dual protocol of Er:YAG laser technology as a non-hormonal treatment approach.

Keywords

Dual-phase vaginal Er:YAG laser protocol · Atrophy-related pelvic floor disorders · Urogynecology · Quality of life · Breast cancer survivorship

Application of laser technologies for treatment of urinary stress incontinence in women of reproductive age

Urologiia. 2015 Jan-Feb;(1):36-40.

Leshunov EV, Martov AG..

Abstract

Urinary incontinence is a significant health problem with considerable social impact. Prospective study was carried out to assess the efficacy and safety of erbium laser (Er:Yag 2940 nm) for treatment urinary stress incontinence in women of reproductive age and its influence on quality of life in the area of sexuality. 37 women (mean age 36,2 years) with mild and moderate urinary stress incontinence were enrolled in the study. The control group consisted of 20 women of similar age. Treatment was delivered in outpatient settings without anesthesia and sedation. Laser system Dermablade MCL 31 (Asclepion Laser Technologies, Germany) with a set of vaginal heads V-Asclepion was employed. All patients underwent examination including Q-tip test and Valsalva maneuver and completed ICIQ-SF H FSFI forms. Within 1 month postoperatively all 37 patients noted significant reduction of urinary stress incontinence symptoms and favorable changes in quality of sexual life. Positive trend was found in urethrovesical junction angle changes. No postoperative complications were registered. The findings from this prospective study confirmed high efficacy and an acceptable safety profile of the new treatment of urinary stress incontinence.

Introduction

Quality of life (eng. - quality of life, abbr. - QOL; Germ. - Lebensqualität, abbr. LQ) - the category which characterises the vital circumstances of life. This determines the degree of self-worthiness and freedom of being for each individual [1].

There are many factors that determine the quality of life of a woman in her reproductive age.

According to the demographic, from the age of 15 through to 49 a woman is considered to be in her reproductive age. During this time she is able to carry and give birth to a child. Although Pregnancy and childbirth are both physiological processes, they also have a significant impact both on the functions of individual organs, as well as on a woman's organism on the whole. These often contribute to the emergence of symptoms that significantly lower the quality of life. One such symptom is the manifestation of urinary incontinence (UI) during pregnancy and after birth.

Many studies have shown that an overwhelming number of women suffering from UI had a previous history of pregnancy and childbirth [2,3,4]. The frequency of UI in pregnant women, maintained by several authors, varies from 12 to 74% [5,6]. The frequency of UI after the first birth is between 24 and 29 % [7].

A study conducted in 2008 shows that the manifestation of the symptoms of urinary incontinence during pregnancy and in the first year after giving birth affects 21.7% of women. Such cases are most frequently observed in the presence of aggravated gynaecological, obstetric and somatic anamnesis. [8]

Furthermore, the frequency of urinary incontinence is directly related to the number of pregnancies of a woman, the presence of recurrent inflammatory diseases of the genital tract, obstetric injuries and dissections of the perineum during childbirth, and the clinical manifestations of the syndrome of undifferentiated connective tissue dysplasia in blood relatives. It is noted that some women's control of urination is restored spontaneously within a few weeks or months after birth; however, according to a study EPINCONT (2003), 42% of women in this group develop persistent stress incontinence over a period of five years. Moreover, amongst women suffering from rare and sporadic episodes of incontinence, persistent postpartum, stress incontinence develops within five years in 92% of cases [9].

According to Russian statistics in 2006, about 30 million Russian women, two thirds of whom are of working age suffer from this severe, chronic relapsing disease: this problem affects one in five women of reproductive age [10]. Overall, 30% to 70% of women in Russia suffer from various types of UI [11].

The effect of UI on the quality of life varies from significant to severe [12]. Without being life-threatening, the pathological loss of urine is considered a "quietly crippling force" - a social disease. Its significance is comparable with depression and diabetes, and the economic costs of diagnosis and treatment in developed countries exceed those of cardio renal bypass surgery and kidney dialysis put together [13, 14]. It affects professional life and employment, and it complicates family and social behaviour.[15].

The majority of patients prefer minimally invasive procedures to surgical treatment [16]. Thus, the search for new treatments for stress urinary incontinence in women is of great relevance. It is necessary to develop more effective minimally invasive methods - treatment that would reduce the incidence of intraoperative and postoperative complications and maximise the rehabilitation of patients.

Laser medicine in urogynecology originated in the last decades of the twentieth century, and at this day and age it is difficult to imagine progress without laser technology, which has opened up new possibilities for resolving numerous health problems. The development of laser medicine in urogynecology is divided into three main categories: laser surgery (using high-energy medical lasers), laser therapy (the use of lasers with low-intensity radiation) and laser diagnostics.

Asclepion Technology

It is known that the causes of stress urinary incontinence is the relaxation of the anatomical structure that supports the periurethral tissue, and the weakening of the urethral sphincter. Damage to the innervation of the pelvic floor muscles during vaginal delivery may lead to loss of strength and neurohumoral regulation of tone of the pelvic muscles, which in turn can cause incontinence and damage to the pelvic floor support. Studies have shown that the ligaments and pubocervical fascia in women with stress urinary incontinence have reduced collagen content, or are characterised by a significant change in collagen. Changes in the metabolism of connective tissue leads to a lack of support for the urinary tract.

The method of local hyperthermia has a significant place in modern medical technology - when the primary effect which is either directly related to the denaturation of collagen, or achieved by heating the selected tissue area to a temperature corresponding or slightly above the beginning of denaturation. Local heating of the tissue in medical practice is carried out using either an infrared laser or radiofrequency radiation, or using an electric current.

The erbium (Er: YAG) laser has a wavelength of 2.94 micron radiation (medium IR range). Its working regime is impulsive. The depth of penetration into the tissue with the erbium laser radiation does not exceed 0.05 mm (50 microns).

The main mechanism of function of the Asclepion V-Spot Technology is the achievement of selective stimulation of the synthesis of sub-mucosal collagen. The immediate reaction is a reduction of collagen fibres and the acceleration of neocollagenesis, which lead to hardening of the tissue and an increase in flexibility. The treated area is gradually reduced and tightened, improving support of the bladder, thereby reducing the symptoms of stress urinary incontinence.

Objective: To prospectively evaluate the clinical efficiency and safety of a minimally invasive treatment of stress urinary incontinence using Asclepion V-Spot Technology in women of reproductive age.

Materials and methods

A total of 37 women aged between 28 and 43 years took part in this study (the average age was 36.2). A control group to assess the impact of anti-stress treatments on the quality of sexual life were 20 patients of a similar age, who do not suffer from symptoms of stress urinary incontinence. The study was conducted in accordance with the rules stipulated in the protocol and GCP and does not contradict the Declaration of Helsinki.

All participants in the study were examined by a physical therapist, a urologist and a gynaecologist.

The following criteria for inclusion in the study were used: previous natural childbirth, normal cytology (pap smear), a negative urine culture, the absence of acute medical illness, a verified diagnosis of stress urinary incontinence in mild to moderate severity.

The following criteria for exclusion were used: pregnancy, lactation, taking photosensitive drugs, injury and / or active infection in the treatment stage, diagnosed vaginal bleeding, and active menstruation.

Laser treatment of stress urinary incontinence is based on the use of a 6th generation erbium laser, Asclepion MCL 31 Er: YAG, 2940 nm with a set of vaginal nozzles (Fig. 1).

The procedure was performed in an ambulatory environment, without anaesthesia or sedation. In the first stage, the vaginal canal is processed in the ablation method along the entire length of the vesico-urethral angle to introitusa, the second stage is non-ablative (thermal mode). The combination of ablative and non-ablative methods allows the achievement of high efficiency treatment with maximum security, eliminating the excessive damage to the vaginal mucosa.

After the procedure, the vagina was treated with a water-based solution of chlorhexidine, for the evacuation of tissue detritus. The period without sexual activity was 72 hours. Topical antiseptics were used for the prevention of infectious complications. In the case of a history of episodes of genital herpes, valacyclovir was administered for prophylaxis at the standard dose for three days before and after the procedure. The patients were able to return to their normal activities on the same day.



Fig. 1 Er: YAG 2940 nm. laser system with a set of 31 MCL vaginal nozzles Asclepion V (Asclepion Laser Technologist).

Results

All patients involved in the study have undergone laser treatment for stress urinary incontinence using Asclepion V-Spot Technology. The procedure was carried out without complications in the intra - and postoperative period. During the procedure, the patients did not notice any pain or discomfort.

To evaluate the clinical efficiency, three fixation points were identified: before treatment, after 1 month and 6 months after the procedure.

During each visit, the following procedures were carried out: a vaginal examination, a PAP-test, a Q-tip test, a Valsalva manoeuvre, a cough test, filling out FSFI questionnaires, the ICIQ-UI SF, QOL SF-36.

During the vaginal examination prior to the procedure, at 1 and 6 months after the procedure, no pathological changes were found. The PAP test has also shown no change in the condition of the cervix before and after the procedure.

A vital part of this stage of patient's examination is the indication of involuntary urine loss. In other words, complaints of stress urinary incontinence need to be confirmed by a demonstration of involuntary loss of urine at the time of physical stress. A cough test is carried out with the women in the gynaecological chair in the lithotomy position. The patient is asked to produce cough shock in a series of 3, i.e. by coughing 3-4 times with intervals between series of aftershocks on a full breath.

Prior to the laser treatment for urinary incontinence in 37 (100%) patients, who participated in the study, a positive cough test was carried out. After 1 month only 6 (16%) patients reacted positively. 6 months after the procedure, the sample was negative in all patients involved in this study.

In international practice, to evaluate the degree of omission of the bladder neck and upper third of the urethra, the so-called Q-tip test is widely used. The test is theoretical, popular and deepens the analytical capabilities of the mechanisms leading to incontinence. The results are shown in Fig. 2 as follows: before the procedure, during the Valsalva manoeuvre, the angle averaged to $45.2 \pm 4.79^\circ$. 1 month after the procedure, it was $-40.4 \pm 1.23^\circ$, After 6 months, it was $-36.2 \pm 2.42^\circ$.

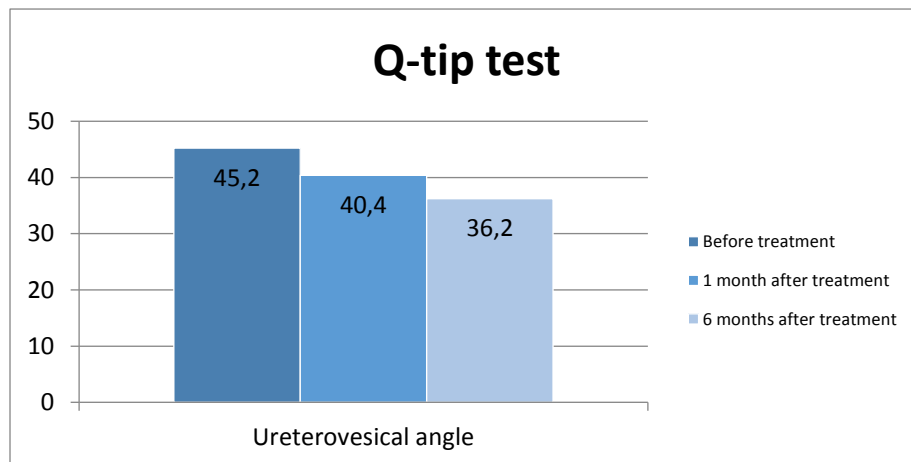


Fig. 2 The dynamics of changes in the urethrovesical angle within 6 months of the study

The Valsalva manoeuvre, or a test under pressure, is necessary to simulate the true state of the urethra at the time of pressure. Despite its extensive routine use in urogynecological practice, the significance of the test is relatively small. Not all patients suffering from stress incontinence demonstrate a positive Q-tip test result, and not all patients demonstrating a positive test result suffer from stress incontinence.

ICIQ-UI SF is an international profile to determine the severity of stress urinary incontinence. By using the ICIQ-UI SF, stress incontinence can be divided into the following four degrees of severity: mild (1-5), medium (6-12), severe (13-18) and very severe (19-21). The results of the study of the dynamics of SUI symptoms are presented in Fig. 3. Prior to the procedure, the average value was $8.3 \pm 2,79$ points. 1 month after the procedure, the average value was $3.1 \pm 1,03$ points. 6 months after the procedure, the average value was $0.6 \pm 0,54$ points ($p < 0.05$).

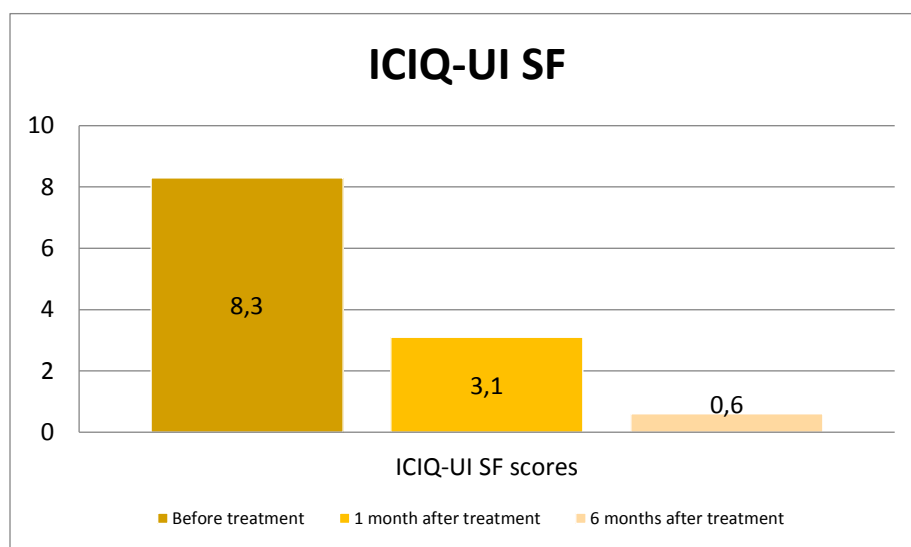


Fig. 3 The change in the severity of symptoms of stress urinary incontinence according to the questionnaire ICIQ-UI SF.

To properly assess the quality of life before and after treatment, a modified questionnaire was used: "SF-36 Health Status Survey" (SF-36). The purpose of the above questionnaire for women with urinary incontinence was to assess not only the effectiveness of medical treatments, but also changes in the patient's quality of life (physical activity, mental state, social role, sexual function, subjective assessment of their health) before and after treatment.

As evident in the results shown in Table. 1, after 1 month there was a significant positive trend following the indicators on the SF-36 scale: RP, BP, GH, MH. Distinct positive dynamics after 6 months including a high level of confidence ($p < 0.01$) was observed in all parameters of the SF-36 scale, except SF. Furthermore, after 6 months, according to all QoL indicators, adaptive and testifying levels showing a high quality of life are observed.

The questionnaire to calculate the index of sexual function in women (Female Sexual Function Index (FSFI)) is required for a prospective evaluation of the quality of sexual life in women before and after anti-stress treatments. The comprehensive format of the questionnaire provides a wide range of applicability of this questionnaire in clinical practice, as well as being very accessible to the respondents themselves.

SF36	Before the procedure	After 1 month	After 6 months
PF	54.4±12.0	65.2±11.6	84.7±14.7**
RP	39.1±18.8	53.3±15.4*	79.3±15.5**
BP	52.3±12.1	70.1±11.6*	81.0±15.1**
GH	54.8±9.6	73.0±9.3*	84.8±14.2**
VT	41.6±11.6	62.4±10.6	75.3±12.2**
SF	65.5±9.8	66.7±10.1	74.7±10.1*
RE	40.2±18.1	62.7±11.8	87.9±15.8**
MH	43.6±9.8	58.5±9.4*	78.8±10.7**

*Table 1 The dynamics of changes in quality of life according to the SF-36 questionnaire. Please note: * - $p < 0.05$, ** - $p < 0.01$ (in comparison to before the procedure)*

The results of the investigation on the sexual function of women before the procedure are shown in Table 2.

Headings of the FSFI questionnaire	Indicators (M ± SD) Norm	Indicators (M ± SD) SUI	FSFI changes in comparison to the norm in (%)	P
Attraction	5.12 ± 0.37	4.14 ± 1.57	-14.58%	<.0001*
Arousal	4.67 ± 0.74	4.21 ± 1.47	-16.20%	<.0001*
Lubrication	4.8 ± 0.56	4.36 ± 1.36	-9.17%	<.0001*
Orgasm	5.5 ± 0.87	4.21 ± 1.33	-13.79%	<.0001*
Satisfaction	5.2 ± 0.61	4.34 ± 1.44	-14.98%	<.0001*
Pain	5.68 ± 0.43	4.62 ± 1.51	-18.34%	<.0001*

Table 2 The comparison of a healthy population with patients suffering from stress urinary incontinence. Note: M - average, SD - standard deviation. $p \leq 0.05$ - a statistically significant result.

As shown in the results table of the FSFI questionnaire comparing healthy women with women suffering from stress urinary incontinence, it was found that all sections of the questionnaire results are reduced in the group of women with SUI. Moreover, comparing groups of all sections of the questionnaire revealed a strong statistical link - <.0001, which indicated that women with SUI have a clearly decreased sexual function in comparison with a healthy population. The research showed a decreased sexual function (performance in the FSFI questionnaire <27) is present in 18% of women who were not complaining about any sexual dysfunction.

	Improvement	No changes
Attraction	28 (75%)	9 (24%)
Arousal	31 (73%)	6 (16%)
Lubrication	29 (78%)	8 (21%)
Orgasm	21 (57%)	16 (43%)
Satisfaction	32 (77%)	5 (13%)
Pain	16 (43%)	21 (57%)
Total	31 (84%)	6 (16%)

Table 3 The change in the FSFI questionnaire indicators in all sections in percentages (%).

The data shown in Table 3 shows that in the total population, female sexual function has improved in 84% of patients, and has not changed in 16%. This proves the high efficiency of this type of treatment, and a positive effect of laser correction of stress urinary incontinence in women, thus restoring their sexual function.

Analysis of the safety profile: the presence of vaginal discharge of a bloody consistency was 20 (55%), low-grade fever 6 (16%), cystalgia 2 (6%). Any side effects did not require an appointment for special treatment and were resolved on their own in up to 3 days.

Discussion

The particular feature of treating women of reproductive age with stress urinary incontinence, is their inability to perform most common operational procedures. This is due to the fact that subsequent births can nullify the result of any surgical intervention. Conservative treatment methods recommended to women of such reproductive age result in a temporary effect, yet they do not allow patients to return to active life. In this regard, the development of minimally invasive treatments that do not require a rehabilitation period and anaesthetics is a priority in medical science.

Using modern laser technology enables us to convert loose and untuned connective tissue into densely formed connective tissue. This is done through remodelling of the extracellular matrix. Qualitative changes in the connective tissue at the expense of the synthesis of collagen and elastin proteins restore the lost function of the carcass.

The use of 6th generation MCL31 erbium laser (Asclepion Laser Tech.) allows for a large variability of the duration and intensity of the pulse, and furthermore enables us to perform the individual selection of treatment for each individual case. Data analysis of the study shows the high efficiency of the Asclepion V-Spot Technology on the symptoms of stress urinary incontinence in women of reproductive age.

Objective criteria for the adequacy of the treatment are as follows: lack of clinical incontinence, lack of sexual dysfunction, restoration of normal MP and urethral syntopy MP and the urethra and also the improvement in the quality of life of the patient.

The observed changes in the results of the Q tip test confirm periurethral connective tissue remodelling and improvement of maintenance functions, which in turn leads to changes in the urethrovesical angle and restores the continence function. This data is equally supported by the reduction of episodes of urinary incontinence.

Within the 6 months of monitoring, improvement in sexual function of women was observed, which is important in terms of prevalence of female sexual dysfunction in women with stress urinary incontinence. Changes in intra-coital sensitivity are also associated with a change in the innervation and blood supply of the anterior wall of the vagina.

The objectification of sensations of the patient by means of assessing the level of quality of life provides an opportunity to adequately analyse the results of the treatment. In this study, positive dynamics in changes in the quality of life of patients with stress urinary incontinence were reported, improving both mental and physical aspects.

No post-operative complications were reported. This proves the safety of the method in the absence of inflammatory changes and reactions, which is an advantage over previously well-known methods.

Laser correction of stress urinary incontinence using the Asclepion V-Spot Technology is a modern, minimally invasive method of treatment, with a high level of efficiency and a high safety profile.

References

1. Spilker B. Quality of life assessments in clinical trials / R.d.Hays, Fayers Oxford University Press: Oxford, New York, Tokyo, 1998. - 360 p.
2. Alexandrov, V.P. Stress Urinary Incontinence in Women / V.P. Alexandrov, A.V. Kurenkov, E.V. Nikolayeva. СПб: СПбМАПО, 2006. - 92 p.
3. Apolikhina, I. A. Obstetric and gynecologic risk factors of urinary incontinence / I.A. Apolikhina, V.V. Romikh // *Obsterocs and gynecology*. 2003. - № 5. - P. 7-10.
4. Kulakov, V.I. Obstetric and gynecologic risk factors of urinary incontinence in women / V.I.Kulakov, I.A. Apolikhina, A.D. Deyev // *Obsterocs and gynecology*. 2005. - № 3. - p. 32-36.
5. Risk factors for urinary incontinence among middle-aged women / K.N. Danforth, M.K. Townsend, K. Lifford et al. // *Am. J. Obstet. Gynecol.* 2006. -Vol. 194, №2. -P. 339-45.
6. Risk factors for urinary incontinence in women / F. Parazzini, E. Colli, G. Origgi et al. // *Eur. Urol.* 2000. - Vol. 37, № 6. - P. 637-643.
7. Loran, O.B. Epidemiology, etiology, pathogenesis, diagnosis of urinary incontinence / O.B. Loran // *Пленум Правления Российского общества урологов: материалы*. М., 2001. - P. 21-41.
8. Zakrytnaka, O.S. Prediction of urinary incontinence in women during pregnancy and after childbirth with justification prevention // dissertation, PhD.
9. Hannestad, Y.S. Help-seeking and associated factors in female urinary incontinence: the Norwegian EPINCONT study / Y.S. Hannestad, G. Rortveit, S. Hunskar // *Scand. J. Prim. Health Care*. 2002. - Vol. 20. - P. 102-107.
10. Alayev, Y.G. Urinary disorders / Y.G. Alayev, V.A. Grigorian, Z.K. Gadzhayeva, M.: Litterra, 2006. - 208 p.
11. Apolikhina, I.A. Prevalence and social aspects of urinary incontinence in women / I.A. Apolikhina, V.V. Konstantinov, A.D. Deyev // *Obsterics and gynecology*. 2005. - № 5. - G. 32 - 36.
12. Prevalence and impact on quality of life of urinary incontinence: in Japanese working women / L Akari, M. Beppu; M. Kajiwara; Y. Mikami // *Urology*. 2005. - Vol; 66, № 1.-P. 88-93.
13. Prevalence of urinary incontinence and other urological symptoms in the non-institutionalized elderly / A.C. Diokno, B.M. Brook, M.B. Brown et al. // *J. Urol.*-1986.-Vol. 136.-P. 1022-25.
14. Patient-reported impact of urinary incontinence—results from- treatment seeking women in 14 European countries / B. Monz, M.E. Pons, C. Hampel et al. // *Maturitas*. -2005. Vol. 52, Suppl -2. - P. S24-34.
15. Patterns of constipation in urogynecology: clinical importance and pathophysiologic insights / M. Soligo, S. Salvatore, A.V. Emmanuel et al. // *Am. J. Obstet. Gynecol.* 2006. - Vol. 195, № 1. - P. 50-5.
16. Assessment of bother someness and impact on quality of life of urinary incontinence in women in France, Germany, Spain and the UK / S. Papanicolaou, S. Hunskar, G. Lose, D Sykes // *BJU Int*. 2005. - Vol. 96, № 6.- P. 831-8.

Efficacy of Erbium:YAG laser treatment compared to topical estriol treatment for symptoms of genitourinary syndrome of menopause

(2016) *Lasers SurgMed*. Aug 22.

Adrian Gaspar MD, Hugo Brandi PhD, MD, Valentin Gomez MD, Daniel Luque MD;

Abstract

Objectives The objective of this prospective comparative cohort study was to establish the effectiveness and safety of Erbium:YAG (Er:YAG) laser treatment for genitourinary syndrome of menopause and to compare it with an established topical estriol treatment.

Methods Fifty patients with genitourinary syndrome of menopause were divided into two groups. The estriol group received a treatment of 0.5 mg estriol ovules for 8 weeks and the laser group was first treated for 2 weeks with 0.5 mg estriol ovules 3 times per week to hydrate the mucosa and then received three sessions with 2,940 nm Er:YAG laser in non-ablative mode. Biopsies were taken before and at 1, 3, 6, and 12 months post-treatment. Maturation index, maturation value and pH were recorded up to 12-months post-treatment, while the VAS analysis of symptoms was recorded up to 18 months post-treatment.

Results Statistically significant ($P < 0.05$), reduction of all assessed symptoms was observed in the laser group at all follow-ups up to 18 months post-treatment. Significant improvement in maturation value and a decrease of pH in the laser group was detected up to 12 months after treatment. The improvement in all endpoints was more pronounced and longer lasting in the laser group. Histological examination showed changes in the tropism of the vaginal mucosa and also angiogenesis, congestion, and restructuring of the lamina propria in the laser group. Side effects were minimal and of transient nature in both groups, affecting 4% of patients in the laser group and 12% of patients in the estriol group.

Conclusions Our results show that Er:YAG laser treatment successfully relieves symptoms of genitourinary syndrome of menopause and that the results are more pronounced and longer lasting compared to topical estriol treatment.

Introduction

Vulvovaginal atrophy can be progressive and unlikely to resolve without intervention. It can have a significant effect on woman's sexual health and quality of life (QOL) [1]. It is estimated that 10–45 percent of postmenopausal women have symptoms of vulvovaginal atrophy [1,2]. Despite the prevalence of symptoms, only 20–25 percent of symptomatic women seek medical attention [3]. In 2014, genitourinary syndrome of menopause (GSM) has been accepted as a consensus new terminology for vulvovaginal atrophy and defined as a collection of symptoms and signs associated with a decrease in estrogen and other sex steroids syndrome, including but not limited to genital symptoms of dryness, burning, and irritation; sexual symptoms of lack of lubrication, discomfort or pain, and impaired function; and urinary symptoms of urgency, dysuria, and recurrent urinary tract infections [4]. Before menopause, in the presence of endogenous estrogen levels, the vagina is characterized by a thickened rugated vaginal surface, increased vaginal blood flow, and vaginal lubrication. Estrogen is a dominant regulator of vaginal physiology, its effects including increased blood flow, improved epithelial thickness, reduced pH, and increased secretions. GSM is most commonly associated with the diminished estrogen levels that accompany spontaneous or induced menopause and aging [1]. Estrogen plays an essential role in maintaining the elasticity and health of genital tissues. Declining levels of estrogen during menopause result with increased tissue fragility and higher risk of vaginal and urinary infections, irritation, dryness, urogenital pain, and vaginal tissue trauma. GSM is characterized by changes in the quantity and quality of vaginal secretions, loss of collagen, adipose- and water-retaining ability. The vaginal walls become thinner, less elastic, and pale with loss of rugation; the vaginal surface becomes friable with petechiae, ulcerations, and bleeding often occurring after minimal trauma [1,5].

The prevalence of urogenital symptoms in postmenopausal women includes vaginal dryness in 29% of patients, burning or irritation in 21.3%, nocturia/pollakiuria in 16.4%, urinary incontinence in 15.2%, dyspareunia in 14%, chronic leukorrhea in 13.5%, and dysuria in 7.2% of patients [5]. The goals of GSM management are to alleviate symptoms and to reverse atrophic anatomic changes. Treatment with exogenous estrogen preparations delivered either systemically or locally is the therapeutic standard for prescription therapies. Even though systemic estrogen therapy (e.g., oral, transdermal) is an effective treatment, there are some drawbacks to be considered. Women with a previous medical history of hormone-dependent cancer must be evaluated and informed in relation to the risks/benefits [6]. There is a high rate of patient abandonment of hormone replacement therapy (HRT) and not all patients wish to receive HRT; many have valid concerns to its long-term use. There is also speculation that recurrences of certain hormone-dependent cancers are dose dependent. In the study by Von Schoultz [7], researchers established that different doses of estrogen and progesterone and treatment regimens for menopausal hormone therapy may be associated with the recurrence of breast cancer. Local estrogen preparations in the form of tablets, rings, or creams are often prescribed as they are perceived to have a low systemic absorption and have been shown to result in significant symptomatic benefit [1,8].

However, there are some limitations to these therapies, such as the fact that the beneficial effect is evident only for the time of the therapy and in general its effect stops when the treatment is discontinued, and also that these changes affect mostly the surface of the vagina [6]. Changes during vaginal aging affect the whole vaginal wall, not only the epithelium, which is significantly reduced in thickness, as well as the glycolytic load [8]. The lamina propria of the atrophic vagina has decreased extracellular matrix components and reduced vascularization and water-retaining capacity [9]. Local estrogen treatments have a high recurrence rate once they are discontinued; symptoms tend to reappear after the treatment has been completed, with systemic effects being reported during the use of some vaginal estrogens. On the other hand, patients are increasingly expressing high concern over cancer-related consequences, and there is a lack of long-term documented studies on the safety of these absorbed estrogens. This is the reason why in recent times new treatments that work on the long-term and also on the level of connective tissue and vascularization are being developed, some of which represent important alternatives. Thermal laser treatment is one of the newer treatments. The medical effects of lasers are well established in terms of biochemical, ablative, and thermal effects. Depending on the laser energy delivered and the time during which it is delivered, the tissue effect ranges from more a destructive one (e.g., tissue ablation) to a thermal only effect (e.g., coagulation, photo chemical reactions). The special SMOOTH mode produces a fast sequence of low-fluence laser pulses inside and overall super-long pulse allowing the heat to dissipate and distribute approximately 200mm deep into the mucosa [10]. In this way, a controlled deep thermal effect is achieved, without causing ablation. There have been many reports that thermal energy from the laser source, especially in a moist environment, enhances the collagen component and the vascularization [11–13]. Collagen remodeling and new collagen synthesis has been suggested as a mechanism of laser induced skin resurfacing and remodeling of vaginal connective tissue [10,13,14]. Minimally invasive, non-ablative thermal Erbium:YAG (Er:YAG) laser treatment for gynecological applications has been previously described as a safe and effective option for the treatment of stress urinary incontinence [15]. Recently, non-ablative thermal Er:YAG laser therapy has demonstrated improvement of GSM symptoms in a pilot study of 45 postmenopausal women [16].

The objective of this study was to establish safety and effectiveness of non-ablative Er:YAG laser (RenovaLase1) treatment (3 sessions over 8 weeks) and to compare the effectiveness and durability of the new treatment to the standard topical estriol treatment administered during the same time period (8 weeks). In order to assess and compare the durability of the effect after treatment has been stopped, 8 week duration was chosen for both treatment regimes.

Methods

Fifty post-menopausal patients were recruited in this pilot comparative cohort study conducted at the Gynecology Department of the Faculty of Medicine at Mendoza University in Mendoza, Argentina, in the period from March 2012 till November 2012. Inclusion criteria were: measured estradiol level of 20 pg /ml and experience of more than one of the following symptoms of GSM: dyspareunia, vaginal dryness, vaginal burning or irritation, and chronic leukorrhea. Exclusion criteria included pelvic organ prolapse greater than stage I, previous vaginal surgery, smoking, subjection to any hormonal therapy in the 6 months prior to inclusion into the study and infectious leukorrhea. Patients' BMIs ranged from 24 to 28.

The active control group of 25 patients (estriol group) received an 8-week treatment of 0.5mg of estriol ovules. The ovules were administered daily during the first 2 weeks, three times a week in weeks 2–4, then twice a week in weeks 4–8. The laser treatment group of 25 patients first received a 2 week pre-treatment with 0.5mg estriol ovules (three ovules/week)

and then received 3 sessions of laser therapy during the course of 8 weeks. The rationale for the pre-treatment comes from the fact that the Erbium laser has high absorption in water and the methods of the thermal-only Er:YAG mucosal treatment requires a highly moist environment. Because of that, in order to improve the hydro retention of the tissue, a pre-treatment was done by applying 0.5mg of estriol ovules three times per week for 2 weeks. Then on the 3rd week, the first laser treatment was performed with a 2,940 nm Er:YAG laser (XS Dynamis, Fotona, Slovenia) using a special modality, SMOOTH mode, which delivers laser energy in a non-ablative, thermal-only technique based on the manufacturer's proprietary pulsing sequence. A total of three treatments, once every 3 weeks, were performed. In the treatment protocol the laser irradiation was applied in two steps, firstly to the whole vaginal canal and then to the introitus area. A special laser speculum was introduced into the patient's vagina to serve as a guide for the laser beam delivery system, which is an Er:YAG handpiece with a 3608 circular adapter.

Several longitudinal passes using a step-by-step retraction of the handpiece were performed, delivering cumulative energy between 1,000 and 1,500 J to the whole vaginal canal. In the second step of the procedure, laser energy was delivered to the entrance of the vaginal canal, the vestibule, and introitus area. No anesthesia was used before or during the session. Patients were instructed to avoid sexual intercourse and activities that can increase intra-abdominal pressure during the initial post-op period of 7 days after the intervention. During the laser intervention, patient discomfort, and treatment tolerability, as well as potential adverse events were monitored.

Biopsies for histological examination from six patients from each group were taken with Tischler biopsy forceps before treatment and 1, 3, 6, and 12 months post treatment. The biopsy location was at the junction of the mid third with the distal third of the anterior vaginal wall. Lidocaine anesthesia was applied before procedure.

The maturation index (MI), which shows increased ratios of intermediate and parabasal cells compared to superficial cells, was established by cytological examination using light microscopy. The data of MI were then used to calculate the maturation value (MV) [17]. For normally menstruating women, the MV range is between 50 and 95; for women with various degrees of GSM, the MV is below 50. MI was measured before intervention and at 1, 3, 6, and 12 months after starting the treatment. Vaginal pHtesting, used to evaluate estrogen deprivation, was performed before and 3 and 12 months post treatment. VAS (Visual Analog Scale) analysis was performed for assessment of the severity of the following GSM symptoms: dyspareunia, dryness, irritation, and leukorrhea. Patients assessed the severity of the symptoms as: severe—3, moderate—2, mild—1, and none—0. Assessments were made before intervention and at 1, 3, 6, 12, and 18 months after starting the treatment. Results were statistically analyzed using Student's t-test, values below 0.05 were considered statistically significant.

Results

Fifty post-menopausal patients with typical GSM symptoms were recruited in this study in the period from March 2012 till November 2012. Patient's demographic data are included in Table 1.

TABLE 1. Patient Data

	Er:YAG laser group (n = 25)	Estriol group (n = 25)	P-value
Age (years ± SD)	55.0 ± 6.7	53.5 ± 5.7	0.3929
Menopause entry ^a	49.0 ± 4.0	48.6 ± 2.8	0.7128
Parity	2.1 ± 1.5	2.6 ± 1.7	0.3395
BMI (kg/m ²)	26.2 ± 1.4	25.9 ± 1.3	0.4335
Estradiol (pg/ml)	14.1 ± 3.1	13.6 ± 3.2	0.5233
POP stage I	9/25 (36%)	14/25 (56%)	/
GSM symptoms			
Dyspareunia	25/25 (100%)	25/25 (100%)	
Irritation	25/25 (100%)	25/25 (100%)	
Dryness	25/25 (100%)	25/25 (100%)	
Chronic leukorrhea	18/25 (72%)	21/25 (84%)	

^aMenopause duration was not more than 7 years.

There were no statistically significant differences between the groups' demographic data ($P < 0.05$). The estriol group had a higher baseline percentage of stage I POP, which did not seem to impact the symptoms of GSM or estradiol levels, which were very similar in both groups. Symptoms of dyspareunia, irritation, dryness, chronic leukorrhea (Table 2 and Fig. 1a–d) were assessed on the 0–3 VAS scale. There was a statistically significant ($P < 0.05$) reduction of all the symptoms in both groups up to the 6 month follow-up; however, the relief of symptoms was more prominent in the laser group at all follow-ups. More importantly, the effect of the laser treatment remained statistically significant at the 12 and 18-month follow-up, while the effects of the estriol treatment were diminished at the 12-month follow-up and at 18 month follow-up some were even significantly worse than before treatment (Table 2 and Fig. 1a–d). Side effects included a sensation of warmth and related mild-to-moderate pain in 4% of patients, as well as slight transient edema. One patient also developed transitory pain after laser treatment and one patient experienced spotting. In the estriol group, 8% of patients experienced spotting, 4% mastodynia, and 12% abdominal pain.

TABLE 2. Severity of GSM Symptoms Before and at 1, 3, 6, 12 and 18 Month Follow-Ups

Er:YAG laser group ($n = 25$)						
	Before	1 month	3 months	6 months	12 months	18 months
Dyspareunia	2.44 ± 0.65	1.52 ± 0.77* ($P < 0.001$)	1.00 ± 0.96* ($P < 0.001$)	1.08 ± 1.00* ($P < 0.001$)	0.96 ± 0.98* ($P < 0.001$)	1.60 ± 0.65* ($P < 0.001$)
Irritation	2.04 ± 0.79	1.16 ± 0.55* ($P < 0.001$)	0.88 ± 0.88* ($P < 0.001$)	0.96 ± 0.93* ($P < 0.001$)	1.48 ± 0.82* ($P < 0.05$)	1.56 ± 0.58* ($P < 0.01$)
Dryness	2.24 ± 0.60	1.12 ± 0.78* ($P < 0.001$)	0.80 ± 0.82* ($P < 0.001$)	1.04 ± 0.89* ($P < 0.001$)	1.04 ± 0.73* ($P < 0.001$)	1.52 ± 0.71* ($P < 0.001$)
Chronic leukorrhea	2.28 ± 0.83	0.84 ± 0.90* ($P < 0.001$)	0.84 ± 0.90* ($P < 0.001$)	0.60 ± 0.71* ($P < 0.001$)	1.00 ± 0.71* ($P < 0.001$)	1.28 ± 0.74 ($P = 0.054$)
Estriol group ($n = 25$)						
Dyspareunia	2.28 ± 0.74	1.80 ± 0.82* ($P < 0.001$)	1.60 ± 0.96* ($P < 0.001$)	1.88 ± 0.83* ($P < 0.01$)	2.24 ± 0.72	2.36 ± 0.70
Irritation	2.00 ± 0.65	1.48 ± 0.59* ($P < 0.001$)	1.20 ± 0.82* ($P < 0.001$)	1.32 ± 0.85* ($P < 0.01$)	2.12 ± 0.53	2.28 ± 0.61x ($P < 0.01$)
Dryness	2.28 ± 0.46	1.32 ± 0.85* ($P < 0.001$)	1.20 ± 0.96* ($P < 0.001$)	1.68 ± 0.80* ($P < 0.01$)	2.36 ± 0.49	2.40 ± 0.50x ($P < 0.05$)
Chronic leukorrhea	1.71 ± 0.64	0.95 ± 0.74* ($P < 0.001$)	0.62 ± 0.74* ($P < 0.001$)	0.86 ± 0.96* ($P < 0.01$)	1.48 ± 0.82	1.76 ± 0.83x ($P < 0.01$)

The values present mean ± standard deviation. Statistical significance was determined using student's *t*-test. *P* values <0.05 were considered statistically significant. Bold values represent statistically significant mean as compared to mean before treatment. *indicates statistically significant improvement. x indicates statistically significant worsening.

Overall, side effects in both groups were minimal and of a transient nature. The MV in the estriol group improved significantly at 1 and 3 month follow-up and then it started declining, with still significant, although borderline improvement (22.5–25 points) after 12 months. In comparison to this, the laser group improvement was much higher, from 20.8 to 52.2 points after 12 months and was highly statistically significant ($P < 0.001$) (Table 3 and Fig. 2a). The pH value was measured before and after 3 and 12 months and also shows a statistically significant decrease of pH value even at the 12-month follow-up, while the decrease at the estriol group was not as pronounced and has diminished at the 12-month follow-up (Table 3 and Fig. 2b). Histological examination (Fig. 3), which was done in six patients before and 1, 3, 6, and 12 months after the laser treatment, showed changes in the tropism of the vaginal mucosa. Changes in the epithelial tissue included parakeratosis and acanthosis (thickness). Changes in the lamina propria included an initial vasodilation with pericapillary oedema due to the photothermal effect, with major congestion and improvement in vascularization. On the other hand, there was an increase in the amount of blasts and the fibrillar components of the extracellular matrix (which could possibly be the result of increased collagenesis). Finally, a marked angiogenesis could be seen at all follow-ups months with a noticeable papillomatosis.

TABLE 3. Results of the Maturation Value and pH for Both Groups

	Before	1 month	3 months	6 months	12 months
Erbium:YAG laser group (n = 25)					
Maturation value	20.8 ± 5.4	33.3 ± 13.3* (P < 0.001)	39.7 ± 11.5* (P < 0.001)	47.9 ± 12.7* (P < 0.001)	52.2 ± 8.5* (P < 0.001)
pH value	5.0 ± 0.4	/	4.1 ± 0.4* (P < 0.001)	/	4.4 ± 0.6* (P < 0.001)
Estriol group (n = 25)					
Maturation value	22.5 ± 7.1	26.8 ± 7.1* (P < 0.001)	32.6 ± 13.9* (P < 0.001)	24.7 ± 13.2	25 ± 6.37* (P < 0.05)
pH value	4.9 ± 0.6	/	4.5 ± 0.7* (P < 0.01)	/	4.9 ± 0.6

Results for the maturation value were measured before and after 1, 3, 6, and 12 months, and for the pH value before and after 3 and 12 months. The values present mean ± standard deviation. Statistical significance was determined using student's t-test. P values < 0.05 were considered statistically significant. Bold values represent statistically significant values as compared to values before treatment. *indicates statistically significant improvement.

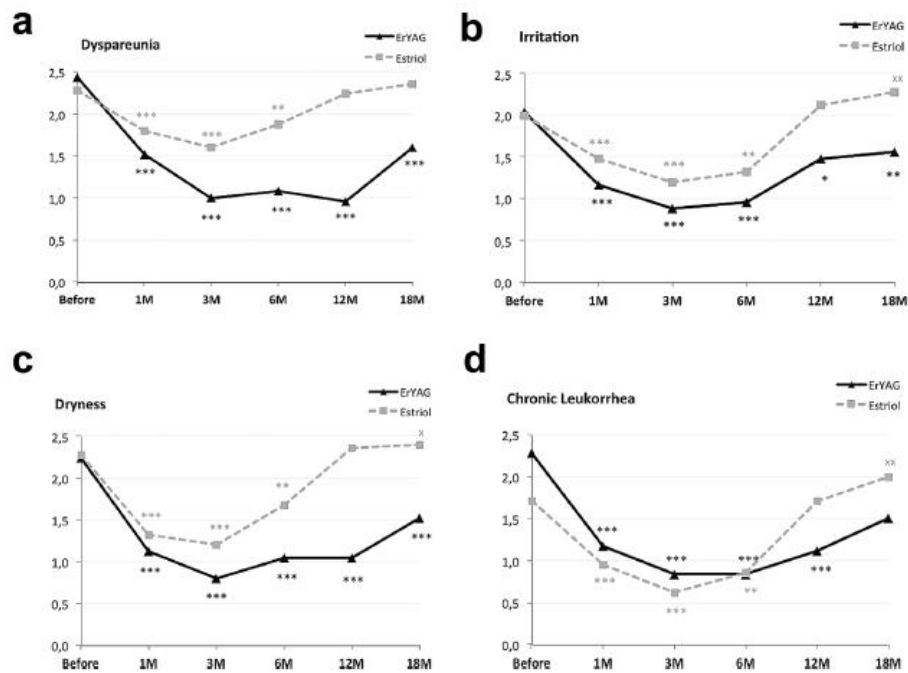


Fig. 1. Assessment of the following symptoms of GSM: (a) dyspareunia, (b) irritation, (c) dryness, (d) chronic leukorrhea—on a 0–3 VAS scale in the laser group and in the estriol group before the treatment and after 1, 3, 6, 12, and 18 months. *Indicates level of statistically significant improvement—***P < 0.001; **P < 0.01; *P < 0.05; x denotes statistically significant worsening -xx - P < 0.01; x - P < 0.05.

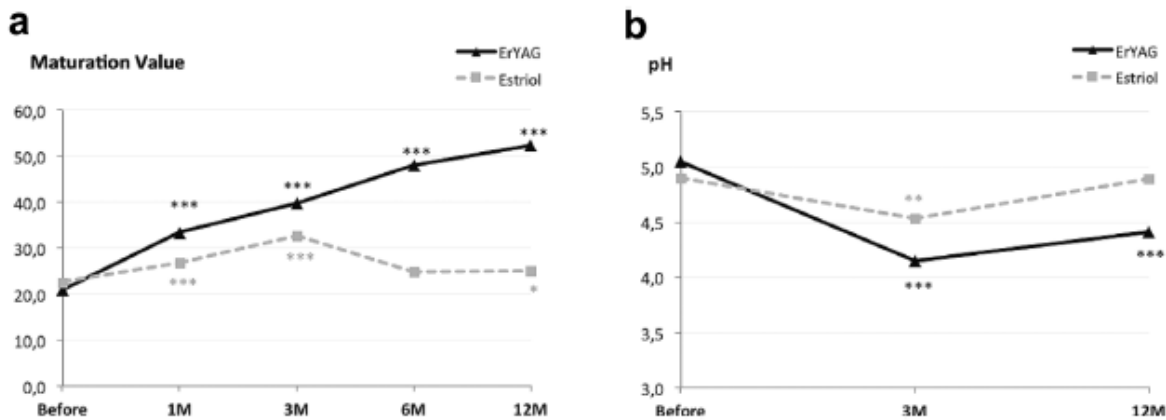


Fig. 2. (a) Maturation value before and at 1, 3, 6, and 12 months post treatment, and (b) pH before and at 3 and 12 months follow-up. *Indicates level of statistical significance—*** $P < 0.001$; ** $P < 0.01$; * $P < 0.05$.

Discussion

The primary goal of GSM treatment is to restore normal physiological conditions and thus to relieve GSM symptoms.

Our results have shown that novel Er:YAG laser therapy is more efficient and longer lasting than topical estriol treatment, which has shown transient relief of symptoms that started to diminish after the treatment stopped. In this study, we aimed at comparing the effect of a novel treatment to topical estriol treatment in terms of the durability of the effect after treatment has been stopped. For this purpose, an equal duration of treatment regimen has been chosen as the most appropriate, that is, laser treatment over 8 weeks compared to 8 week of estriol. Vaginal mucosa has several functions: absorption, secretion, protection, and response to stimuli. These four functions directly depend on the integrity and normal function and morphology of the mucosa, which also depends on estrogen levels [18]. Physiological changes in GSM are the results of aging and diminished estrogen concentrations during menopause. These changes present histologically as changes in vaginal wall structures— thinning and decreased thickness of the epithelium, and clinically as dryness, increased pH, painful intercourse, irritation of the vulva with burning and itching, paleness of tissue, and loss of elasticity. Improvement in the symptoms of GSM can be achieved either by increasing the local estrogen levels or the blood flow in the affected area [6].

It is well known that therapy with local estrogen in the form of estradiol, estriol or conjugated estrogens, restores vaginal pH and increases the thickness of the epithelium, and vaginal secretions [1]. Recently, it has been shown that local estrogens are also able to induce collagen synthesis and reorganization in animal models as well as clinically [19,20]. However, to the best of our knowledge local estrogen therapy does not seem to have a significant effect on angiogenesis. In the present study, estriol was used as a comparison to laser therapy. Estriol is a lower-potency estrogen that has recently been shown to improve symptoms of GSM [21]. Local estrogen preparations affect mostly the surface of the vaginal mucosa and the improvement is transient— lasting only as long as the therapy is administered [6]. In contrast, Er:YAG laser therapy with non-ablative SMOOTH mode acts by producing pulse sequences of low fluence pulses that are absorbed at the tissue surface and cause transient heat increase of the mucosa, inducing restructuring of the lamina propria, but also microvascularization and new vessel formation. This tissue response on mild heat pulsing has been confirmed in prior studies [10,22,23]. The consequence of this mechanism of action is long term improvement of GSM symptoms. The histology of the inspected samples prior to the treatment showed typical consequences of lack of estrogen, which also resulted with macroscopic findings, such as diminished humidity, rugation, elasticity, lubrication, and secretions [1]. In histological samples taken from patients in the laser group at 1, 3, 6, and 12 months after the treatment, an improvement was observed in terms of basal cell hyperplasia, parakeratosis, and papillomatosis. Changes in the lamina propria included an initial vasodilation effect and an increase in the cellularity of the extracellular matrix with papillomatosis. Changes in the lamina propria could explain the immediate restorative reaction that the heat has on the mucosal tissue: the improvement in vascularization could result in an increase in oxygen and nutrients supply to the treated area thus favoring a restorative process.

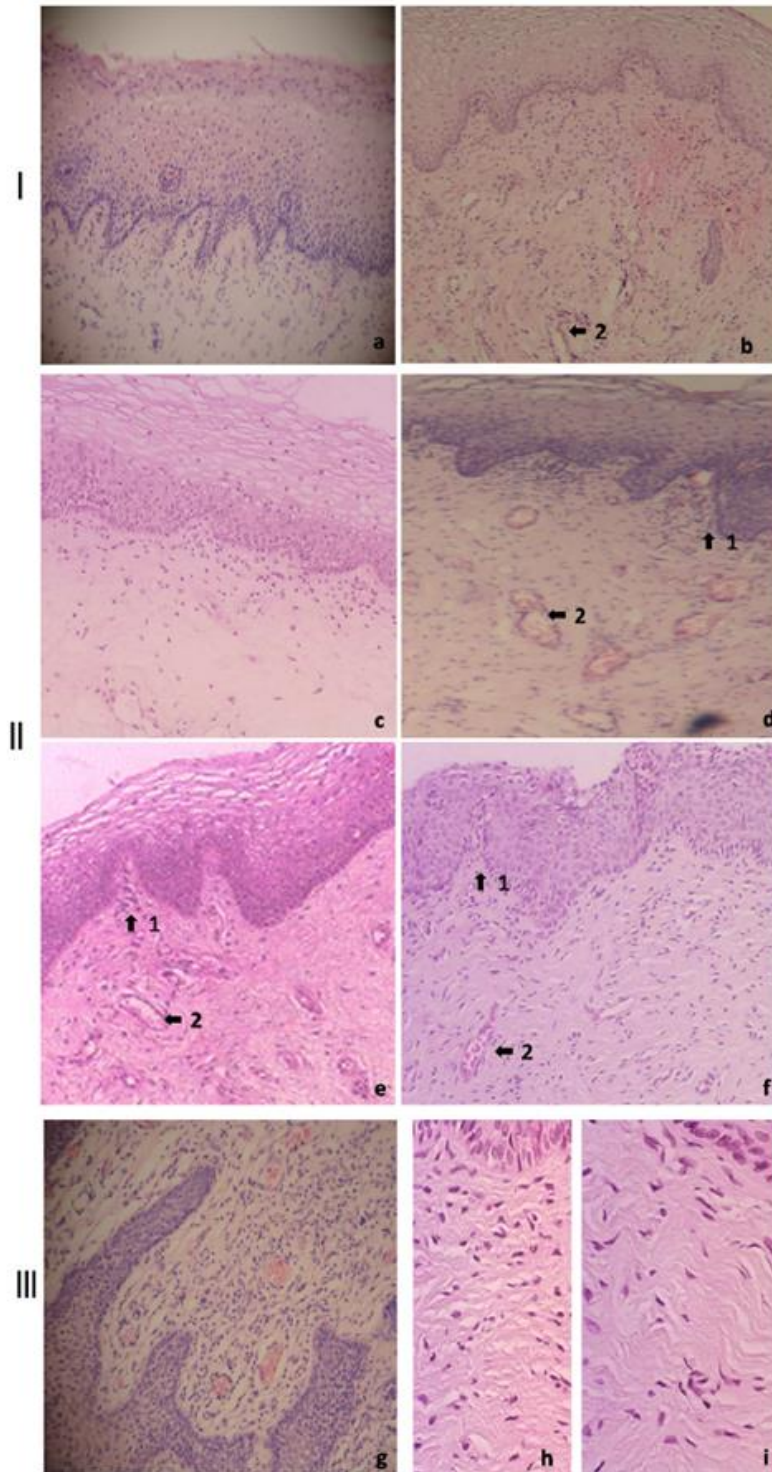


Fig. 3. Histological examination (hematoxylin-eosin staining) of the vaginal mucosa of patients with GSM symptoms before and after Er:YAG laser treatment. Panel I shows images before treatment (a) and 1 month after laser treatment (b). New vessel formation can be observed (2). Panel II shows images before treatment (c) and 3, 6, and 12 months after laser treatment (d–f, respectively). Increased cellularity and neo-angiogenesis can be observed (2) after Er:YAG laser treatment, increase in papillomatosis (1), basal cells hyperplasia, and a complete restorative reaction at the level of the lamina propria. Panel III shows images at 6 months after laser treatment, displaying increased angiogenesis (g) and restorative reaction at the level of the extracellular matrix (h and i). Photomicrographs at 4× (a–g) and 10× (h and i) magnification are presented.

The MV, which indicates the degree of maturation attained by the vaginal epithelium and serves as an objective means of evaluating hormonal response [17] and atrophy, was significantly increased in the laser group even after having completed the laser therapy, indicating the long-term effect of laser regeneration. In contrast, the effect in the estriol group was less pronounced and has shown a trend of decrease after the end of the hormonal treatment [6]. It can be speculated that histological changes seen in the laser group ultimately result with an improvement in the assessed symptoms of GSM (irritation, dyspareunia, dryness, and chronic leukorrhea). Assessing the symptoms of dyspareunia, dryness, irritation, and chronic leukorrhea, as well as the MV and pH, there was greater reduction of symptoms and greater improvement in the MV and pH in the laser group as compared to the estriol-only group. It is important to highlight that improvements in the estriol group were observed during the time that the therapy was administered and remained significantly improved up to the 6 month follow-up (4 months after therapy was stopped), while in the laser group they were sustained after the laser treatment was concluded, up to 18 months after 1st treatment (and 16 months after therapy was stopped), showing a much longer lasting effect in comparison to estriol. The effects of estriol on the symptoms of GSM showed improvement up to the 6-month follow up, with results diminishing to the level before treatment at the 12-month follow up, and some even showing significantly worse symptoms at the 18-month follow-up compared to baseline. This transient effect of estriol has also been reported in previous studies [6].

The pH value decreased in both groups, the effect of the laser being more pronounced. It can be hypothesized that the decrease is due to an increase in superficial cells (evidenced by an increased MV) and the thickness in the epithelium and consequently glycogen production. Glycogen in the mucous layer serves as a substrate for vaginal colonization by Doderlein's lactobacillus which produce lactic acid which in turn regulates the low vaginal pH [24]. The effect of laser treatment on GSM symptoms has been previously described only in a few studies. In one of the studies by Gaspar et al. [25], a fractional CO₂ laser was used for the treatment of vaginal rejuvenation. It showed beneficial effects in the three layers of the vaginal tissue and in sexual function. A study by Salvatore et al. [26], has shown in a 3-month follow-up study that treatment with a fractional CO₂ laser improves symptoms of GSM. Histological analysis of vaginal tissue at 1 and 2 months after treatment revealed thicker epithelium with increased glycogenic store, papillae formation, and increased content of blood vessel in the connective tissue, all suggestive of a metabolic reactivation of the connective components of the vaginal mucosa [27]. Similar histological changes were observed in biopsies taken up to 12 months post treatment in our study. However, the major difference between CO₂ laser and the Er:YAG laser method used in the present study is in the ablative characteristics of the CO₂ laser, which works by vaporizing columns of tissue. Tissue vaporization of epithelial layer surface is necessary to expose deeper, underlying connective tissue, which is more abundant in water, to the thermal effects of the CO₂ laser pulse [27] for achieving the desired photobiomodulatory effect. In contrast, Er:YAG laser with SMOOTH mode creates heat pulses without damaging the mucosa. The temporal distribution of energy delivered with the special 166 GASPARET AL. SMOOTH mode allows the heat to slowly dissipate to depths of approximately 200 mm [10], thus achieving the same biological effects than the thermal effects of a CO₂ laser pulse, with the additional benefit of avoiding mucosal damage. Consequently, the risk of infection, necrosis, scarring, and other side effects is minimized compared to CO₂. The beneficial effects of non-ablative Er:YAG laser treatments in gynecology were previously described by Ogrinc et al. [15] and Gambacciani et al. [16].

In a study by Ogrinc et al. [15], the results confirmed that a minimally invasive, non-ablative laser treatment is an effective, safe, and comfortable treatment alternative with at least 1 year lasting positive effects in patients with stress urinary incontinence. A positive effect on the symptoms of stress urinary incontinence was ascribed to neocollagenesis and collagen remodeling in the vaginal wall. In the study, a special sub-ablative sequence of laser pulses was used to achieve an optimal temperature to stimulate collagen tightening and new collagen formation in the vaginal connective tissue. A similar pulsing sequence, which delivers laser energy in a non-ablative mode (SMOOTH mode), was used in our case to achieve moderate homogeneous heating within a several hundred micron thick superficial layer, without any ablation and with a controlled temperature deposition [28]. Gambacciani et al. [16], have recently published a study where the same type of laser—Er:YAG with SMOOTH mode, was used for the treatment of GSM. The study reported significant improvement of GSM symptoms, which lasted up to 6 months post-treatment. The treatment was equally or more effective than local estriol gel. In the present study, we show that the results are reproducible and can be sustained up to 18 months after treatment. Based on examination of vaginal wall histology before and after treatment the effects of non-ablative Er:YAG laser treatment can be suggested. The positive effect on the epithelium and lamina propria is presumably due to the stimulation of cell proliferation via heat shock protein activation, an increase of collagen production as well as anti-inflammatory action [29–31]. It is also very important to acknowledge that laser therapy has most probably a different mechanism of action than estriol, resulting in induced vessel formation, reconstitution of the lamina propria, and consequent regeneration of the mucosa lasting for an extended period of time even after therapy has been ceased. Having all the above considerations in mind, we believe that

the Er:YAG laser treatment in combination with a low-dose/short-term estriol mucosa preparation phase could be considered a preferred treatment with respect to effectiveness and safety. In patients that cannot receive estrogen therapy due to previous or existing estrogen responsive cancers, mucosa could be prepared differently (i.e., using platelet-rich plasma or just by using moisturizing gel during the treatment), making the laser treatment a completely estrogen-free, non-invasive option for the treatment of GSM symptoms.

The safety profile of the treatment has also been shown to be favorable, consisting of only mild and transient side effects of local nature. It has to be emphasized, that a long-term safety profile has not yet been established; however, based on the transient nature of the observed side effects and considering the mode of action of Er:YAG laser treatment, no long-term safety issues are to be expected. In conclusion, the major benefit of the laser treatment in comparison to the 8-week local estriol treatment is that the laser treatment produces a long lasting effect characterized by an improved vascularization and increased extracellular matrix component, while estriol-only treatment increases the glycogen level in the vaginal epithelium and its turnover [1], with less effect and only transient effect on vascularization and changes in the lamina propria, requiring maintenance treatment for the effects to be sustained. Due to these enhanced effects, the laser treatment provides great improvement in the signs and symptoms of GSM, which remains evident also after the treatment is concluded. We have observed a trend of diminishing effect at the 18-month follow-up, although the improvement was still highly significant. Since the treatment is safe and noninvasive, it could be repeated once the patients feel the return of symptoms, and in that way sustain the beneficial mucosal state. Although, this is a pilot study and longer follow-ups with greater numbers of patients would be needed to better determine the effectiveness and long-term safety of this new treatment option, our results indicate that Er:YAG laser promises to be an efficient and safe treatment alternative for GSM.

References

1. Management of symptomatic vulvovaginal atrophy: 2013 position statement of the north american menopause society. *Menopause* 2013;20(9):888–902; quiz 903–904.
2. Santoro N, Komi J. Prevalence and impact of vaginal symptoms among postmenopausal women. *J Sex Med* 2009; 6(8):2133–2142.
3. Bachmann GA, Nevadunsky NS. Diagnosis and treatment of atrophic vaginitis. *AmFamPhysician* 2000;61(10):3090–3096.
4. Portman DJ, Gass ML. Genitourinary syndrome of menopause: New terminology for vulvovaginal atrophy from the International Society for the Study of Women's Sexual Health and the North American Menopause Society. *Vulvovaginal Atrophy Terminology Consensus Conference Panel. Menopause* 2014;21(10):1063–1068.
5. Iosif CS, Bekassy Z. Prevalence of genito-urinary symptoms in the late menopause. *Acta Obstet Gynecol Scand* 1984;63(3): 257–260.
6. Johnston SL, Farrell SA, Bouchard C, Farrell SA, Beckerson LA, Comeau M, Johnston SL, Lefebvre G, Papaioannou A; SOGC Joint Committee-Clinical Practice Gynaecology and Urogynaecology. The detection and management of vaginal atrophy. *J Obstet Gynaecol Can* 2004;26(5):503–508.
7. Von Schoultz E, Rutqvist LE. Menopausal hormone therapy after breast cancer: The Stockholm randomized trial. *J Natl Cancer Inst* 2005;97(7):533–535.
8. Suckling J, Lethaby A, Kennedy R. Local oestrogen for vaginal atrophy in postmenopausal women. *Cochrane database Syst Rev* 2006;(4):CD001500.
9. Cardozo L, Bachmann G, McClish D, Fonda D, Birgerson L. Meta-analysis of estrogen therapy in the management of urogenital atrophy in postmenopausal women: Second report of the Hormones and Urogenital Therapy Committee. *Obstet Gynecol* 1998;92(4 Pt 2):722–727. EFFICACY OF ERBIUM:YAG LASER TREATMENT OF GSM 167
10. Drnovsek-Olup B, Beltram M, Pizem J. Repetitive Er:YAG laser irradiation of human skin: A histological evaluation. *Lasers Surg Med* 2004;35(2):146–151.
11. Kunzi-Rapp K, Dierickx CC, Cambier B, Drosner M. Minimally invasive skin rejuvenation with erbium: YAG laser used in thermal mode. *Lasers Surg Med* 2006;38: 899–907.
12. Bodendorf MO, Willenberg A, Anderegg U, Grunewald S, Simon JC, Paasch U. Connective tissue response to fractionated thermo-ablative Erbium:YAG skin laser treatment. *Int J Cosmet Sci* 2010;32(6):435–445.
13. Salvatore S, Leone Roberti Maggiore U, Athanasiou S, Origoni M, Candiani M, Calligaro A, Zerbini N. Histological study on the effects of microablative fractional CO2 laser on atrophic vaginal tissue: An ex vivo study. *Menopause* 2015; 22(8):845–849.
14. Berlin AL, Hussain M, Phelps R, Goldberg DJ. A prospective study of fractional scanned nonsequential carbon dioxide laser resurfacing: A clinical and histopathologic evaluation. *Dermatol Surg* 2009;35(2):222–228.
15. Ogrinc UB, Sencar S, Lenasi H. Novel minimally invasive laser treatment of urinary incontinence in women. *Lasers Surg Med* 2015;47:689–697.
16. Gambacciani M, Levancini M, Cervigni M. Vaginal erbium laser: The second-generation thermotherapy for the genitourinary syndrome of menopause. *Climacteric* 2015;18:757–763.
17. Meisels A. The maturation value. *Acta Cytol* 1967;11(4):249.
18. Mac Bride MB, Rhodes DJ, Shuster LT. Vulvovaginal atrophy. *Mayo Clin Proc* 2010;85(1):87–94.
19. Rahn DD, Good MM, Roshanravan SM, Shi H, Schaffer JI, Singh RJ, Word RA. Effects of preoperative local estrogen in postmenopausal women with prolapse: A randomized trial. *J Clin Endocrinol Metab* 2014;99(10):3728–3736.
20. Montoya TI, Maldonado PA, Acevedo JF, Word RA. Effect of vaginal or systemic estrogen on dynamics of collagen assembly in the rat vaginal wall. *Biol Reprod* Feb 2015; 92(2):43.
21. Cano A, Estevez J, Usandizaga R, Gallo JL, Guinot M, Delgado JL, Castellanos E, Moral E, Nieto C, del Prado JM, Ferrer J. The therapeutic effect of a new ultra low concentration estriol gel formulation (0.005% estriol vaginal gel) on symptoms and signs of postmenopausal vaginal atrophy: Results from a pivotal phase III study. *Menopause* 2012;19(10):1130–1139.
22. Dams SD, de Liefde-van Beest M, Nuijs AM, Oomens CWJ, Baaijens FPT. Heat shocks enhance procollagen type I and III expression in fibroblasts in ex vivo human skin. *Skin Res Technol* 2011;17(2):167–180.
23. Romanos GE, Gladkova ND, Feldchtein FI, Karabut MM, Kiseleva EB, Snopova LB, Fomina YV. Oral mucosa response to laser patterned microcoagulation (LPM) treatment. An animal study. *Lasers Med Sci* 2013;28(1):25–31.
24. Sturdee DW, Panay N. Recommendations for the management of postmenopausal vaginal atrophy. *Climacteric* 2010; 13(6):509–522.
25. Gaspar A, Addamo G, Brandi H. Vaginal fractionalCO2 laser: A minimally invasive option for vaginal rejuvenation. *Am J Cosmet Surg* 2011;28(3):156–162.
26. Salvatore S, Nappi RE, Zerbini N, et al. A 12-week treatment with fractional CO2 laser for vulvovaginal atrophy: A pilot study. *Climacteric* 2014;17(4):363–369.
27. Zerbini N, Serati M, Origoni M, Candiani M, Iannitti T, Salvatore S, Marotta F, Calligaro A. Microscopic and ultrastructural modifications of postmenopausal atrophic vaginal mucosa after fractional carbon dioxide laser treatment. *Lasers Med Sci* 2015;30(1):429–436.
28. Vizintin Z, Rivera M, Fistonc I, Saracoglu F, Guimares P, Gaviria J, Garcia V, Lukac M, Perhavec T, Marini L. Novel minimally invasive VSP Er:YAG laser treatments in gynecology. *J Laser Health Acad* 2012;1:46–58.
29. Thomsen S. Pathologic analysis of photothermal and photomechanical effects of laser-tissue interactions. *Photochem Photobiol* 1991;53(6):825–835.
30. Melo de VA, Anjos dos DCS, Albuquerque Junior R, Melo DB, Carvalho FUR. Effect of low level laser on sutured wound healing in rats. *Acta Cir Bras* 2011;26(2):129–134.
31. Kao B, Kelly KM, Majaron B, Nelson JS. Novel model for evaluation of epidermal preservation and dermal collagen remodeling following photorejuvenation of human skin. *Lasers Surg Med* 2003;32(2):115–119.

Treatment of the genitourinary syndrome of menopause

(2015) *Climacteric*, 18:sup1, 23-29

S. Palacios, A. Mejía & J. L. Neyro

Abstract

The vagina, vulva, vestibule, labia majora/minora, and bladder trigone have a high concentration of estrogen receptors; therefore, they are a sensitive biological indicator of serum levels of these hormones in women.

The estrogen loss in postmenopausal women produces a dysfunction called genitourinary syndrome of menopause. The principal therapeutic goal in the genitourinary syndrome of menopause is to relieve symptoms. Treatment options, as well as local and systemic hormonal treatment are changes in lifestyle and non-hormonal treatments mainly based on the use of moisturizers and lubricants. New treatments that have recently appeared are ospemifeme, the first selective hormone receptor modulator for dyspareunia and vulvovaginal atrophy treatment, and the use of vaginal laser. This review has been written with the intention of giving recommendations on the prevention and treatment of genitourinary syndrome of menopause.

Laser therapy for the restoration of vaginal function

Maturitas <http://dx.doi.org/10.1016/j.maturitas.2017.01.012>

Marco Gambacciani^{a*}, Santiago Palacios^b

^aDepartment of Obstetrics and Gynaecology, Pisa University Hospital, Pisa (Italy)

^bPalacios Institute of Women's Health, Madrid (Spain)

*Corresponding Author: Marco Gambacciani MD, Department of Obstetrics and Gynaecology, Pisa University Hospital

Abstract

Laser therapy has a therapeutic role in various medical conditions and most recently has gained interest as a non-hormonal treatment for genitourinary syndrome of menopause (GSM) and as a non-invasive option for stress urinary incontinence (SUI). Several therapies are available to alleviate GSM symptoms, including hormonal and non-hormonal products. Both microablative fractional CO₂ laser and the non-ablative vaginal Er:YAG laser (VEL) induce morphological changes in the vaginal tissues, and data from non-randomized clinical trials suggest that laser therapy can alleviate vaginal dryness and dyspareunia. VEL has been reported to improve SUI as well as vaginal prolapse. Although large randomized trials have not been reported, the evidence suggests that VEL can be offered as a safe and efficacious alternative to hormone replacement therapy (HRT) for GSM, as well as a first-line treatment for mild to moderate SUI, before surgical procedures are resorted to. Randomized studies are needed to compare laser treatments with other therapies, as well as to assess the duration of the therapeutic effects and the safety of repeated applications. Research is presently evaluating both an automated robotic probe for VEL treatments and an intraurethral probe for the treatment of severe and type III SUI.

Keywords

genitourinary syndrome of menopause, urinary incontinence, pelvic organ prolapse, vaginal relaxation syndrome, vaginal laser therapy

Genitourinary syndrome of menopause: an overview of clinical manifestations, pathophysiology, etiology, evaluation, and management

Am J Obstet Gynecol. Dec;215(6):704-711

Jason Gandhi, MS; Andrew Chen, BA; Gautam Dagur, MS; Yiji Suh; Noel Smith, MD; Brianna Cali, BS; Sardar Ali Khan, MD

Abstract

Genitourinary syndrome of menopause, a new term for a condition more renowned as atrophic vaginitis, is a hypoestrogenic condition with external genital, urological, and sexual implications that affects >50% of postmenopausal women. Due to sexual embarrassment and the sensitive nature of discussing symptoms, genitourinary syndrome of menopause is greatly underdiagnosed. The most up-to-date literature pertaining to clinical manifestations, pathophysiology, etiology, evaluation, and management of genitourinary syndrome of menopause is comprehensively reviewed. Early detection and individually tailored pharmacologic (eg, estrogen therapy, selective estrogen receptor modulator, synthetic steroid, oxytocin, and dehydroepiandrosterone) and/or nonpharmacologic (eg, laser therapies, moisturizers and lubricants, homeopathic remedies, and lifestyle modifications) treatment is paramount for not only improving quality of life but also for preventing exacerbation of symptoms in women with this condition.

Key words: atrophic vaginitis, dyspareunia, estrogen-progestin therapy, genitourinary syndrome of menopause, hypoestrogenism, menopausal hormone therapy, nonhormonal vaginal therapy, quality of life, urinary incontinence, urogenital atrophy, vaginal maturation index, vulvovaginal atrophy.

Introduction:

Genitourinary syndrome of menopause(GSM), previously known as vulvovaginalatrophy, atrophic vaginitis, or urogenitalatrophy, is a chronic, progressive vulvovaginal, sexual, and lower urinarytract condition characterized by a host of symptoms secondary to a clinical state of hypoestrogenism after onset of menopause.

In 2014, the International Society for the Study of Women's Sexual Health and the North American Menopause Society agreed that "genitourinary syndrome of menopause" is a more inclusive and accurate term to describe the conglomeration of external genital, urological, and sexual sequelae caused by hypoestrogenism during menopause.¹ They also agreed the new terminology would carry less social stigma thus making it easier for women to openly talk about it, especially to their care providers. GSM-like symptoms may also be mirrored in hypoestrogenic premenopausal women. The syndrome or its features manifest in some manner in approximately 15% of premenopausal women² and 40-54% of postmenopausal women.³ Because women have a higher life expectancy than men, and approximately >17% of the population will be age >65 years by 2030, the consequences of declined endogenous estrogen levels in menopausal women should be of great interest to clinicians.⁴ GSM is often underdiagnosed due to sexual embarrassment⁵ or general disregard due to associating it as a liability of natural aging. In a recent study, only 4% of women were able to attribute vulvovaginal symptoms to GSM.⁶ Only around 25% of womenwith GSM go to a practitioner for consultation.² Another European study found that only 54% of women discuss their sexual health with practitioners when asked, and 33% of women do not discuss it at all.⁷ Identifying postmenopausal women's profiles (eg, their tendency to be proactive or reserved) may help bypass the social taboo on discussing GSM, thus expediting evaluation and management.⁸ In cases of abrupt estrogen deprivation, eg, surgical menopause, patients can experience significant sexual dysfunction and even poorer quality-of-life outcomes. We presently explore the signs, symptoms, and genitourinary manifestations of GSM; the importance of its early detection; as well as the crucial role of proper patient education in avoiding the long-term risks and complications that may severely compromise quality of life. Management of GSM must ideally be tailored to individual patient medical history, potential risks and benefits of exogenously administered estrogen therapy (ET), as well as patient lifestyle.

Clinical manifestations: Clinicians play a major role in recognizing the signs of GSM because many women are reluctant to report their symptoms due to personal reasons. Additionally, 50% of postmenopausal women with mild or moderate GSM are asymptomatic, making diagnosis particularly challenging. Only a weak correlation has been found between symptom score and physical examination of GSM.⁹ Manifestations of GSM are primarily divided into external genital and urological signs and symptoms (Table 1), which can be observed through physical examination.¹ Genitourinary complications experienced secondary to GSM are included in Table 1 to further guide clinicians and health care providers. There may be a linking of certain signs and complications, eg, vaginal vault prolapse and urinary incontinence. Introital stenosis to a width <2 fingers, decreased vaginal depth, and vaginal dryness must be diagnosed before insertion of the speculum, otherwise the pelvic examination will cause considerable pain. Vaginoscopy is an alternative if the practitioner is unable to perform a pelvic/vaginal examination. GSM is most commonly diagnosed when the patient presents with dyspareunia secondary to vaginal dryness. Common signs and symptoms in order of prevalence and degree of atrophy include vaginal dryness (in 75% postmenopausal women), dyspareunia (38%) and vaginal itching, discharge, and pain (15%).^{10,11} When the vulvovaginal epithelium is inadequately lubricated, ulceration and fissures can develop during intercourse, causing dyspareunia. Vaginismus, or painful spasm of vaginal muscles, can also occur as a physiological response when there is anxiety toward expected sexual pain. Sexual manifestations are an extension of those of the external genitalia (Table 1).

Pathophysiology: During female embryologic development, the urogenital sinus, müllerian ducts, and sinovaginal node (ie, Müller tubercle) form the vaginal vestibule and lower fifth of vagina, urinary bladder, trigone, and the entire urethra. Fused müllerian ducts form the uterus and upper four-fifths of the vagina. The genitalia and lower urinary tract share common estrogen receptor function. Due to the common embryological origin, hypoestrogenism has both vulvovaginal and urologic effects; urogenital tissue receptors are dependent on endogenous estrogen levels to maintain normal physiology.¹² During postmenopause, the number of estrogen receptors continue to decrease but never fully disappear. However, in the presence of exogenous administration of estrogen, one can replenish lost estrogen receptors.² In the vulvovaginal tissue, estrogen receptor- α is predominantly present in premenopausal and postmenopausal women, whereas estrogen- β appears to only be expressed in premenopausal women.¹³ Estrogen is a vasoactive hormone that increases blood flow.¹¹ Vaginal lubrication is caused by fluid transudation from blood vessels, and from endocervical and Bartholin glands. Activated estrogen receptors also encourage epithelial proliferation with redundant smooth muscle tissue layer. The formation of rugae aids in expandability, distensibility, and lubrication of the vagina during sexual stimulation. Vaginal secretions, lubrication, and improved blood flow of vaginal walls all help to increase vaginal mechanical

TABLE 1

External genital, urological, and sexual manifestations of genitourinary syndrome of menopause

External genital		Urological		Sexual
Signs and symptoms	Complications	Signs and symptoms	Complications	Signs and symptoms
Vaginal/pelvic pain and pressure	Labial atrophy	Frequency	Ischemia of vesical trigone	Loss of libido
Dryness	Vulvar atrophy and lesions	Urgency	Meatal stenosis	Loss of arousal
Irritation/burning	Atrophy of Bartholin glands	Postvoid dribbling	Cystocele and rectocele	Lack of lubrication
Tenderness	Intravaginal retraction of urethra	Nocturia	Urethral prolapse	Dyspareunia
Pruritus vulvae	Alkaline pH (5–7)	Stress/urgency incontinence	Urethral atrophy	Dysorgasmia
Decreased turgor and elasticity	Reduced vaginal and cervical secretions	Dysuria	Retraction of urethral meatus inside vagina associated with vaginal voiding	Pelvic pain
Suprapubic pain	Pelvic organ prolapse	Hematuria	Uterine prolapse	Bleeding or spotting during intercourse
Leukorrhea	Vaginal vault prolapse	Recurrent urinary tract infection	Urethral polyp or caruncle	
Ecchymosis	Vaginal stenosis and shortening			
Erythema	Introital stenosis			
Thinning/graying pubic hair				
Thinning/pallor of vaginal epithelium				
Pale vaginal mucous membrane				
Fusion of labia minora				
Labial shrinking				
Leukoplakic patches on vaginal mucosa				
Presence of petechiae				
Fewer vaginal rugae				
Increased vaginal friability				

Gandhi. Genitourinary syndrome of menopause. Am J Obstet Gynecol 2016.

TABLE 2
Causes of estrogen deficiency in premenopausal women or due to factors unrelated to menopause

Type	Cause
Systemic	Hyperprolactinemia (during breast-feeding) Postpartum estrogen deficiency Hypoestrogenism (eg, due to autoimmune disorders affecting ovaries, pituitary tumors)
Pharmacological	Gonadotropin-releasing hormone agonist analogs Leuprolide Nafarelin Selective estrogen receptor modulators Tamoxifen Aromatase inhibitors Danazol Medroxyprogesterone
Iatrogenic	Bilateral oophorectomy (ie, surgical menopause) Ovarian failure secondary to pelvic radiation Chemotherapy Radiation therapy

Gandhi. Genitourinary syndrome of menopause. Am J Obstet Gynecol 2016.

compliance.² In the advent of hypoestrogenism, these prolubricative and proelastic functions are lost due to diminished collagen, elastin, and hyaluronic acid content; thinned epithelium; impaired smooth muscle proliferation; denser connective tissue arrangement; and loss of vascularity, thus predisposing the woman to irritation and sexual trauma.¹⁴ The vaginal and urethral epithelium is comprised of nonkeratinized stratified squamous epithelium with superficial, intermediate, and basal cell layers that store glycogen in the presence of physiologic estrogen levels. The epithelium of the vaginal wall is constantly exfoliating and producing glycogen, which is hydrolyzed to glucose. A healthy vaginal flora is composed of a variety of aerobic and anaerobic, gram-positive and gramnegative bacteria. Predominant *Lactobacillus* metabolizes

glucose into lactic acid and acetic acid, lowering the vaginal pH to a range of 3.5-4.5. The acidity of the vagina provides natural protection against urinary tract infections (UTI) and vaginitis, discouraging the growth of pathogenic bacteria and infection.¹¹ Estrogen is vital for modulating innate defenses of the urinary tract. Thus, knowledge of the association between GSM and recurrent UTI can help avoid unnecessary use of antibiotics and prevent antimicrobial resistance.¹⁵ Atrophy of urogenital tissue is identified

with declined endogenous estrogen levels with vaginal epithelium appearing thin, pale, and less rugated. The loss of estrogen is responsible for the reduction of *Lactobacillus*, changing the vaginal fluid to an alkaline pH of 5.0. The higher pH impairs the viability of healthy vaginal flora⁵ and promotes overgrowth of gramnegative rod fecal flora including group B streptococci, staphylococci, coliforms, and diphtheroids, inducing vaginal infection and UTI and inflammation.¹⁶ In decreased levels of circulating estrogen, substantial vascularization is lost in the urogenital tract, making the tissue atrophic. Estrogen deficiency causes loss in dermal collagen in dense connective tissue of the vagina, bladder, and urethra, and then causes the vaginal wall to become thinner and less elastic. In consequence, the vagina becomes shortened and narrowed, which may lead to dyspareunia. The bladder and urethra also become atrophic, causing urinary incontinence and frequency.^{2,11} One study reported that 20% of postmenopausal women experienced urge incontinence while roughly 50% experienced stress urinary incontinence.¹⁷ It is thought that estrogen receptors in the bladder trigone and urethra aid in increasing the sensory threshold when the bladder becomes distended. Lack of estrogen decreases the threshold and impairs urethral closure pressure and Valsalva leak-point pressure, contributing to urinary urgency.¹⁷ Research studies have also suggested that in postmenopausal women, the lack of estrogen impairs connective tissue and causes urethral sphincter dysfunction of stress urinary incontinence. In comparison, premenopausal women experience stress incontinence mainly due to anatomical changes.¹⁸ GSM-related incontinence is a key cause of recurrent UTI in postmenopausal women, signifying the importance of GSM evaluation and management to avoid the repercussions of inessential antibiotic therapy.¹⁵

TABLE 3
Risk factors for genitourinary syndrome of menopause

Menopause
Nonmenopause hypoestrogenism
Bilateral oophorectomy
Cigarette smoking
Alcohol abuse
Decreased frequency and sexual abstinence
Ovarian failure
Lack of exercise
Absence of vaginal childbirth

Gandhi. Genitourinary syndrome of menopause. Am J Obstet Gynecol 2016.

Etiology: The etiology of GSM is secondary to decreased levels of endogenous estrogen levels. In the female body, the 3 forms of estrogen produced mainly in the ovaries are estradiol, estrone, and estriol with estradiol being the most abundant in premenopausal women. During the transition between perimenopausal and postmenopausal years, estrone becomes the most prominent and is a less potent form of estrogen.¹⁹ Table 2 outlines nonmenopausal related causes of estrogen deficiency that may mimic GSM sequelae,^{12,16} such as the hormonal therapies and chemotherapy from treating women with breast cancer. Table 3 lists risk factors for developing GSM such as cigarette smoking, which contributes to decreased

circulation and impaired receptor function.^{5,12} Table 4 distinguishes between development of superficial and deep dyspareunia.^{20,21}

Evaluation: A full history should be performed on patients suspected to have GSM. Lubricants, powders, soaps, spermicides, and panty liners commonly contain irritants that could produce discomfort to the genitourinary region. Antiestrogen medications or a history of oophorectomy, radiation, or chemotherapy increases suspicion of GSM-like symptomatology particularly in premenopausal women. The cornerstone of evaluating menopausal women with sexual health symptoms is the pelvic examination. Atrophic vaginal epithelium appears pale and shiny, and patches of erythema may be present. One should check for any signs of lacerations or lesions, labial fusion, introital stenosis, and friable epithelium. Table 5 catalogs findings of cystoscopic and laparoscopic procedures. Differential diagnoses that should be evaluated when a woman is thought to present with GSM include bacterial vaginosis, trichomoniasis, candidiasis, contact irritants, foreign bodies, and sexual trauma. Other diagnoses to consider include neoplasia and precancerous neoplasia of external or internal female genitalia, endocrine disorders, infections from body piercing, vaginal stenosis secondary to radiation, lichen sclerosus, and lichen planus.¹² To aid in the diagnosis of GSM, several laboratory tests are useful. Cytology of the vaginal epithelium shows an increase in parabasal cells and a decrease in superficial cells. Ultrasound examination of the uterus is especially useful as a thin endometrial thickness of <5 mm indicates decreased estrogen stimulation. Vaginal pH, Pap test, and vaginal culture are also useful in assessing for genitourinary infection. Table 6 lists the diagnostic tests to perform after the initial clinical assessment.

Management: Management of GSM varies according to symptom severity. For moderate to severe symptoms, ET is reported to be the most successful treatment option in terms of increasing the vaginal maturation index (VMI). For milder symptoms, though nonhormonal therapies are subjectively effective, they are suitable for women at risk for estrogenresponsive neoplasia, and do not require prescriptions.^{22,23} To assess the effectiveness of treatment, a pH test and cytologic analysis may be utilized. Since GSM is a chronic condition, life-long management is essential to prevent recurrence of symptoms.

Estrogen therapy: ET is the standard treatment for GSM. It has proven to be successful in rapidly restoring vaginal epithelium and associated vasculature, improving vaginal secretions, lowering vaginal pH to restore healthy vaginal flora, and alleviating overall vulvovaginal symptoms.²⁴ Both systemically (eg, oral or patch) and vaginally administered forms are effective in improving GSM. However, hormonal therapy is only considered after all risk factors and benefits have been thoroughly reviewed with the patient. The lowest effective dosage of systemic ET is always advisable, as the stimulatory effect of high estrogen levels on the endometrium can lead to proliferation, hyperplasia, or carcinoma. Local ET is the most accepted form of therapy for GSM; it also offers the fastest and most effective symptomatic relief. Although local ET does not reduce the risk of osteoporosis or effectively manage vasomotor symptoms, up to 90% of women report subjective improvement of their symptoms.²⁵ As with all hormone replacement therapies, some risks accompany the benefits of treatment. Each woman should discuss her situation with her physician to determine the duration and severity of her series of symptoms. Women may prefer to avoid hormone therapy and approach the option of

TABLE 4
Classifications, etiologies, and risk factors for superficial and deep dyspareunia

	Subtype	
	Superficial	Deep
Prevalence	More common	Less common
Location	Vulvar region, vaginal opening	Pelvic region, internal genitalia
Etiologies	Genitourinary syndrome of menopause, vulvitis, vulvovaginitis, vulvovestibulitis, genital herpes, urethritis, atrophic vulvitis, lack of lubrication, vaginal dryness, vaginal infection, episiotomy, radiotherapy, sexual trauma, and topical irritants	Pelvic inflammatory disease; gynecological, pelvic, or abdominal surgery; postoperative adhesions; endometriosis; genital or pelvic tumors; irritable bowel syndrome; urinary tract infections; and ovarian cysts
Risk factors	Age, menopause, hypoestrogenism, vaginal atrophy, lack of arousal and lubrication, and pelvis floor abnormalities	
Type of pain	Sharp, burning, itching	

Gandhi. Genitourinary syndrome of menopause. *Am J Obstet Gynecol* 2016.

TABLE 5
Physical findings of urogenital instrumentation in genitourinary syndrome of menopause

Cystoscopy	Laparoscopy
Squamous metaplasia of trigone	Atrophic uterus, fallopian tubes, and ovaries
Shortening of urethra	Supporting lax ligaments
Pale urethral mucous membrane	
Urinary sphincter dysfunction (eg, decreased contractility)	
Compliance	
Pale trigone	

Gandhi. Genitourinary syndrome of menopause. *Am J Obstet Gynecol* 2016.

over-the-counter vaginal creams for symptomatic relief. Although side effects are uncommon, systemic ET is associated with breast tenderness and/or enlargement, vaginal bleeding or spotting, nausea, and modest weight gain. In cases where the patch is used, some irritation at application sites may occur. The most common side effect of hormone replacement therapy is increased systemic estrogen. Additionally, some women might experience headache, back pain, abdominal pain, and vaginal yeast infections. Breast tenderness most often decreases with time, and taking oral estrogen with food can prevent nausea. Common side effects of intravaginal products include vaginal secretion, vaginal spotting, and genital pruritus. To avoid any harmful long-term side effects of hormone replacement therapy, many physicians advise patients to use the cream or gel for 6 months, discontinue temporarily, and then resume

treatment. Contraindications to the use of ET include known or suspected cases of breast cancer, estrogen-dependent cancers, undiagnosed vaginal bleeding, history of thromboembolism (ie, blood clotting disorders), endometrial hyperplasia or cancer, hypertension, hyperlipidemia, liver disease, hypersensitivity to active compounds in ET, history of stroke, venothrombotic events, coronary heart disease, pregnancy, smoking in those age >35 years, migraines with neurologic symptoms, and acute cholecystitis/cholangitis. **Systemic:** Systemic hormone replacement therapy is suggested to patients who seek relief from GSM symptoms in addition to relief from hot flashes and protection from osteoporosis.²⁶ Due to concomitant use of progestin in women with a uterus, systemic ET is associated with adverse effects such as endometrial bleeding, breast tenderness, increased risk of stroke, venous thromboembolism, and breast cancer. Potential adverse effects of estrogen-progestin therapy may cause the therapy to be contraindicated and unacceptable to some women. Women taking systemic hormone therapy with unresolved symptoms should also take continuous or intermittent topical ET. **Topical:** Topical estrogens alone supply sufficient estrogen to reduce symptoms and reverse atrophic vaginal epithelial conditions. The treatment limits systemic absorption by avoidance of hepatic metabolism. Thus, additional progestin is not necessary to prevent endometrial hyperplasia or cancer. Topical treatment is advised to patients who seek relief solely from vaginal atrophy symptoms, as the low dose of estrogen may not be enough to alleviate other menopausal symptoms. In contrast to systemic estrogen, topical estrogens do not solve vasomotor symptoms associated with menopause or reduce the risks of osteoporosis. According to the North American Menopause Society, low-dose vaginal estrogens decrease vaginal pH, increase the number of vaginal lactobacilli, improve vaginal and urethral cytology, and prevent frequent UTI.¹¹ Vaginal ET trials have also demonstrated relief of urinary symptoms of urgency, frequency, nocturia, and stress/urgency urinary incontinence.²³ Vaginal tablets, creams, and rings are the routes of low-dose local estrogen; the 2006 Cochrane Database of Systematic Reviews stated that all types are equally effective in resolution of dyspareunia, vaginal itching, and dryness.²⁷ Women should choose the option of low-dose vaginal ET based on their personal preference and lifestyle. Women may select the tablet over the cream due to reduction in mess. Creams are currently the most common choice of vaginal product for the treatment of GSM and provide flexibility of dosage and frequency of administration. Advantages of estradiol-releasing vaginal rings are that they are long-acting over a period of 3 months and require less sustained effort to use. However, there are reports of occasional vaginal ring expulsion so adequate dexterity is required for insertion and removal. Cystoceles or rectoceles may also cause the ring to become displaced and fall out. Roughly 80-90% of women on local ET report subjective improvement and relief from GSM.^{12,16,22} Care and monitoring are often customized depending on a woman's medical history and symptoms. Relevant factors include whether a woman is premenopausal or postmenopausal, whether she has a uterus, and whether she has had hormone-dependent cancer (eg, breast or endometrial). In asymptomatic women using topical estrogens, there are currently insufficient data to recommend annual endometrial surveillance.²⁸

Selective estrogen receptor modulator: Another oral treatment option for GSM are selective estrogen receptor modulators (SERM). Ospemifene was approved by the Food and Drug Administration in 2013. Ospemifene provides a therapeutic pharmacologic treatment option for patients who are not candidates for ET. The current literature shows that it is both efficacious and safe in treating vulvovaginal atrophy and dyspareunia by improving vaginal structure and pH.²⁹ Double-blind

TABLE 6

Diagnostic tests to consider post–initial clinical assessment

Tests	Findings
Pelvic exam with speculum and bimanual palpation (with topical anesthesia); vaginoscopy	Loss of rugae
Rectal exam	Rectal mass; rectocele
Transvaginal ultrasound; hysteroscopy	Endometrial stripe <5 mm indicating loss of estrogenic stimulation; pelvic mass
pH test	Symptomatic pH: 5–7 (normal pH: 3.5–4.5)
Vaginal cytology	Basal epithelial cells predominate and decreased percentage of superficial cells
Wet mount	Presence of leukocytes and paucity of <i>Lactobacillus</i>
Pap test	Atrophy of cervix and stenosis of os
MRI/CT scan	Pelvic and adnexal abnormalities

CT, computed tomography; MRI, magnetic resonance imaging.

Gandhi. Genitourinary syndrome of menopause. Am J Obstet Gynecol 2016.

placebo-controlled studies have shown that it remains efficacious and safe up to 52 weeks while providing greater symptomatic relief than vaginal lubricants. There were no cases of endometrial cancer and <1% of patients experienced endometrial hyperplasia with treatment.³⁰ Similar to ET, ospemifene increases the incidence of thromboembolism and should be avoided in patients with increased risk of venous thromboembolism. Lasofoxifene is another SERM that binds to both estrogen receptor types and has high oral bioavailability. Three phase III clinical trials showed that lasofoxifene is effective in increasing bone mineral density.³¹⁻³³ Additionally, the drug has been shown to have many other beneficial effects such as decreased coronary disease, stroke, vaginal pH, and vaginal dryness.³⁴ A newer therapy, tissue-specific estrogen complex, involves combining a SERM with a conjugated estrogen. Studies show that pairing bazedoxifene, a SERM, with estrogens is associated with higher safety and better tolerability than estrogen-progestin therapy.^{35,36}

Laser therapies: Recently, the use of laser treatment has become an innovative treatment option for GSM. In 2014, the Food and Drug Administration approved the use of fractional microablative carbon-dioxide laser therapy for genitourinary surgery. At specific diode parameters, laser therapy stimulates improved vascularity; improved glycogen storage, collagen, and extracellular matrix production; as well as cellular proliferation to increase the thickness of the squamous epithelium with the formation of new papilla, thus enhancing the viability of the vaginal epithelium.³⁷⁻³⁹ One study reported that improvement of vaginal dryness, pruritus, dysuria, and dyspareunia was maintained at 12 weeks' follow-up posttherapy.⁴⁰ This study included 50 women and reported an 84% satisfaction rate with the laser treatment. In addition, no adverse events were reported during the study period. Additional research has shown that the microablative therapy also significantly improves quality of life and sexual function.³⁸ In all, 85% of women who were previously not sexually active due to GSM symptoms regained a normal sexual life at 12 weeks following therapy.⁴¹ Novel nonablative laser therapies are also being studied for use in the treatment vulvovaginal symptoms. Pilot studies have found that vaginal erbium laser treatment significantly improves both vaginal dryness and dyspareunia up to 24 weeks after treatment.⁴² Precise impulses are released to raise the temperature of vaginal tissue, stimulating remodeling of collagen in the introitus and vaginal canal. Novel low-energy dynamic quadripolar radiofrequency (DQRF) lasers are now also being used for vulvovaginal treatment. Previous ex vivo and in vivo studies demonstrated that DQRF thermal treatment could produce thickening and rearrangement of collagen and elastin fibers without side effects in the epidermis, nerves, or blood vessels.⁴³ A study conducted by Vicariotto and Raichi⁴⁴ demonstrated that in women with vaginal laxity, DQRF produced subjective improvement in laxity, sexual satisfaction, dysuria, and incontinence. As an attractive novel nonhormonal therapy for GSM, additional studies are needed to explore the long-term safety and efficacy of various laser therapies on genitourinary symptoms.

Synthetic steroid: Tibolone, a synthetic steroid, has been found not only to improve the VMI but also increase sex drive through its partandrogenic properties. Moreover, urinary incontinence problems of nocturia and urgency were found to be minimized.⁴⁵

Oxytocin: Oxytocin, the neuropeptide released by the posterior pituitary gland, has also been studied amidst concerns over ET. A randomized double-blind controlled trial conducted in Stockholm reported that application of oxytocin gel produced healthier and more normalized vaginal epithelium. Treated participants reported significant reduction in their most bothersome symptom. Additionally, vaginal pH decreased with use of oxytocin and no increase in endometrial thickness was observed.⁴⁶

Intravaginal dehydroepiandrosterone: Dehydroepiandrosterone (ie, prasterone) is a steroid hormone intermediate in the biosynthesis pathway for androgen and estrogen synthesis. A recent randomized, double-blind, placebocontrolled phase III trial showed that daily intravaginal application of 0.5% dehydroepiandrosterone increased superficial cell percentage and decreased parabasal cell in the vaginal epithelium, decreased vaginal pH, and decreased sexual pain. At gynecological examination, dehydroepiandrosterone application improved vaginal secretions, epithelial thickness, and color in comparison to placebo.⁴⁷ As a promising novel therapy, more research is needed to assess the long-term efficacy and safety of dehydroepiandrosterone.

Moisturizers and lubricants: Moisturizers and lubricants are used for temporary relief of vaginal dryness and itching during sexual intercourse. These therapy options do not reverse most vaginal atrophic effects and have effectiveness length of <24 hours. Hence, they are more useful and recommended to women with mild symptoms, or should be used in conjunction with systemic or topical ET. Moisturizers may contain polycarbophil-based polymers that adhere to the epithelial and mucin

cells on the vaginal wall to preserve moisture levels.²⁴ When selecting a lubricant or moisturizer, it is advised that the product should mimic vaginal secretions in terms of osmolality, pH, and composition.⁴⁸

Homeopathic remedies: It is estimated that 10% of women experiencing vaginal symptoms of GSM are using herbal therapies such as black cohosh, dong quai, phytochemicals, nettle (250 mL infusion/d), comfrey root, motherwort, soy foods, and chaste tree extract. Other alternatives and complementary therapies are chickweed tincture, wild yam, and acidophilus capsules. Although homeopathic remedies show improvement in vaginal tissue flexibility, studies show that there is no proven efficacy on the vaginal epithelium and treatment of GSM.¹⁶ Some vitamins such as vitamin E and D have been used for GSM therapy; vitamin D may help generate keratinocyte proliferation and differentiation in the vaginal epithelium.²⁴

Lifestyle modifications: Increased sexual activity is advised for maintaining robust vaginal muscle condition. There is a positive link between sexual activity and maintenance of vaginal elasticity and pliability as well as lubricative response to sexual stimulation. Sexual intercourse improves blood circulation to the vagina and seminal fluid also contains sexual steroids, prostaglandins, and essential fatty acids, which serve to maintain vaginal tissue. Vulvovaginal tissue stretching also helps to promote vaginal elasticity. Masturbation or sex devices are options for patients without a partner.²² Stressreduction therapy and psychological counseling may benefit women with nonorganic causes of vaginal dryness. Cessation of smoking can help relieve symptoms. Lastly, wearing looser undergarments and legwear may improve air circulation, discouraging growth of microorganisms.

Conclusion:

“Genitourinary syndrome of menopause” is the latest terminology instated to increase awareness and reduce social stigma of the genitourinary sequelae and sexual dysfunction associated with postmenopausal hypoestrogenism. ET is the mainstay of medical treatment but the risks and benefits should be thoroughly discussed with each patient. More importantly the physician and patient should work together to find the optimal combination of lifestyle changes and management options. Global assessment scales for GSM are currently seeing development; a proposed tool rates elasticity, lubrication, and tissue integrity; state and color of individual vulvovaginal and urethral anatomy; as well as pH and VMI.⁴⁹ Such assessment tools may help a physician to tailor treatment based on the objective and subjective severity of signs and symptoms. Newer treatments such as laser therapy are promising but require further studies to prove long-term efficacy.

References

- Portman DJ, Gass ML; Vulvovaginal Atrophy Terminology Consensus Conference Panel. Genitourinary syndrome of menopause: new terminology for vulvovaginal atrophy from the International Society for the Study of Women's Sexual Health and the North American Menopause Society. *Menopause* 2014;21:1063-8.
- Palacios S. Managing urogenital atrophy. *Maturitas* 2009;63:315-8.
- DiBonaventura M, Luo X, Moffatt M, Bushmakina AG, Kumar M, Bobula J. The association between vulvovaginal atrophy symptoms and quality of life among postmenopausal women in the United States and Western Europe. *J Womens Health (Larchmt)* 2015;24: 713-22.
- Keil K. Urogenital atrophy: diagnosis, sequelae, and management. *Curr Womens Health Rep* 2002;2:305-11.
- Mac Bride MB, Rhodes DJ, Shuster LT. Vulvovaginal atrophy. *Mayo Clin Proc* 2010;85: 87-94.
- Nappi RE, Kokot-Kierepa M. Vaginal health: insights, views and attitudes (VIVA) results from an international survey. *Climacteric* 2012;15: 36-44.
- Nappi RE, Panay N, Rabe T, Krychman M, Particco M. Results of the European REVIVE (REal Women's View of Treatment Options for Menopausal Vulvar/Vaginal ChangEs) survey. 10th Congress of the European Menopause and Andropause Society; May 20-22, 2015; Madrid, Spain.
- Castelo-Branco C, Biglia N, Nappi RE, Schwenkhagen A, Palacios S. Characteristics of post-menopausal women with genitourinary syndrome of menopause: implications for vulvovaginal atrophy diagnosis and treatment selection. *Maturitas* 2015;81:462-9.
- Davila GW, Singh A, Karapanagiotou I, et al. Are women with urogenital atrophy symptomatic? *Am J Obstet Gynecol* 2003;188: 382-8.
- Wines N, Willsteed E. Menopause and the skin. *Australas J Dermatol* 2001;42:149-58; quiz 159.
- North American Menopause Society. The role of local vaginal estrogen for treatment of vaginal atrophy in postmenopausal women: 2007 position statement of the North American Menopause Society. *Menopause* 2007;14: 355-69; quiz 370-1.
- Goldstein I. Recognizing and treating urogenital atrophy in postmenopausal women. *J Womens Health (Larchmt)* 2010;19:425-32.
- Chen GD, Oliver RH, Leung BS, Lin LY, Yeh J. Estrogen receptor alpha and beta expression in the vaginal walls and uterosacral ligaments of premenopausal and postmenopausal women. *Fertil Steril* 1999;71: 1099-102.
- Nappi RE, Palacios S. Impact of vulvovaginal atrophy on sexual health and quality of life at postmenopause. *Climacteric* 2014;17:3-9.
- Luthje P, Hirschberg AL, Brauner A. Estrogenic action on innate defense mechanisms in the urinary tract. *Maturitas* 2014;77:32-6.
- Willhite LA, O'Connell MB. Urogenital atrophy: prevention and treatment. *Pharmacotherapy* 2001;21:464-80.
- Robinson D, Cardozo LD. The role of estrogens in female lower urinary tract dysfunction. *Urology* 2003;62(Suppl):45-51.
- Hyun HS, Park BR, Kim YS, Mun ST, Bae DH. Urodynamic characterization of postmenopausal women with stress urinary incontinence: retrospective study in incontinent pre- and post-menopausal women. *J Korean Soc Menopause* 2010;16:148-52.
- Utian WH. Biosynthesis and physiologic effects of estrogen and pathophysiological effects of estrogen deficiency: a review. *Am J Obstet Gynecol* 1989;161:1828-31.
- Kao A, Binik YM, Kapuscinski A, Khalife S. Dyspareunia in postmenopausal women: a critical review. *Pain Res Manag* 2008;13: 243-54.
- Butcher J. ABC of sexual health: female sexual problems II: sexual pain and sexual fears. *BMJ* 1999;318:110-2.
- North American Menopause Society. Management of symptomatic vulvovaginal atrophy: 2013 position statement of the North American Menopause Society. *Menopause* 2013;20:888-902; quiz 903-4.
- Rahn DD, Carberry C, Sanses TV, et al. Vaginal estrogen for genitourinary syndrome of menopause: a systematic review. *Obstet Gynecol* 2014;124:1147-56.

24. Palacios S, Castelo-Branco C, Currie H, et al. Update on management of genitourinary syndrome of menopause: a practical guide. *Maturitas* 2015;82:308-13.
25. Cardozo L, Bachmann G, McClish D, Fonda D, Birgerson L. Meta-analysis of estrogen therapy in the management of urogenital atrophy in postmenopausal women: second report of the Hormones and Urogenital Therapy Committee. *Obstet Gynecol* 1998;92: 722-7.
26. Brockie J. Managing menopausal symptoms: hot flushes and night sweats. *Nurs Stand* 2013;28:48-53.
27. Suckling J, Lethaby A, Kennedy R. Local estrogen for vaginal atrophy in postmenopausal women. *Cochrane Database Syst Rev* 2006: CD001500.
28. Castelo-Branco C, Cancelo MJ, Villero J, Nohales F, Julia MD. Management of post-menopausal vaginal atrophy and atrophic vaginitis. *Maturitas* 2005;52(Suppl): S46-52.
29. Paton DM. Ospemifene for the treatment of dyspareunia in postmenopausal women. *Drugs Today (Barc)* 2014;50:357-64.
30. Constantine GD, Goldstein SR, Archer DF. Endometrial safety of ospemifene: results of the phase 2/3 clinical development program. *Menopause* 2015;22:36-43.
31. Moffett A, Ettinger M, Bolognese M, et al. Lasofoxifene, a next generation SERM, is effective in preventing loss of BMD and reducing LDLC in postmenopausal women. *J Bone Miner Res* 2004;19:S96.
32. McClung MR, Siris E, Cummings S, et al. Prevention of bone loss in postmenopausal women treated with lasofoxifene compared with raloxifene. *Menopause* 2006;13:377-86.
33. Cummings S, Eastell R, Ensrud K. The effects of lasofoxifene on fractures and breast cancer: 3 year results from the PEARL trial. *J Bone Miner Res* 2008;23:S81.
34. Gennari L. Lasofoxifene, a new selective estrogen receptor modulator for the treatment of osteoporosis and vaginal atrophy. *Expert Opin Pharmacother* 2009;10:2209-20.
35. Komm BS, Mirkin S, Jenkins SN. Development of conjugated estrogens/bazedoxifene, the first tissue selective estrogen complex (TSEC) for management of menopausal hot flashes and postmenopausal bone loss. *Steroids* 2014;90:71-81.
36. Kagan R. The tissue selective estrogen complex: a novel approach to the treatment of menopausal symptoms. *J Womens Health (Larchmt)* 2012;21:975-81.
37. Abrahamse H. Regenerative medicine, stem cells, and low-level laser therapy: future directives. *Photomed Laser Surg* 2012;30:681-2
38. Stefano S, Stavros A, Massimo C. The use of pulsed CO2 lasers for the treatment of vulvovaginal atrophy. *Curr Opin Obstet Gynecol* 2015;27:504-8.
39. Hutchinson-Colas J, Segal S. Genitourinary syndrome of menopause and the use of laser therapy. *Maturitas* 2015;82:342-5.
40. Salvatore S, Nappi RE, Zerbinati N, et al. A 12-week treatment with fractional CO2 laser for vulvovaginal atrophy: a pilot study. *Climacteric* 2014;17:363-9.
41. Salvatore S, Nappi RE, Parma M, et al. Sexual function after fractional microablative CO(2) laser in women with vulvovaginal atrophy. *Climacteric* 2015;18:219-25.
42. Gambacciani M, Levancini M, Cervigni M. Vaginal erbium laser: the second-generation thermotherapy for the genitourinary syndrome of menopause. *Climacteric* 2015;18: 757-63.
43. Nicoletti G, Cornaglia AI, Faga A, Scevola S. The biological effects of quadripolar radiofrequency sequential application: a human experimental study. *Photomed Laser Surg* 2014;32:561-73.
44. Vicariotto F, Raichi M. Technological evolution in the radiofrequency treatment of vaginal laxity and menopausal vulvo-vaginal atrophy and other genitourinary symptoms: first experiences with a novel dynamic quadripolar device. *Minerva Ginecol* 2016;68: 225-36.
45. Mendoza N, Abad P, Baro F, et al. Spanish Menopause Society position statement: use of tibolone in postmenopausal women. *Menopause* 2013;20:754-60.
46. Al-saqi SH, Uvnäs-moberg K, Jonasson AF. Intravaginally applied oxytocin improves postmenopausal vaginal atrophy. *Post Reprod Health* 2015;21:88-97.
47. Labrie F, Archer DF, Koltun W, et al. Efficacy of intravaginal dehydroepiandrosterone (DHEA) on moderate to severe dyspareunia and vaginal dryness, symptoms of vulvovaginal atrophy, and of the genitourinary syndrome of menopause. *Menopause* 2016;23: 243-56.
48. Edwards D, Panay N. Treating vulvovaginal atrophy/genitourinary syndrome of menopause: how important is vaginal lubricant and moisturizer composition? *Climacteric* 2016;19: 151-61.
49. Panay N. Genitourinary syndrome of the menopause: dawn of a new era? *Climacteric* 2015;18(Suppl):13-7.

Vaginal erbium laser: the second-generation thermotherapy for the genitourinary syndrome of menopause

(2015), *Climacteric*, 18:5, 757-763.

M. Gambacciani ^{*}, M. Levancini ^{*, †} and M. Cervigni [‡]

^{*} Department of Obstetrics and Gynecology, Pisa University Hospital, Pisa, Italy; [†] Department of Obstetrics and Gynecology, Clinica Alemana, Universidad Del Desarrollo, Santiago, Chile; [‡] Department of Obstetrics and Gynecology, Catholic University of the Sacred Heart, Rome, Italy

Abstract

Aim: To evaluate the effects of the vaginal erbium laser (VEL) in the treatment of postmenopausal women suffering from genitourinary syndrome of menopause (GSM).

Method: GSM was assessed in postmenopausal women before and after VEL (one treatment every 30 days, for 3 months; $n = 45$); the results were compared with the effects of a standard treatment for GSM (1 g of vaginal gel containing 50 μ g of estriol, twice weekly for 3 months; $n = 25$). GSM was evaluated with subjective (visual analog scale, VAS) and objective (Vaginal Health Index Score, VHIS) measures. In addition, in 19 of these postmenopausal women suffering from stress urinary incontinence (SUI), the degree of incontinence was evaluated with the International Consultation on Incontinence Questionnaire-Urinary Incontinence Short Form (ICIQ-UI SF) before and after VEL treatments.

Results: VEL treatment induced a significant decrease of VAS of both vaginal dryness and dyspareunia ($p < 0.01$), with a significant ($p < 0.01$) increase of VHIS. In postmenopausal women suffering from mild to moderate SUI, VEL treatment was associated with a significant ($p < 0.01$) improvement of ICIQ-SF scores.

The effects were rapid and long lasting, up to the 24th week of the observation period. VEL was well tolerated with less than 3% of patients discontinuing treatment due to adverse events.

Conclusion: This pilot study demonstrates that VEL induces a significant improvement of GSM, including vaginal dryness, dyspareunia and mild to moderate SUI. Further studies are needed to explore the role of laser treatments in the management of GSM.

Genitourinary syndrome of menopause and the use of laser therapy

(2015), *Maturitas*, Dec;82(4):342-5.

Juana Hutchinson-Colas^a, Saya Segala^{a, b}

^a Division of Female Pelvic Medicine and Reconstructive Surgery, Department of Obstetrics, Gynecology and Reproductive Sciences, Rutgers-Robert Wood Johnson Medical School, New Brunswick, NJ, USA

^b Division of Urology, Department of Surgery, Rutgers-Robert Wood Johnson Medical School, New Brunswick, NJ, USA

Abstract

Genitourinary syndrome of menopause is a common condition that left untreated can progress and negatively affect quality of life and sexual function. Laser therapy has a therapeutic role for several gynecologic conditions and most recently has gained interest as a non-hormonal treatment for genitourinary syndrome of menopause (GSM). The laser is well tolerated and may increase thickness of the squamous epithelium and improve vascularity of the vagina. These morphological changes presumably alleviate symptoms of dryness, dyspareunia, and irritation. However, the duration of therapeutic effects and safety of repeated applications at this point is not clear. Further research is needed in the form of controlled studies of the laser and other non-hormonal GSM therapies. The objective of this paper is to review the existing literature describing laser therapy for GSM.

Rationale and design for the Vaginal Erbium Laser Academy Study (VELAS): an international multicenter observational study on genitourinary syndrome of menopause and stress urinary incontinence

(2015), *Climacteric*, 18:sup1, 43-48

M. Gambacciani, M. G. Torelli *, L. Martella †, G. L. Bracco ‡, A. G. Casagrande **, E. Albertin ††, S. Tabanelli ‡‡, M. Viglietta ***, G. D' Ambrogio †††, G. Garone ‡‡‡ and M. Cervigni ****

Department of Obstetrics and Gynecology, University Hospital Pisa; * Centro Palmer, Reggio Emilia; † Centro Medico Radiologico 3P, Noventa di Piave (VE); ‡ Ospedale Campo di Marte Lucca; ** Studio Medico, Novara; †† Poliambulatorio Elysium, Albignasego (Padova); ‡‡ Ambulatorio Ginecologico, Bologna; *** Studio Medico Fossano (CN); ††† Centro Medico Pignatelli, Lecce; ‡‡‡ Centro Sofi a, Monza; **** Department of Obstetrics and Gynecology, Catholic University, Rome, Italy

Abstract

The genitourinary syndrome of menopause (GSM) and stress urinary incontinence (SUI) are common clinical challenges for women's health and quality of life. The laser treatment and particularly the vaginal erbium laser (VEL) may provide a new non-invasive treatment for both GSM and SUI. However, the estimation of the ultimate results of different laser treatments may be altered by different issues, such as patient selection, concomitant treatments, and long-term effect of vaginal laser thermotherapy. In the present paper, we present the protocol for a large multicenter study on the evaluation of the efficacy and safety of VEL for the treatment of GSM and SUI, the Vaginal Erbium Laser Academy Study (VELAS). This study will evaluate the effects of three laser applications in 1500 postmenopausal women. Subjective and objective symptoms will be evaluated prior to the first laser treatment with follow-up visits after 4 weeks from the last laser application, and subsequently after every 3 months for 1 year. Findings from the VELAS have the potential to affect clinical care practice and health decisions for millions of women world-wide for a non-hormonal treatment for GSM and a non-invasive treatment of SUI.

First assessment of short-term efficacy of Er:YAG laser treatment on stress urinary incontinence in women: prospective cohort study

(2015), *Climacteric*, 18:sup1, 37-42.

N. Fistonjć *, I. Fistonjć *, A. Lukanovič †, Š. Findri Guštek *, I. Sirta Bilajac Turina ‡ and D. Franić **

Ob/Gyn Clinic, University Hospital Merkur, Zagreb, Croatia; * Ob/Gyn & Menopause Clinic, Zagreb, Croatia; † Division of Gynecology, University Medical Center, Ljubljana, Slovenia; ‡ Institute of Public Health, Rijeka, Croatia; ** Department of Obstetrics and Gynecology, General Hospital Ptuj, Slovenia

Abstract

Objectives: This is the first assessment of efficacy and safety of the Er:YAG laser in the treatment of stress urinary incontinence. The aim of this study was to assess the short-term outcome of a non-invasive laser treatment for mild-to-severe stages of this condition and to check its applicability in different body mass index and age groups.

Methods: A prospective cohort, single-center study at the Ob/Gyn Clinic, Zagreb, Croatia recruited a consecutive sample of 73 female patients suffering from stress urinary incontinence. The procedure was performed with a 2940-nm Er:YAG laser (XS Dynamis, Fotona, Slovenia) designed to achieve heating up of vaginal mucosa to around 60 °C, 500 – 700 μm in depth.

Results: The score in the International Consultation on Incontinence Questionnaire-Urinary Incontinence Short Form was reduced to a median of 46% (95% confidence interval 33 – 67%; $p < 0.001$). The reduction was significantly higher in women with normal body mass index (67%) than in overweight women (25%), as well as in women younger than 39 years (100%) compared with those older than 60 years (8%) ($p < 0.001$).

No serious adverse events were noticed.

Conclusion: This study of Er:YAG laser therapy in women has demonstrated a clinically relevant, short-term improvement of stress urinary incontinence, with minimal adverse events of a transient nature.

Minimally invasive laser procedure for early stages of stress urinary incontinence (SUI)

(2012), J. LAHA, Vol. 2012, No.1; pp. 67-74.

Fistonić Ivan, Findrić Guštek Štefica, Fistonić Nikola

Abstract

The objective of this labeled, prospective, single-center pilot study was to assess the efficacy and safety of a novel minimally invasive, non-ablative laser treatment in the early stages of SUI.

A total of 39 patients suffering from mild to moderate stress urinary incontinence underwent treatment with an Er:YAG (2940 nm) laser in non-ablative fractional mode. Assessment tools included the ICIQ-UI SF questionnaire for assessing the degree of incontinence and its impact on the quality of life, the Q-tip test for evaluating the mobility of the urethra and bladder neck, PISQ-12 for assessing quality of life in the area of sexuality, and perineometry for the measurement of muscle strength. Follow-ups were scheduled after 1 month for 39 patients, after 3 months for 22 patients and after 6 months for 6 patients.

Preliminary results of post-treatment evaluation showed significant improvement ($p < 0.05$) in all the domains tested: ICIQ-UI scores decreased by more than 3 points at all follow-ups. A mean duration of muscle contraction measured with perineometry at 1 month increased by 4.7 s, at 3 months by 11.8 s and at 6 months by 22.8 s. Q-tip angle decreased by 14.7° at 1 month follow-up, by 15.9° at 3 months and by 22.5° at 6 months. PISQ-12 scores increased after 1 month by 5.4 points, after 3 months by 5.9 points and after 6 months by 6.6 points.

The preliminary results confirm that a minimally invasive, non-ablative fractional laser treatment (IncontiLase™) is an effective, safe and comfortable treatment option for symptom relief in patients with mild and moderate SUI.

Erbium laser in gynecology

(2015) *Climacteric*, 18:sup1, 4-8.

Z. Vizintin, M. Lukac, M. Kazic and M. Tettamanti*

*Latinmed, Stuart, Florida, USA

Abstract

The aim of this paper is to present a novel laser technology utilizing the erbium YAG laser for various minimally invasive, non-surgical procedures in gynecology. Non-ablative, thermal-only SMOOTH-mode erbium pulses are used to produce vaginal collagen hyperthermia, followed by collagen remodeling and the synthesis of new collagen fibers, resulting in improved vaginal tissue tightness and elasticity. This erbium laser technology is used for treatments of vaginal laxity, stress urinary incontinence, pelvic organ prolapse and vaginal atrophy. In the period from 2010 to 2014, several clinical studies covering all four indications were conducted with the aim to prove the efficacy and safety of this novel technology. An overview is presented of the results of these studies where several objective as well as subjective assessment tools were used. The results have shown that SMOOTH-mode erbium laser seems to be an effective and safe method for treating vaginal laxity, stress urinary incontinence, pelvic organ prolapses and vaginal atrophy.

Laser procedure for female urinary stress incontinence: A review of the literature

Progrès en urologie (2017) 27, 1076—1083

C. Contéa, T. Jauffreta, S. Vieillefosse, J.F. Hermieub, X. Deffieuxa

Summary

Introduction: There is increasing interest in noninvasive treatment of female stress urinary incontinence (SUI), including a vaginal laser procedure. In view of a lack of data on this technique, we conducted a non-systematic review of the literature.

Methods: We reviewed studies concerning the laser treatment of SUI from PubMed, Medline, the Cochrane Library and Web of Science. Study design, outcome measure, number of participants, procedural complications and results were analyzed.

Results: The use of laser treatment of female SUI has been described in 7 prospective, singlecenter and non-comparative (no control group) studies, all of which used an erbium YAG or a CO2 laser in thermal non-ablative treatment. Primary outcome was ICIQ-UI-SF score in six studies, and pad tests in one study. Follow-up ranged from 5 to 36 months. Improvement rates ranged from 62% to 78%. No major adverse events were noted. Minor side effects included sensation of warmth, increased vaginal discharge and transient urge urinary incontinence.

Conclusion: The efficacy of vaginal laser treatment of SUI has not been assessed in comparative studies. More rigorous and adequately powered trials are required to assess the relative benefits and adverse event profile of laser treatment of SUI, as compared with other minimally invasive procedures.

Key words

Laser procedure, Stress urinary, incontinence, Female, Phototherapy

Effect of non-ablative laser treatment on overactive bladder symptoms, urinary incontinence and sexual function in women with urodynamic stress incontinence

Taiwanese Journal of Obstetrics & Gynecology 56 (2017) 815e820

Yi-Hao Lin, Wu-Chiao Hsieh, Lulu Huang, Ching-Chung Liang

Abstract

Objective: To investigate the effects of non-ablative laser treatment on overactive bladder (OAB) syndromes, stress urinary incontinence and sexual function in women with urodynamic stress incontinence (USI).

Materials and methods: Between April 2015 and June 2015, consecutive patients with USI with OAB syndromes underwent two sessions of Erbium:YAG laser treatment in a tertiary hospital. Patients received validated urological questionnaires, urodynamic studies, 1-h pad test and measurement of vaginal pressure before, one and three months after laser treatment. Questionnaires at 12 months were completed by telephone interview. Adverse effects and patients' satisfaction were also assessed.

Results: We included 30 patients with a mean age of 52.6 ± 8.8 years. Three months after therapy, mean 1-h pad test significantly decreased ($P \leq 0.039$). Significant improvement in OAB symptoms in four questionnaires were noted at three months post treatment, but not sustained for 12 months in two of them. Three months after therapy, mean vaginal pressure significantly improved ($P \leq 0.009$). Of 24 (82.7%) sexually active patients, 62.5% (15/24) and 54.2% (13/24) of their sexual partners reported improved sexual gratification three months later. No major adverse effects were noticed.

Conclusions: Erbium:YAG laser treatment can resolve USI and coexistent OAB symptoms three months after therapy. Sexual experience is also improved. However, repeated laser therapy may be necessary after six months.

Key words

Erbium:YAG laser, Overactive bladder, Stress urinary incontinence, Questionnaire

Laser therapy for the genitourinary syndrome of menopause. A systematic review and meta-analysis

Maturitas 103 (2017) 78–88

Eleni Pitsouni, Themou Grigoriadis, Matthew E. Falagas, Stefano Salvatore, Stavros Athanasiou

Abstract

This study aimed to identify and then synthesize all available data regarding the efficacy of laser therapy for postmenopausal women with genitourinary syndrome of menopause (GSM) with/without urinary incontinence (UI). PubMed, Scopus, Web of Science, Cochrane Library and ClinicalTrials.gov were searched in October 2016. The keywords were “laser genitourinary syndrome of menopause”, “laser vulvovaginal atrophy”, “laser vaginal atrophy” and “laser women incontinence”. Quality of reporting and risk of bias of the included studies were assessed according to STROBE and MINORs checklists, respectively. Quality of the body of evidence was evaluated with the GRADE approach. Fourteen studies involving 542 participants were included in this systematic review and meta-analysis. All GSM symptoms (dryness/ dyspareunia/ itching/ burning/ dysuria/ urgency/ frequency) and UI decreased significantly and consistently in all available publications. The pooled mean differences for the various symptoms were: dryness $-5.5(95\%CI:-6.7,-4.4;7\text{studies};I2:0\%)$, dyspareunia $-5.6(95\%CI:-6.8,-4.5;7\text{studies};I2:0\%)$, itching $-4(95\%CI:-5.7,-2.2;6\text{studies};I2:79\%)$, burning $-3.9(95\%CI:-5.9,-2;6\text{studies};I2:87\%)$, dysuria $-2.9(95\%CI:-5.1,-0.7;4\text{studies};I2:90\%)$ and UI $-4.9(95\%CI:-6.4,-3.4;2\text{studies};I2:0\%)$. Because urgency/frequency was assessed by different methodologies the data could not be meta-analyzed. Furthermore, KHQ, UDI-6, MCS12/PCS12, FSFI, overall sexual satisfaction and measurements of the effect of laser therapy on the local pathophysiology improved significantly. In conclusion, laser therapy for postmenopausal women with GSM appears promising. It may reduce symptom severity, improve quality of life of postmenopausal women and restore the vaginal mucosa to premenopausal status. However, the quality of the body of evidence is “low” or “very low” and, thus, evidence-based modification of current clinical practice cannot be suggested

Key words

Genitourinary syndrome of menopause (GSM), Lower urinary tract symptoms (LUTS), Incontinence
Dyspareunia, Female sexual function index (FSFI), Laser therapy

Light and Energy Based Therapeutics for Genitourinary Syndrome of Menopause: Consensus and Controversies

Lasers in Surgery and Medicine 49:137–159 (2017)

Y. Tadir, A. Gaspar, A. Lev-Sagie, M. Alexiades, R. Alinsod, A. Bader, A. Calligaro, J. A. Elias, M. Gambaciani, J. E. Gaviria, C. B. Iglesia, K. Selih-Martinec, P. L. Mwesigwa, U. B. Ogrinc, S. Salvatore, P. Scollo, N. Zerbinati, J. S. Nelson

Gynecologist and plastic surgeons pioneered the application of lasers in medicine and surgery almost 5 decades ago, initially used to treat cervical and vaginal pathologies. Ever since, energy-based devices have been deployed to treat pelvic pathologies and improve fertility. Recent technological developments triggered an unprecedented wave of publications, assessing the efficacy of fractional laser, and radiofrequency on the vaginal wall in reversing natural aging processes. Studies have shown that a certain degree of thermal energy deposited on the vaginal wall stimulates proliferation of the glycogen-enriched epithelium, neovascularization, and collagen formation in the lamina propria, and improves natural lubrication and control of urination. This review aimed to review such data and to guide future research. A unique assembly of experts from around the globe, compiled and edited this manuscript based on a thorough literature review and personal experience.

Key words

laser; radiofrequency; energy based device; genitourinary syndrome of menopause (GSM); vagina; vulva; rejuvenation; stress urinary incontinence (SUI); lichen sclerosus; vulvodynia

VULVODYNIA & LICHEN SCLEROSUS

Erbium:YAG Laser for the Treatment of Vulvodynia. A Pilot Study

University Clinic for Gynaecology and Obstetrics, Clinical Department for Gynaecology, University Hospital Graz

Gerda Trutnovsky, Daniela Ulrich, Vesna Bjelic-Radistic, Karl Tamussino

Background

The term vulvodynia refers to pain in the vulva that has existed for at least 3 months and for which no clinical causes can be identified. Prevalence studies show that up to 8% of all sexually active women are affected by vulvodynia.

Erbium:Yag lasers have long been used in dermatology for the treatment of scars and wrinkles (laser peeling). Recently, this technique has also been used in gynaecology for the vaginal treatment of atrophy (genitourinary syndrome of menopause). To date, there has only been one small pilot study on its use in the treatment of vulvodynia.

The ablative laser emits fractional, pulsed laser light with a wavelength of 2,940nm, which corresponds to the maximum peak of water absorption. At short pulse duration (300 μ s), small tissue volumes are rapidly heated (>100 °) and vaporised. Histological studies show that this stimulates the formation of new blood vessels and connective tissue.

Method

In the gynaecological pain outpatient unit of the University Women's Hospital Graz, women diagnosed with vulvodynia were offered vulva laser therapy as part of a multimodal interdisciplinary therapy.

The treatment was performed in the outpatient unit using EMLA local anaesthetic cream. Depending on the diagnosis, either just the introitus or both the introitus and the vagina were treated. The women were asked to indicate the severity of their pain caused by vulvodynia and dyspareunia using a visual analogue scale (0-10) before the start of the treatment and one month after.

Results

Since February 2017, 13 women have been treated for vulvodynia with the Erbium:Yag laser. To date, 6 women have received only one treatment, 5 women two and 2 women three treatments. The average period between treatments was 47 ± 13 days. The women treated were 41.6 ± 16.1 years (range 21-58) old. The women indicated that the pain associated with the treatment was on average 3.5 ± 2.1 .

In the follow-up, most women showed significant improvement in their symptoms of vulvodynia and dyspareunia.

Discussion

Treatment of the vulva with the Erbium:Yag laser could be a new effective and feasible method of treating vulvodynia.

The Er:YAG role in vulvar lichen sclerosus: Report of two cases

Poster presented at the SIGO Congress, October 2016

Anglana F¹, Frascani F², Oliva C³, Angelucci M⁴, Fasola E⁵, Saccucci P⁶

¹Bios2, Roma ²Medicina Estetica, Roma; ³Dipartimento di Ostetricia e Ginecologia Ospedale San Filippo Neri, Roma;

⁴Dipartimento di Ginecologia Istituto Regina Elena IRE, Roma; ⁵Medicina Estetica e Microchirurgia, Milano

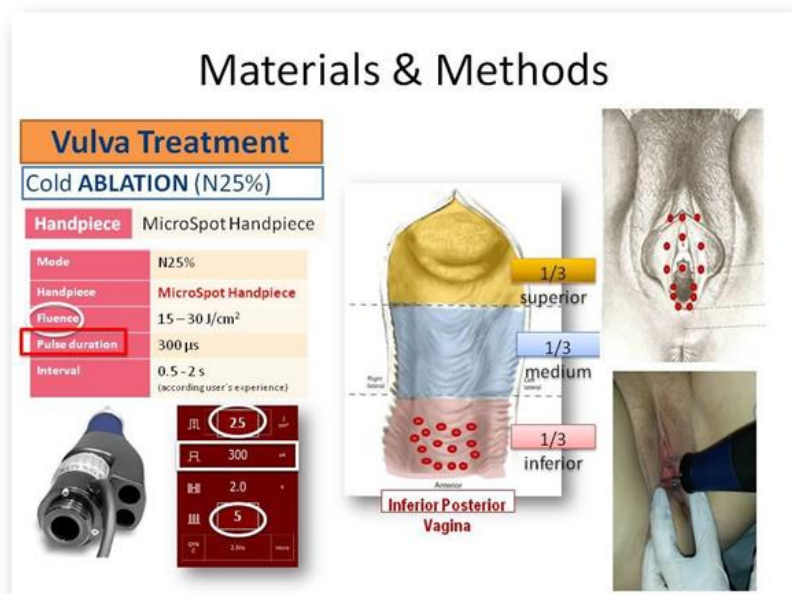Objectives

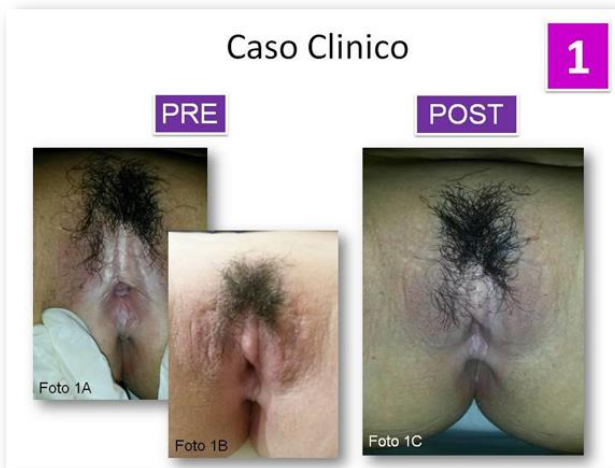Vulval lichen sclerosus (LS) is a chronic and progressive inflammatory disease of the mucosa and skin affecting the genital region. Its cause has not yet been fully identified, but several studies have shown how autoimmune mechanisms play a key role in terms of the pathogenesis of the condition. Many patients with vulval LS respond reasonably well to treatment with topical corticosteroids, and experience a clinical improvement, as well as an improvement in the histology of their condition and its symptoms. There is still much discussion about the long-term effects of applying topical corticosteroids for long periods of time due to their side effects which include, atrophy, a rebound effect when their use is stopped, fungal infections, recurrence of related HPV infections, and systemic absorption. CO2 laser treatment has been shown to be effective in producing a significant improvement in post-menopausal vulvovaginal atrophy. The purpose of this study is to assess the efficacy and safety of Erbium laser treatment on vulval LS. Erbium laser technology is widely used in other areas of the body and is capable of ablating tissue whilst transferring less heat thereto, compared to the CO2 laser. It could therefore be deemed a valid option as a non-invasive treatment type. As part of this study we have assessed the short-term efficacy and acceptability of the Erbium vaginal laser as a new option for second-generation ablation therapy in treating vulval LS.

Materials and Methods

2 Caucasian patients with an established diagnosis of vulval LS made over 5 years ago, who have already undergone repeated topical treatments having a temporary effect on their condition (topical cycles of cortisone at high-doses combined with creams that stimulate the skin to return it to a normal, healthy state, PRP injections at a rate of 2 treatments per year, Placentex injections, delivery of substances that return the skin to a normal, healthy state via electroporation) and with persisting lesions and symptoms (genital itching, dryness around the entrance to the vagina and dyspareunia, recurrence 3 months after stopping treatment), were recruited for vulvar application using laser treatment for gynaecology. We used an Erbium laser which emits longwave radiation equal to 2,940 nm (chromophore: water) with a microspot manipulator (169 microcolumns) over a surface area of 13 x 13 mm with a

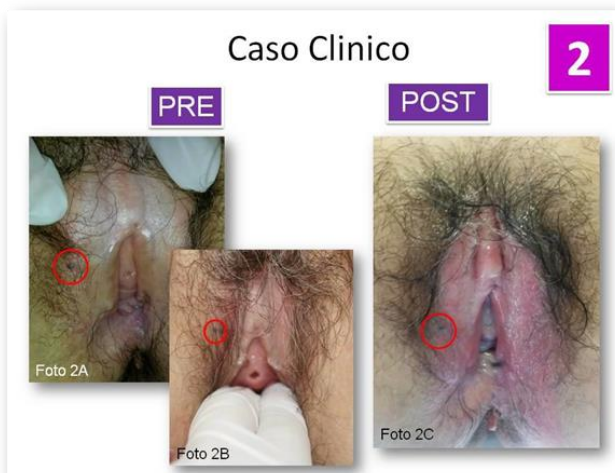fluence of 25 J/cm² and an impulse time of 300 ms. Each patient underwent two treatments two weeks apart, with application of the laser over the entire surface area of the external genitals (the labia majora and labia minora, the frenulum and clitoral hood, the vulval vestibule). At the time of recruitment all symptoms were assessed with a score (from 0 to 10). Atrophy was assessed using a clinical point system (from 0=absent to 4=severe). The same assessment was conducted at follow-up after 3-4-5 months. This is a preliminary, prospective, open-label, uncontrolled study.





Clinical Case 1:

33 years old. Vulvoscopy: extensive whitish plaque of cutaneous sclerosis of the upper third of the vulva covering the clitoral hood, complete resorption of the labia minora, severe narrowing of the entrance to the vulva (PHOTO 1A) and slight resorption of the adipose tissue of the labia majora (PHOTO 1B).



Clinical case 2:

55 years old. Vulvoscopy: extensive white/off-white plaque of atrophy covering the whole vulva with significant distortion of the anatomy (resorption of the labia minora and covering of the clitoral hood) (PHOTO 2A) and gradual narrowing of the entrance to the vagina (PHOTO 2B) for which she previously underwent vulvovaginoplasty involving the posterior labial commissure due to stenosis of the entrance to the vulva and anterior prolapse of the vagina.

Results

Clinical Case 1:

Outcome (PHOTO 1C): halted disease progression, volume of the labia majora partially restored, symptoms totally disappeared and not returned even 5 months after the treatment.

Clinical Case 2:

Outcome (PHOTO 2C): halted disease progression, symptoms totally disappeared and not returned even 5 months after the treatment.

Vulval symptoms:

- dryness of the entrance to the vagina and, especially dyspareunia, significantly improved quickly and permanently.
- itching was well-controlled [after the procedure].

From a clinical point of view, an improvement in the overall condition of the cutaneous tissue and mucosa of the vulva was observed.

Conclusions

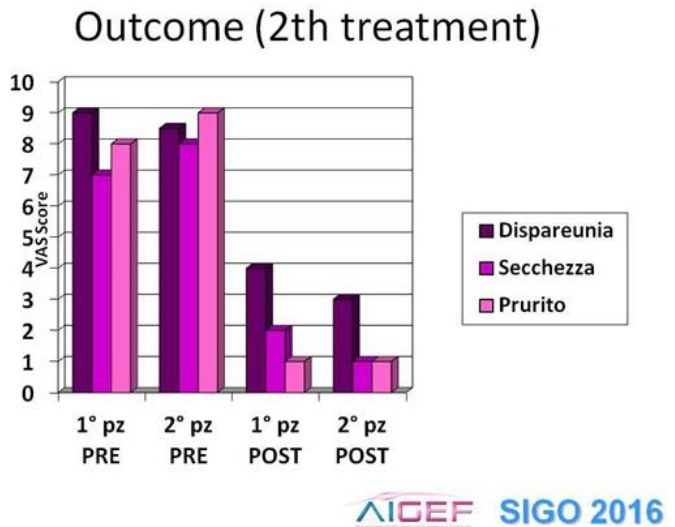
The data obtained concerning the efficacy of the Erbium laser in treating vulvovaginal symptoms such as dryness, itching and, especially, dyspareunia, are encouraging. The efficacy of this technology in treating the symptoms of vulval LS is said to be connected to its ability to limit the progression of the disease by means of positive stimulation at the level of the dermoepidermal junction, producing an increase in the depth of the dermal papillae, neocollagenesis and neoangiogenesis.

This beneficial action of the Erbium laser led to the disappearance of symptoms and halted the progression of the disease with a clinical improvement lasting to date, 5 months after the treatment.

Clearly more clinical studies involving a larger number of patients and control groups treated with a placebo or with alternative treatments as a means of comparison (CO₂, corticosteroids etc.), must be conducted in order to better define the efficacy of this technology in treating vulva LS. Topical steroid treatment remains to date the gold standard in treatment for vulval LS due to its ability to alleviate the symptoms of the condition shortly after its first application. Emollient creams should be used in association with corticosteroids to support the pharmacological treatment. Further studies are needed to clarify the role of the Erbium laser in treating vulval LS. This technology could be considered as an alternative treatment for those patients for whom the use of ultrapotent corticosteroids has not been successful and for those patients for whom the use of steroid medications is contraindicated.

References

1. Anglana F, Lippa P, Ronca S, Caussade A. Atlas of Vulvar Dermatoses and Dermatitis. CIC Editore [Published], 2015 Edition.
2. Bradford J, Fischer G. Long-term management of vulval lichen sclerosis in adult women. *Aust N Z J Obstet Gynaecol.* 2010;50:148–152.
3. Salvatore S, Nappi RE, Zerbinati N, et al. A 12-week treatment with fractional CO₂ laser for vulvovaginal atrophy: a pilot study. *Climacteric.* 2014;17:363–9.



4. Gambacciani M, Levancini M, Cervigni M. Vaginal erbium laser: the second-generation thermotherapy for the genitourinary syndrome of menopause. *Climacteric.* 2015 Oct; 18(5):757-63.
5. Virgili A, Corazza M, Minghetti S, Borghi A. Growing evidence for topical mometasone fuoroate in the treatment of Vulvar Lichen Slerosus. *Maturitas.* 2015 Jan; 80(1):113

A minimally invasive treatment method for lichen sclerosis

Ye. V. Leshunov

Urologist and andrologist at the Clinic of Professor Yutskovskaya (Moscow), Department of Urology IPK FMBA Russia.

I. V. Kvach

Gynaecologist and endocrinologist at the Clinic of Professor Yutskovskaya (Moscow).

Professor Ya. A. Yutskovskaya, M.D.

Head of the Department of Dermatovenerology and Cosmetology at the GBOU VPO Pacific State Medical University of the Ministry of Healthcare of the Russian Federation, Director of the Yutskovskaya Professorial Clinic (Vladivostok) and the Clinic of Professor Yutskovskaya (Moscow).

Abstract

Described below is a contemporary, minimally invasive treatment method for lichen sclerosis using an erbium laser and PRP. A prospective study was conducted on the efficacy and safety of the proposed method. The clinical case is discussed below.

Introduction

According to the WHO, it is expected that 46% of all women will be over 45 years old by 2015^[1]. There has been a noticeable growth in the number of patients with dystrophic diseases of the vulva, including in children and women of reproductive age, as a result of a change in the population of contemporary society in recent years. Atrophic changes to the tissues of the external sex organs often have severe clinical manifestations and are accompanied by neuropsychiatric disorders, which significantly decrease the woman's quality of life^[2]. Atrophic lichen sclerosis, or kraurosis, was first described at the end of the 19th century, and interest in the disease has increased during the past several decades^[3]. An increase in the number of patients with dystrophic diseases of the vulva has been noted all over the world. In the past this pathology was mainly found in women of climacteric and postmenopausal age, whereas at present atrophic lichen sclerosis is also diagnosed in children and women of reproductive age^[4]. Little attention is paid to this problem in the literature at the present time. Studies of the aetiology and pathogenesis of atrophic lichen sclerosis, which still remain largely unknown, are few and far between^[5].

Lichen sclerosis and leukoplakia have a persistent and progressive clinical course and are accompanied by a painful and, at times, unbearable itch, which troubles patients almost constantly, is exacerbated by the smallest contact with clothing and is poorly alleviated by medications. In the end, the itch causes emotional disorders and disrupts social relationships. According to M. I. Shtemberg^[6], every second patient experiences psychoemotional disorders even in the early stages of disease. This undoubtedly affects their quality of life. In this context, it would be expedient to assess the efficacy of medical intervention not only according to clinical data, but also taking into account changes in the indices of these patients' quality of life. In our country [Russia], however, no study of the quality of life of patients with dystrophic diseases of the vulva has been conducted. Naturally, there are no methods available for assessing such data.

The problem of treating lichen sclerosis and leukoplakia remains topical due to the low efficacy of existing treatment methods, the duration of the disease, the severity of its course and the likelihood of malignancy^[7]. Despite the wide spectrum of standard treatment used for this pathology, efficacy remains relatively low. The existing standard methods reduce the painful symptoms of the itch of the external sex organs, but do not ensure complete elimination of localised morphological manifestations of the disease or provide prolonged remission, and require ongoing treatment. In addition, the long-term standard therapy for lichen sclerosis and leukoplakia of the vulva does not prevent the development of cancer. And so, according to data collected by Ya. V. Bokhman et al.,^[8] 30% of patients with cancer of the vulva were observed and received the standard treatment for leukoplakia.

In comparison with the traditional standard treatment of lichen sclerosus and leukoplakia of the vulva, laser therapy is significantly more efficacious but does not guarantee permanent results. The recurrence of the process prescribes the need for repeated courses of therapy and the use of more radical treatment methods. At present, laser surgery occupies a key position among the most radical surgical methods for treating gynaecological patients. Laser treatment offers high accuracy, minimal damage to healthy tissue, exsanguinity, a painless operation and does not result in the formation of coarse scars and stenosis^[9].

Past research demonstrates the efficacy of using CO₂ lasers in the treatment of patients with lichen sclerosus. However, the likelihood of a relapse, the long rehabilitation period and the possibility of complications mean that it is not possible to use this procedure on everyone. Data analysis of existing literature on this subject suggests that the limitations of CO₂ lasers are primarily connected to the properties of the laser itself, its depth of penetration (200 µm) and its pronounced thermal effect. At Professor Yutskovskaya's Clinic we use the latest generation Er:YAG laser. The erbium (Er:YAG) laser has an emission wavelength of 2.94 µm (average IR range). It uses a pulse operation mode. The depth of penetration by the erbium laser emission into the biological tissue does not exceed 0.05 mm (50 µm).

CO₂ and erbium lasers differ significantly. They share a single operating principle based on the phenomenon of selective photothermolysis. The main difference between Er:YAG and CO₂ lasers lies in the power of the laser generator. The peak power of the short pulsed solid-state Er:YAG laser reaches 20 kilowatts, whereas the peak power of the pulse of a CO₂ laser reaches 50 watts. As a result, the Er:YAG laser requires either increased pulse duration or repeated pulses on the same area to achieve the necessary ablative depth. The CO₂ laser causes a significant rise in the temperature of the tissue. As a consequence an ablation zone forms, surrounded by a zone of irreversible thermal necrosis and a wider zone of coagulation damage due to heat transfer in the tissues.

The depth of penetration of the energy from a CO₂ laser always exceeds the depth of formation of the basal lamina and it is always accompanied by an additional zone (from 10 to 50-60 mcm) of coagulation damage that is lower than the level of ablation. The high depth of penetration and significant thermal damage limit the number of procedure pathways to two.

Patient supervision after laser treatment is a pressing problem given that in 30% of patients the vulval itch and pain during sex remains following use of the CO₂ laser and the rehabilitation period lasts at least 9 days.

One particularly promising achievement in general and regenerative medicine is the use of growth factors for accelerating regenerative processes at the wound site. Thrombocytes are the most convenient source from which to obtain autogenous growth factors^[10]. These factors are all contained in the alpha granules of thrombocytes. This includes platelet-derived growth factor (PDGF), two types of transforming growth factor beta (TGF-beta 1, 2), insulin-like growth factor (IGF), epidermal growth factor (EGF), fibroblast growth factor (FGF), endothelial growth factor, anti-heparin factor and platelet-activating factor^[11]. The autogenous platelet-derived mass promotes the formation of collagen, accelerates regeneration of the skin and mucus, stimulates vessel growth and the rapid and essential formation of connective tissue, ensures haemostasis, alleviates pain, decreases the risk of infectious complications, helps attain the best result of the surgical procedure and prevents postoperative complications. A new method was tested to optimise the therapy of patients with lichen sclerosus using an Er:YAG laser in conjunction with PRP.

Materials and methods

38 women aged between 18 and 63 years (average age: 56.2) participated in the study. The study complied with all the rules of the GCP Protocol and did not contravene the Declaration of Helsinki.

Each patient included in the study was examined by a GP and gynaecologist. The inclusion criteria for the study was a histologically verified diagnosis of lichen sclerosus, normal cytology (Pap smear), a negative urine culture, the absence of acute somatic diseases and the verified diagnosis of mild and moderate stress incontinence.

The exclusion criteria was pregnancy, lactation, taking photosensitive drugs, injury and/or active infection at the treatment site, diagnosed vaginal haemorrhages and active menstruation.

The laser treatment for lichen sclerosus used the 6th generation Asclepion MCL 31 Er:YAG 2,940 nm erbium laser.

The procedure was carried out under outpatient conditions using the infiltration anaesthesia Ubistesin. During the first stage the area of the vulva affected by lichen sclerosus was treated with ablation, and during the second stage an intradermal injection was given prior to the prepared PRP.

After the procedure, the vulva was treated with an aqueous chlorhexidine solution for the expulsion of the tissue detritus. Abstinence from sex was set at 72 hours. Topical antiseptics were used to prevent infectious complications. In the case of a medical history of genital herpes, a standard dose of valaciclovir was given as a prophylactic three days before and after the procedure. Patients were able to return to normal activity on the same day.

Results

The patients included in the study received two laser treatment procedures for lichen sclerosus in conjunction with PRP with a 1 month interval. The procedure was concluded without complications during the pre and postoperative periods. Patients did not experience pain or discomfort during the procedure.

Three fixed intervals were determined to assess clinical efficacy: before the procedure, 1 month after and 6 months after the procedure. In the initial check-up 1 month after the procedure, 32 patients (85%) had been completely cured of all symptoms of lichen sclerosus and insignificant morphological manifestations remained in 6 patients (15%).

After 6 months, 30 patients (78%) exhibited no manifestations of lichen sclerosus and 8 patients (22%) exhibited weak symptoms, which they considered insignificant.

A modified questionnaire SF-36 Health Status Survey (SF-36) was used to assess quality of life before and after treatment. The aim of the questionnaire on the quality of life for women with lichen sclerosus was to assess not only the medical efficacy of the treatment, but also the change in the patient's quality of life (their physical activity, mental state, social, sexual and other role functions, and a subjective health assessment) before and after the treatment.

The heading 'Before treatment' refers to the patient's feelings from the onset of the disease until treatment. The heading 'After treatment' included two stages: 1 and 6 months after the treatment. The results of the assessment shown in Table 1 facilitated the optimisation of the treatment method used.

SF36	Before the procedure	After 1 month	After 6 months
PF	54.4±12.0	65.2±11.6	84.7±14.7**
RP	39.1±18.8	53.3±15.4*	79.3±15.5**
BP	52.3±12.1	70.1±11.6*	81.0±15.1**
GH	54.8±9.6	73.0±9.3*	84.8±14.2**
VT	41.6±11.6	62.4±10.6	75.3±12.2**
SF	65.5±9.8	66.7±10.1	74.7±10.1*
RE	40.2±18.1	62.7±11.8	87.9±15.8**
MH	43.6±9.8	58.5±9.4*	78.8±10.7**

Table 1. The changes in the parameters of quality of life according to questionnaire SF-36. Note: * - $p < 0.05$, ** - $p < 0.01$ (compared with 'Before the procedure')

As can be seen from the results shown in Table 1, a reliable positive trend was recorded after 1 month according to the following indices of the SF-36 scale: RP, BP, GH, and MH. A distinct positive trend after 6 months with a high level of validity ($p < 0.01$) is noted across all indices of the SF-36 scale, with the exception of SF. After 6 months, levels are indicative of a reasonably high quality of life observed across all the quality of life indices.

Objectifying the patient's feelings via the quality of life assessment enables a complete analysis of the results of the treatment given. This study demonstrates positive changes in the quality of life of patients with lichen sclerosus and an improvement in both the mental and physical elements.

No complications were noted during the postoperative period. The safety of this method is demonstrated by the absence of inflammatory changes and reactions, which represents an advantage over the other known methods.

Treatment of lichen sclerosus using an erbium laser in conjunction with PRP is a contemporary, minimally invasive treatment method with a high efficacy and safety profile.

Clinical case

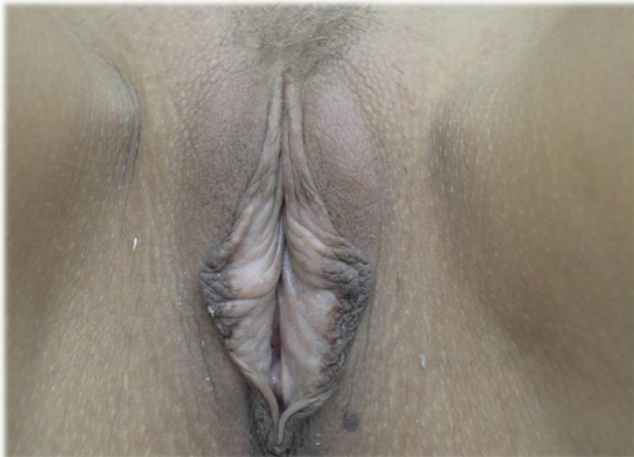

Fig. 1. Lichen sclerosus. The labia minora are diffusely altered.

The patient was 31 years old. She came to Professor Yutskovskaya's LLC Clinic complaining of itching of the vulva, changes to the exterior appearance of the vulva and pain during sexual intercourse. She had never before broached this issue with her gynaecologist, who had administered treatment without success. She was examined at the clinic by specialists in gynaecology, urology and dermatovenerology. Taking into account the medical history of disease and the clinical presentation, advanced lichen sclerosus was diagnosed (Fig. 1).

A biopsy of the vulva was taken which confirmed the diagnosis. Some thickening of the horny and Malpighian layers of the epidermis was noted in addition to areas of parakeratosis. Inflammatory and atrophic changes in the derma were noted in the elastin, which was observed only in small fragments and twisted fibres, and the collagen, which was shown to be sclerosal.

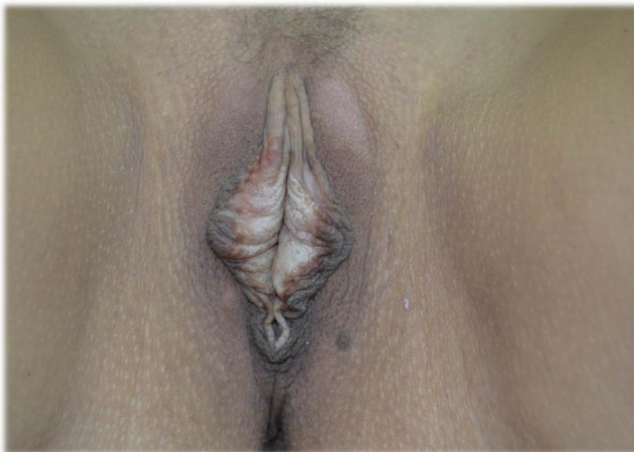

Fig. 2A. View of the vulva immediately after laser destruction.

We decided to conduct treatment using an erbium laser in conjunction with PRP. The method of laser treatment using cold ablation (a pulse duration of 100 ms and a pulse density of 3 J/cm²) enables careful removal of the dysfunctional layer without causing a build-up of heat in the underlying structures (Fig. 2A).

Plasmolifting tubes were used to prepare the PRP. The PRP injections were administered using a mesotherapeutic technique with a 30G needle immediately after the use of the laser (Fig. 2B).

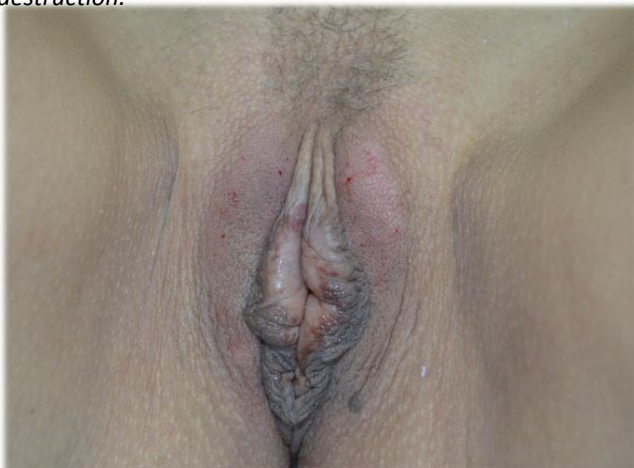

Fig. 2B. View of the vulva after injection with PRP

1 week after the initial procedure the patient noticed changes. The intensity of the itching of the vulva was considerably reduced. Touch sensitivity in the labia minora developed. Discharge from the scab and areas of epithelisation (clear mucus) were visible upon examination (Fig. 3).

We decided to continue treatment. Cold fractional laser grinding was administered (with a pulse duration of 100 ms and a pulse density of 15 J/sm²) in conjunction with PRP injections (Fig. 4A,B).

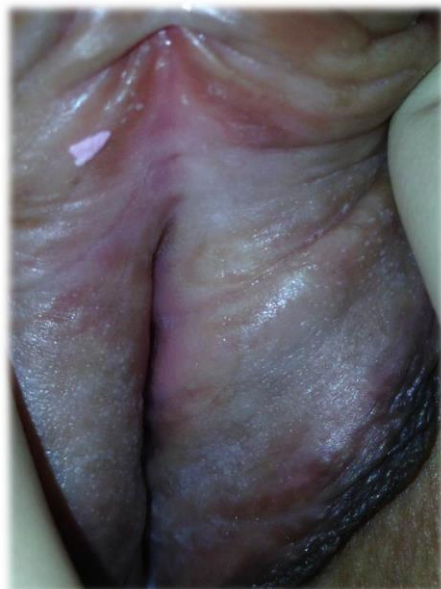

Fig. 3. Condition 1 week after the initial procedure.

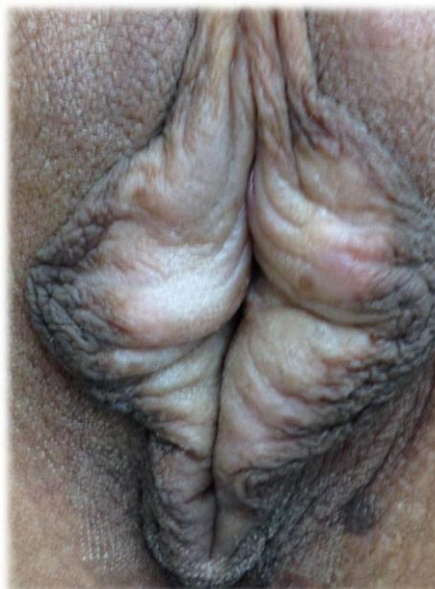

Fig. 4A. Condition after fractional laser destruction.

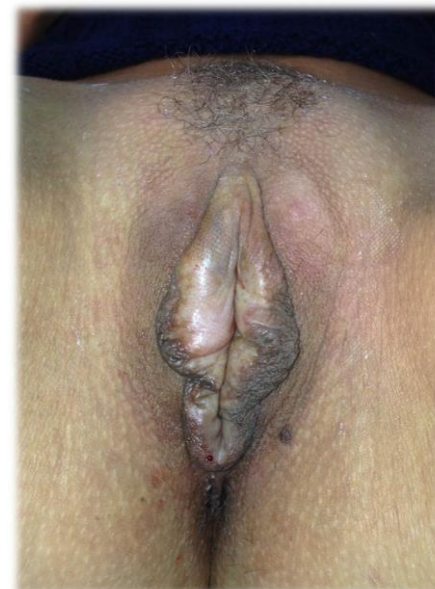

Fig. 4B. Condition after PRP injections.

Complete clinical remission was achieved 1 month after the initial procedure. The patient received two laser treatments in conjunction with PRP. The interval between procedures was 1 month. There were no complications during the pre and postoperative period. The patient did not have any further complaints after 6 months. Mucus was bright pink in colour without changes or sites of hyperkeratosis upon examination (Fig. 5).

Both doctor and patient consider the results of these procedures to be outstanding. The results demonstrate the high efficacy of laser treatment for lichen sclerosus in conjunction with PRP injection. The participants in the study have no material incentive and are in no way affiliated with the manufacturer. Ye.V. Leshunov acted as external consultant to the company Asclepion due to his experience of working with the MCL 31 laser apparatus.

References

1. Баранов И. И., В.Н. Серов. Климактоплан в терапии климактерического синдрома // Русский Медицинский журнал.- 2005.-№1.-С.11-14.
2. Паллади Г.А., Штемберг М.И., Яковлева И.А. Крауроз и лейкоплакия вульвы // Акушерство и гинекология ,1977. -№2. С. 61-64.
3. Levis F.M. Vulva disease from the 1800s to the new millennium / Levis F.M. // J. Cutan. Med. Surg. 2002. - V. 6, № 4. - P. - 340-344.
4. Башкирова А.А. Лечение дистрофических процессов вульвы у девочек и девочек-подростков//Здравоохранение Башкортостана.-2000.-№2.-С. 131-133.
5. Powell J.J. Childhood vulvar lichen sclerosus : an increasingly common problem / Powell J J., Wojnarowska F. // J. Am. Acad. Dermatol. 2001. - V. 44, №5.-P. 803-806.
6. Штемберг М.И. Комплексная патогенетическая терапия крауроза и лейкоплакии вульвы / Штемберг М.И., Шендерова Т.С. // Здравоохранение (Кишинев). 1980. - № 4. - С. 10-12.Маркина Е.И. // Роль инфекционных факторов и гормональных нарушений в генезе дистрофических заболеваний вульвы и их комплексное лечение // Автореф. дисс. канд. мед. наук. Москва, 2003г. -24с.
7. Бохман Я.В. Руководство по онкогинекологии // Ленинград. Медицина.1989. С. 464
8. Бронештер Д.Ш. Лечение дистрофических процессов вульвы с помощью ИК лазерного излучения.: Дисс. канд. мед. наук.// ММА им. И.М.Сеченова. -Москва, 1991.- 106с
9. Marx R. Platelet-rich plasma (PRP): what is PRP and what is not PRP? // Implant dentistry Vol. 10 №4 2001 pg. 121-125.
10. Marx R., Carlson T., Eichstaedt R., Schimmele S., Struss J. Platelet-rich plasma : growth factor enhancement for bone grafts // Oral Surgery, Oral Medicine, Oral Pathology Vol 85 № 6 June 1998 6438-6446.

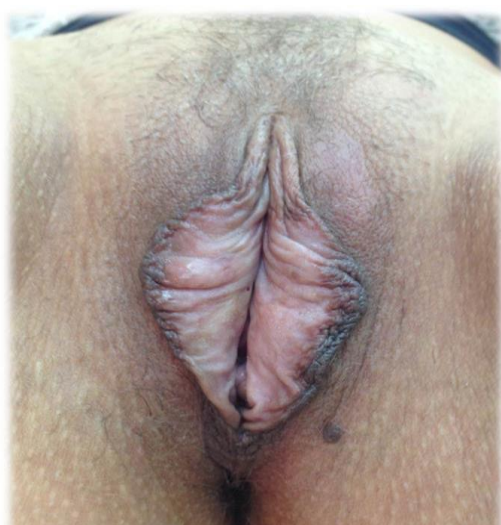


Fig. 5. 6 months after the initial procedure. Note the complete ablation of the mucus. Mucus is bright pink in colour and there are no signs of inflammation.

AESTHETIC GYNECOLOGY & VAGINAL RELAXATION SYNDROME

Fractional Erbium Laser for Vaginal Rejuvenation

Female Cosmetic Genital Surgery- Concepts, classification and techniques. 2017 (1)256-264

Christine A Hamori, Paul E. Banwell, Red Alinsod

E.V. Leshunov

Doctor, urologist, Urology Department, GBOU DPO "Institute for Advanced Studies FMBA, Russia¹

e-mail: leshunov@bk.ru

Key Points

- Er:YAG 2940 nm is one of the most popular systems for laser vaginal rejuvenation in the world.
- This technology has been used to treat the syndrome of vaginal relaxation, stress urinary incontinence, and vaginal atrophy.
- Fractional vaginal rejuvenation is a simple outpatient procedure that requires no anesthesia.
- The rehabilitation period after vaginal rejuvenation with the use of an erbium laser is 72 hours.

Fractional Er:YAG systems with a dedicated gynecological delivery system recently became commercially available.

Er:YAG systems offer a nonsurgical approach for vaginal tightening. Erbium laser technology is used for treating vaginal laxity, stress urinary incontinence, pelvic organ prolapsed, and vaginal atrophy. The first trials for erbium tightening of the vaginal canal began in 2008 and 2009. [1]

From 2010 to 2014 several clinical studies invoking all four indications were conducted to prove the efficacy and safety of this novel technology. The infrared erbium (Er:YAG) laser has an emission wavelength of 2.94 μ m and operates in pulse mode. The main mechanism of action of the laser technology is selective stimulation of the submucosal (lamina propria) collagen synthesis and thermal stimulation of mucosal tissue. The instantaneous reaction of contraction in the collagen fibers and acceleration of neocollagenesis lead to the contraction of tissues and an increase in their elasticity.

The choice of the Er:YAG with its 2940 nm wavelength for this gynecological probe-based system was predicated on the absorption peak of water at that wavelength. Human tissues are a good target for this wavelength because of their very high percentage of water, especially in the vaginal area where mucous membranes are present and in the lamina propria (submucosal area). Because of the extremely high absorption in water, the incident photon energy is almost totally quenched in the first micrometers of tissue, producing at appropriate parameters a very controlled column of thermal stimulation with an extremely narrow band of secondary coagulation, known as *residual thermal damage*. [2]

Collagen is an important component of pelvic floor supportive structures—it makes up more than 80% of the protein content of the endopelvic fascia. Collagen provides tensile strength and integrity, and elastin is responsible for the elasticity and resilience of the connective tissue of the pelvic floor. The extracellular matrix of the vaginal wall consists of collagen type I, III, and V. The ratio of collagen type I/type III determines the mechanical properties of the vaginal wall. A change in the ratio toward collagen type III, which is most frequently observed in vaginal prolapse and stress incontinence, can significantly reduce the elasticity of the vaginal wall. Collagen type V is an important component of basement membranes. Changes in the condition of this collagen are very rare. Elastin helps to provide support to the pelvic floor. With age, decreased elastin in the extracellular matrix causes a loss of submucosal supporting function of the vaginal wall. [3]

Pelvic tissue from women with stress urinary incontinence and pelvic organ prolapse shows a genetic predisposition to abnormal extracellular matrix remodeling, which is modulated by reproductive hormones, trauma, mechanical stress load, and aging. This progressive remodeling contributes to stress urinary incontinence and pelvic organ prolapse by altering normal tissue architecture and mechanical properties. Laser-mediated mechanical and heat pulsing of the endopelvic fascia and pelvic floor tissue could be effective nonsurgical method for treating female urinary incontinence and other disorders resulting from diminished pelvic floor support.

¹ Postgraduate training institute, Russian Federal Biomedical Agency, state-funded supplementary vocational education institution

Collagen that undergoes appropriate mechanical (ablative) and/or thermal microdamage is regenerated, resulting in more elasticity, tightening in the sudden contraction of its fibers, and contraction and shrinking of the irradiated bulk tissue. [4] The result is a better response by muscular tissue in the pelvic floor.

Dr. Rodolfo Milani conducted a pilot study at the University of Milano-Bicocca, San Gerardo Hospital in Monza Italy, to evaluate the safety and efficacy of a novel treatment protocol for vaginal rejuvenation using Er:YAG. Forty-seven patients received treatment for vaginal atrophy between December 2015 and April 2016. The average patient age was 55 years. Every 2 weeks, patients underwent a vaginal atrophy assessment (speculum examination and vaginal pH) and completed questionnaires on atrophy symptoms and quality of life (Utian Quality of Life [UQOL] Scale). [5]

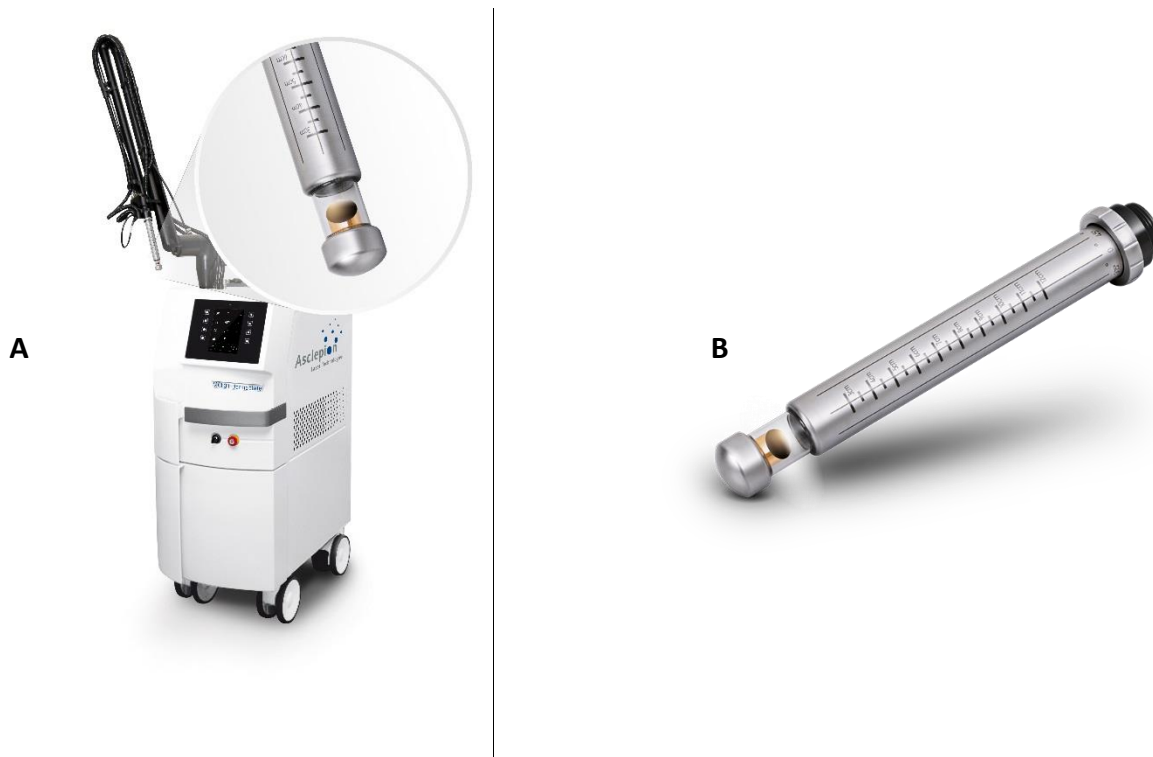


Fig. 17-1 A, MCL31 Dermablase (Er:YAG 2940 nm). B, Juliet vaginal probe

At baseline and after 6 weeks, a Pap smear with a maturation index was performed and a vaginal biopsy sample cultured. The laser system used was the MCL31™ Er:YAG (Asclepion Laser Technologies), delivering a wavelength of 2940 nm (Fig. 17-1). When fitted with the dedicated vaginal probe (Juliet™ Asclepion Laser Technologies), the laser can be operated in the multiple micropulse mode (pulse width of 300 μs, selectable number of pulses in burst) and in the long-pulsed thermal mode (1000 μs, single pulse). The protocol called for one treatment session.

Punch biopsies were performed at baseline and at day 7 after treatment, formalin fixed, and routinely prepared for light microscopy with hematoxylin and eosin staining and two-photon microscopy. All subjects completed the treatment and the 3-month assessment. All patients were aware of a heating sensation in the vagina during treatment. None reported major or lasting adverse effects after treatment.

Results

All women had a significant reduction in vaginal pH from 6.5 to 7 (± 0.3) to 4.5 (± 0.3). pH is one of the most important and sensitive means of evaluating the functional state of vaginal mucosa. A pH change toward alkalinity disrupts the vaginal flora and reduces the mucosal barrier function. The use of laser light changes the trophic properties of tissue. It increases blood circulation lubrication, and the level of glycosaminoglycans, promoting considerable reduction of pH and restoration of normal vaginal biocenosis.

All patients reported a subjective improvement in all symptoms of vaginal atrophy.

The vaginal maturation index (VMI) improved: Parabasal cells were 100% at entry and 33% after 6 weeks of treatment, intermediate cells changed from 0% to 40%, and superficial cells changed from 0% to 27%. The VMI is a ratio obtained by performing a random cell count of the three major cell types shed from the vaginal squamous epithelium: parabasal, intermediate, and superficial. It is reported as relative percentages of these cells and written as a ratio (parabasal %:intermediate %:superficial %).

The VMI is thought to show the effect of estrogen on the vaginal mucosa (not the cervix). Parabasal cells are not affected by estrogen and progesterone, because they are immature cells; intermediate cells are somewhat mature, having been affected by progesterone; and superficial cells are the most mature, having been affected by estrogen. A large percentage of parabasal cells can indicate a lack of estrogen affecting the tissues. A large percentage of superficial cells indicates that a lot of estrogenic stimulation has occurred. Intermediate cells have no value here. VMI numbers are interpreted as follows: 49 or less indicates not very much, or zero, estrogenic effect; 50 to 64 indicates a moderate estrogenic effect; and 65 to 100 indicates a dominant, fertile (premenopausal), estrogenic environment.

Because we can see improvement in the trophism of the mucosa and submucosa with the use of Er:YAG, we decided to evaluate the changes of this index before and after treatment. We noted a significant improvement in the index, which returned to premenopausal levels after two laser treatment procedures.

Patients reported a significant improvement in their UQOL score, including the sexual domain of the scale. [5] The histologic findings in general showed evidence of a thicker and more cellular epithelium and a more compact lamina propria with a denser arrangement of connective tissue, as shown in Figs. 17-2 and 17-3.

The results of the histologic analysis suggested tightening and firming of the vaginal wall.

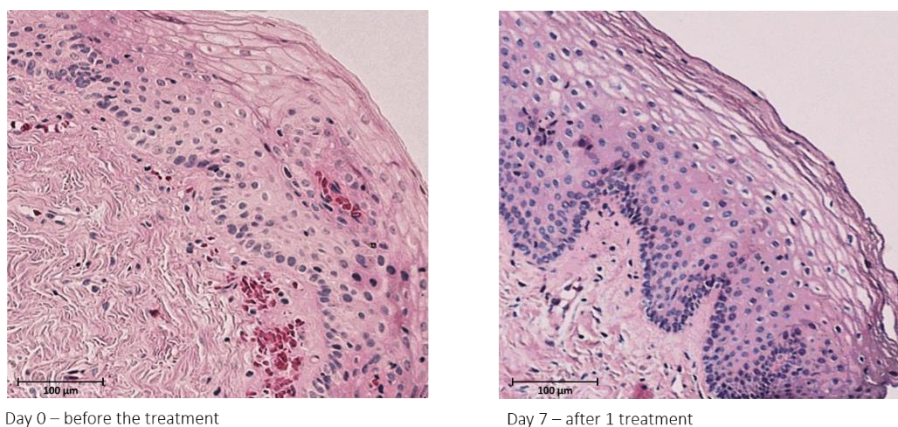
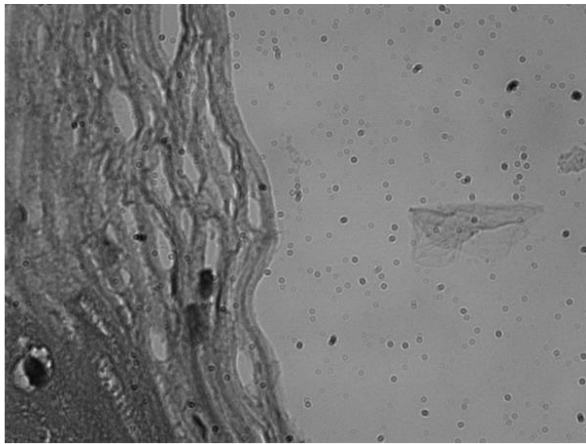
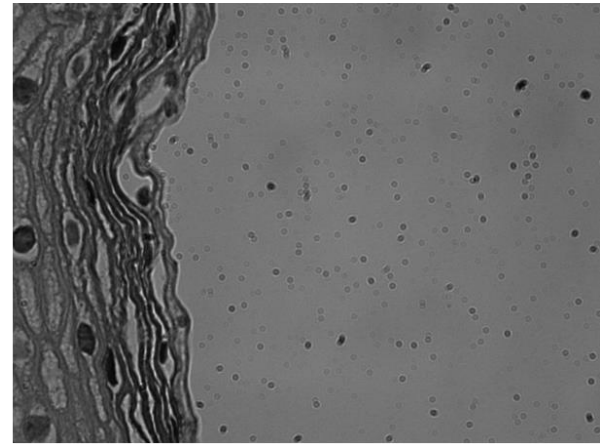


Fig. 17-2 Hematoxylin and eosin—stained specimens of the vaginal wall. A, Baseline sample. B, Seven days after treatment, mucosal architecture is improved in the epithelium and the lamina propria



Day 0 – before the treatment



Day 7 – after 1 treatment

Fig. 17-3: Photon microscopy images of the vaginal wall. A, at baseline, the epithelium was split, with few and pyknotic nuclei. B, seven days after treatment, the epithelium is multilayered and well organized with nuclei present.

Conclusions

The preliminary results of our study confirm that a minimally invasive, fractional laser treatment with short- and long-pulse Er:YAG is an effective, safe, and comfortable treatment option for vaginal rejuvenation in patients with vaginal atrophy.

All patients have subjective improvement in their sex life because of improved vaginal lubrication, more sensation during intercourse because of tightening, and more elasticity. Incontinence symptoms are eliminated or significantly reduced.

Changing the ratio of different types of collagen and elastin increases the mechanical properties, significantly altering the vaginal wall; specifically, it reduces its elasticity. Because the anterior vaginal wall acts as a support for the urethra and muscular lacunar tissue, loss of function leads to hypermobility of the urethra tissue and bladder neck, which manifests as stress urinary incontinence (stress from changes in intraabdominal pressure).

The use of laser energy leads to remodeling of the extracellular matrix and fibroblasts and activation of the vaginal tissue, improving the supporting properties of the vaginal wall. The increased elasticity in the vaginal wall is evaluated subjectively using a Visual Analog Scale and may not be assessed objectively.

References

- I. Vizintin Z, Rivera M, Fiston4 1, et al. Novel minimally invasive VSP Er:YAG laser treatments in gynecology. *J Laser Health Acad* 1:46,2012.
- Lee MS. Treatment of vaginal relaxation syndrome with an erbium:YAG laser using 900 and 360° scanning scopes: a pilot study & short-term results. *User Ther* 23:129, 2014.
- Meijerink AM. Tissue composition of the vaginal wall in women with pelvic organ prolapse, *Gynecol Obstet Invest* 75:21, 2013.
- Bezmenko AA, Schmidt AA, Koval M. et al. Morphological substantiation of applying the Er:YAG laser for the treatment of stress urinary incontinence in women. *J Obstet Women Dis* 3:88, 2014.
- Utian quality of life scale (UQOL). Available at <https://www.menopause.org/docs/default-document-library/uqol.pdf?sfvrsn=2>

Female intimate surgery: review of methods and trends

Plastic surgery and cosmetology. 2014 (2)161-320

Ya.A. Yutskovskaia

Doctor of Medical Sciences, Professor, Head of Dermatovenerology and Cosmetology Department, GBOU VPO "TGMU MinzdravaRossii"², Director, Yutskovskii Professorial Clinic³ (Vladivostok) and Professor Yutskovskaia's Clinic⁴ (Moscow)
e-mail: yutsk@mail.ru

E.V. Leshunov

Doctor, urologist, Urology Department, GBOU DPO "Institute for Advanced Studies FMBA, Russia"⁵
e-mail: leshunov@bk.ru

V.D.Trufanov

Plastic surgeon, Department of Surgical Dentistry and Maxillofacial Surgery, FGBOU VPO "RUDN"⁶, Full Member of the New York Academy of Sciences and of the International American Academy of Sciences for Radiowave Surgery

Abstract (as provided in the Russian publication)

The work presents the review of the present literary data on the history, methods and tendencies of development of female intimate surgery. The methods of performance of the procedures are described considering the reports of surgeries made in the clinic of Prof. Yutskovskaia.

1. INTRODUCTION

Procedures aimed at correcting appearance and restoring functions that are carried out in the female urogenital area are customarily referred to as intimate plastic surgery (IPS). This surgery includes traditional methods of correcting vaginal prolapse and looseness of the vaginal vestibule, and also aesthetic correction of the vulva. The boundary between medical and aesthetic indications for the performance of procedures is blurred, and nowadays many operations are carried out with both objectives in mind.

A major contribution to the development of this sphere in the world is provided by cooperation between gynaecologists, urogynaecologists and reconstructive surgeons. Unfortunately in Russia we see a complete lack of mutual understanding between specialists engaging in "sexual medicine", so that it is not possible to talk of the quality of the results of intimate plastic surgery or of sexual wellbeing as a whole. At the first interview with a prospective patient, a gynaecologist or surgeon should be able to provide a patient, who is looking to have intimate plastic surgery with a full and informed explanation concerning all the options and the potential for correction in the urogenital area. The patient should, in addition, be examined by a psychologist to check for dysmorphophobia. It is important to be sure that the woman is taking the decision independently, without any coercion or pressure from her sexual partner.

Historical information

The previous history of female intimate surgery is associated with genital surgery – ritual manipulations that date back deep into antiquity and have distinct ethnic characteristics. Some approaches and methods used in modern-day sexual surgery have, however, been assimilated specifically from these rituals. One particular aspect of this surgery is that operative intervention is, in a number of cases, carried out not because of medical indications, but in connection with the patient's dissatisfaction with her sex life.

² Pacific Ocean State Medical University, Min. of Health of Russia, state-funded higher education institution

³ Yutskovskii Professorial Clinic, limited company

⁴ Professor Yutskovskaia's Clinic, limited company

⁵ Postgraduate training institute, Russian Federal Biomedical Agency, state-funded supplementary vocational education institution

⁶ Russian University for Friendship between Nations, Federal state-funded higher education institution

Female genital mutilation⁷ is an operation that consists in the removal or resectioning of parts of the female genitalia, up to and including removal of the tip and part of the body of the clitoris (clitoridectomy) and the *labia minora*, performed without medical indications. As things stood in 2008, between 100 and 140 million women had undergone this operation, mainly in Africa (in Egypt, Sudan and Ethiopia, more than 80% of women have this operation), and also in Saudi Arabia and Indonesia. With time, it was female ritual circumcision that served as a prototype for female intimate cosmetic surgery.

To begin with, female intimate cosmetic operations were common among commercial sex workers, nude models, bathing suit models, actresses who appeared naked and certain categories of women suffering from such diseases as urinary incontinence, congenital sex organ development defects or birth-related injuries.

Articles about female intimate plastic surgery first began to appear in North American journals in 1978, and the first article describing a method of correction of the female urogenital area appeared in 1984 [1,2]. When Gary Alter presented the results of his own labiaplasty, vaginoplasty and G-spot enlargement work in 1998, there was a sea change in world opinion concerning intimate surgery. Although operations to tighten the vagina had been carried out earlier, the difference in the new method was that they incorporated aspects of plastic surgery, and concentrated on the appearance of the vulva [3].

Intimate filling as a method appeared at the end of the 1990s, and did not begin to be actively used until after 2000. When the method first began to be practised, various fillers were widely used to augment the tissues of the anogenital area, and on occasion some of these did not meet safety requirements. In the USA, for example, numerous complications were seen that were linked to the use of implants based on bovine collagen and liquid silicone. For a long time a leading role in intimate plastic surgery was taken by lipofilling, often in combination with liposuction of the pubic region and the inside surfaces of the thighs. The first experience of lipofilling of the anogenital area was described by E. Hernandez-Prez in 1996 [4]. Following the commencement of use by cosmetologists of hyaluronic acid based products, doctors performing intimate zone correction also began to take a closer look at these. The first publications concerning the safe and effective use of products containing hyaluronic acid in sexual surgery appeared in 2003 [5]. In 2006, the Italian plastic surgeon A. Alessandrini was the first to familiarise a Russian audience, at a congress in Moscow, with intimate filling methods [6]. Since 2006, Professor Ya.A.Yutskovskaia and her colleagues have been engaged in the development and introduction of intimate filling methods for correction work in the anogenital area.

In discussing sexual medicine generally, mention must be made of the role played by professional medical societies. The International Society of Cosmetogynecology (ISCG) is the first, and the world's largest, association of specialists in aesthetic gynaecology and intimate surgery. It was founded in 2004 by Marco A. Pelosi II and Marco A. Pelosi III, and takes in over 700 members and more than 30 countries. The society was set up with the aim of consolidating academic knowledge in the sphere of female intimate aesthetics and of making changes to gynaecological practice. Moreover the organisers appreciated that doctors working on sex-related problems enter into unique relations with patients, which provides an opportunity for fuller aesthetic control. It is important to make the point that as medical activities become increasingly commercialised, the market for services on offer in the sphere of sexual medicine will grow, while the lack of a legal field in this area enables these services to be licensed in the certification register for a variety of types of medical activity. So perhaps specialists engaged in sexual medicine, be they urologists, gynaecologists or cosmetologists, will not run up against ethical/legal problems, but by the same token patients can anticipate strictly medical problems of quality control for the provision of medical services.

2. INTIMATE SURGERY

Women's views

Women go to a doctor both for aesthetic correction and because of functional disorders, including pain during the sex act or while engaging in sport, frequent irritation, vulvalintertrigo and discomfort while wearing underwear or clothing.

Women aged 18-44 prefer to undergo epilation in the bikini zone, which makes for better visualisation of the vulva [7]. In 2008, D. Herbenick and colleagues carried out a study in which 2 500 women took part. The extent of the practice of pubic hair removal was investigated, and the ways in which it was done, and the influence of pubic pilosity on the quality of one's sex life. The study results gave rise to the conclusion that a complete absence of pubic hair is linked to a higher FSFI (sexual function index) level [8].

Konig and colleagues discovered that 78% of 482 women questioned had learned about labiaplasty through the media, while 14% thought that their own *labia minora* looked abnormal [9]. A feeling of awkwardness, "changing-room syndrome" and

⁷ This 3-word phrase is given in parentheses, in English, in the Russian text; but the Russian word translated as 'mutilation' – обрезание – literally means 'circumcision', and contains none of the overtone of 'mutilation', so where it occurs subsequently I have translated it as 'circumcision' – *Translator*.

problems with sex life are also commonly adduced as reasons for wanting intimate correction. Bearing in mind the possibility of congenital deformations of the vulva, psychological problems may occur during the early adolescent period [10]. Possible dysmorphophobia should be borne in mind: one way or another it is the media who are to blame for this, by giving coverage to it in women's magazines, alongside fashion and the accessibility of pornography on the Internet. Meanwhile the rise in the popularity of the procedures has spawned TV reality shows, where the subject of the ideal appearance of female external sex organs has been actively pursued. Michala and colleagues described a study of 16 girls (average age 14.5) who went to a clinic to have their *labia minora* (LMin) reduced in size [11]. Six girls were worried about LMin asymmetry, while 10 complained of protrusion of the *labia minora*, regardless of their normal size. The concept of ideal external sex organs among women in Western countries differs from that among women in other countries. In Rwanda and Mozambique, for example, extended *labia minora* are considered attractive [12], whereas in Japan the most attractive vulva is considered to be one shaped like a butterfly (**fig. 1**) [13].

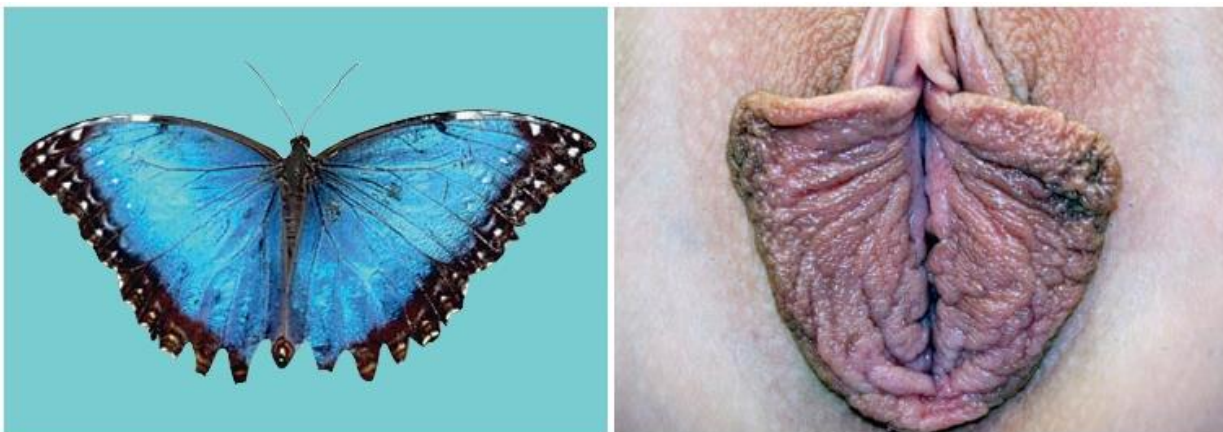

Fig. 1. Vulva that looks like a butterfly.

Doctors' views

Traditionally, it has been gynaecologists who engaged in surgical correction of the vagina and vulva. Since growing numbers of urologists and plastic surgeons are carrying out labiaplasty, intimate filling and cosmetic vaginal operations, the need for correction of complications following interventions is steadily increasing. Most surgeons perform intimate plastic surgery without having had any training in aesthetic vaginal surgery. This gives rise to complications such as non-aesthetic appearance, functional incompetence of the vulva and sexual dissatisfaction. Increasing numbers of patients come to us for correction of such complications as asymmetry, excessive tissue removal, loss of sensitivity and pain in the vulvar area. Around 10% of interventions in the urogenital area that are performed at our centre arise out of unsuccessful operations. In general, cosmetic surgery on the vulva does not require medical indications. According to the results of the consensus adopted in 2007 by the American College of Obstetricians and Gynecologists, the medical indications for intimate surgery are:

- the need to reconstruct the vulva following circumcision;
- asymmetry and hypertrophy of the *labia minora*;
- sclero-atrophic processes in the vulva;
- hypertrophy of the clitoris as a result of an excess of androgens.

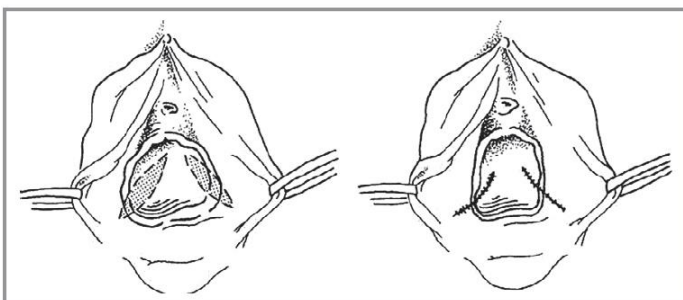
Most surgeons, however, perform intimate plastic surgery with aesthetic objectives or to improve the quality of sex life of the woman and her partner. In a multi-centre, retrospective study, 76% of 258 women had an operation for functional reasons; 53% underwent an operation for cosmetic reasons and 33% to improve self-esteem. Fifty four percent of women who underwent vaginoplasty/perineoplasty and 24% of those who had the combined procedure, including vagino-/perineoplasty, labiaplasty and plastic surgery on the hood of the clitoris, did this to increase their partner's sexual satisfaction [14].

3. METHODS

Vaginoplasty

Vaginoplasty is an intravaginal operation. Vaginoplasty is not intended to eliminate defects in the pelvic floor, but this reconstructive procedure is a modification of traditional colporrhaphy and is often carried out in conjunction with reconstruction of a pelvic floor prolapse.

Classically, the vaginoplasty procedure involves anterior or super-posterior colporrhaphy, modified by the use of plastic surgery methods, excision of the lateral wall of the vaginal mucosa, and also a combination of these methods. Practical experience has shown that, in contrast to other methods, lateral colporrhaphy is less often complicated by a scar process. Ablation or excision of strips of the mucosa from the lateral walls of the vagina enables the diameter of the vagina to be perceptibly narrowed, looseness of the vestibule to be eliminated and the quality of the sex life of the woman and her partner to be improved, but may not be used with prolapse of the pelvic floor (**fig. 2**) [15,16]. This operation is currently used to treat “vaginal relaxation” syndrome. To achieve a better result, the procedure may be combined with perineoplasty and labiaplasty. We have improved on the classical vaginoplasty method, so we can carry out some of the procedures under local anaesthesia. Thus instead of a scalpel we make use of a latest-generation Surgitronradio-frequency apparatus (Ellman International, USA) which enables us to make incisions with exceptional precision and the minimum of trauma. The procedure takes about 60 minutes, and the rehabilitation period 10-15 days.



Complications following an operation to tighten the vagina include dyspareunia, a defect in the mucosa which takes a long time to heal and stress urinary incontinence [17]. In Goodman and colleagues' study, 16.6% of women reported complications, including poor healing of wounds, dyspareunia, post-operative haemorrhaging, pain, excessive constriction of the vestibule and injury to the intestine or bladder with the creation of fistulas [14].

Fig. 2. Diagram of performance of a lateral colporrhaphy. The dotted line shows the zones of excision of vaginal tissues.

In the past, patients with a high risk of haemorrhage and low regenerative capacity used to undergo vaginoplasty using neodymium, diode or CO₂ lasers [18]. Nowadays CO₂ and erbium lasers are universally used. The action of the laser is aimed at the submucosal layer, where a thermal impact is used to begin remodelling of the extracellular matrix, which in turn has the effect of increasing the elasticity of the vaginal wall and tightening of the vagina. A. Gaspar and colleagues assessed the impact of two fractional laser systems – CO₂ and erbium lasers – in conjunction with the topical use of platelet-enriched plasma and pelvic floor exercises. An improvement in the condition of the vaginal wall and a tightening of the vagina were observed in both groups, but more complications were recorded in the patient group on which a CO₂ laser had been used. Complications following the use of a CO₂ and an erbium laser include a burning sensation and excessive tightening of the vagina [19]. At our clinic we use a sixth-generation erbium laser made by Asclepion (Asclepion Laser Technologies GmbH, Germany). The MCL-31 laser system was first used for a gynaecological operation in December 2013 (**fig. 3**). A provisional analysis of the results of the first 15 procedures supports our view that the level of efficacy and safety of this laser system is high. The rehabilitation period takes 3-5 days, depending on the individual characteristics of the woman. Protocols are currently being drawn up for procedures with a variety of changes to the vagina.

There are separate reports concerning the use of lipofilling and hyaluronic acid gels with the aim of tightening the vagina [20]. In our view, fillers are not suitable for use in this procedure, and we would like to warn that this procedure is still in the experimental stage. Despite a lack of studies meeting the requirements of evidence-based medicine, following aesthetic vaginoplasty patient satisfaction is high as regards both medical and functional results and also psychological results. It is not clear whether some kind of ablative or non-ablative laser technology will be developed, or an ultrasound or radio-frequency system, which could be used to address the problems of pelvic floor muscle prolapse. The existence of undesirable events means that lengthy monitoring is needed to analyse long-term efficacy and safety.



Fig.3. The Asclepion MCL31 erbium laser (a); Asclepion handpieces for treatment of vaginal relaxation syndrome and stress urinary incontinence (b).

Perineoplasty

The visible area between the vagina and the rectum is known as the perineum. This is an area where tearing and distension often occur, and kraurosis, and where episiotomies and perineotomies are performed during natural childbirth. Plastic surgery on the perineum (or perineoplasty) is carried out to restore the normal structure of this area through excision of surplus skin, plastic surgery on scar lesions following an episiotomy and insertion of sutures on the muscles of the perineum to eliminate looseness of the vestibule and tighten the entry to the vagina. Most plastic surgeons who carry out vaginoplasty actually perform a perineoplasty as a simpler method of correcting the anterior part of the vagina. Perineoplasty is often combined with labiaplasty and super-posterior colporrhaphy [21].

The following indications for a perineoplasty may be listed:

- existence of scarring to the perineum;
- looseness of the vaginal vestibule;
- low position of the perineum;
- kraurosis.

The performance method comprises excision of a rhomboid area on the perineum above the anus and within the confines of the vaginal vestibule. The lateral boundaries are the remnants of the hymen. The bulbocavernosus and superficial transverse muscle of the perineum are identified, and these are subsequently sutured to create the effect of a tightening of the vaginal vestibule, raising the edges of the vestibule and restoring the structural integrity of the perineum (fig. 4). This procedure is carried out under local anaesthetic with excision of scar tissue using radio-frequency or laser technologies. Use of an erbium laser enables the removal of rough edges and surplus skin, resection of skin neoplasms, enhancement of skin elasticity and elimination of skin hyperpigmentation (fig. 5).

Labiaplasty

The dimensions of the LMin are individual for each woman and change during the course of her life. In the anterior part, the widest part when spread, the breadth of the LMin is on average from 2 to 4 cm. During the course of life, under the influence of endogenous (hormones) and/or exogenous (injury or wearing of underwear) factors, there is a change in shape and loss of function in the LMin, and such changes are known as involution [22].

Hypertrophy of the *labia minora* comes as an increase in the size of the LMin, leading to a decrease in the erectility and sexual hypo-aesthesia both of the LMin themselves and of the tip of the clitoris.

Elongation of the *labia minora* is a lengthening of the LMin by more than 5 cm in their peak state of extension. Most women think that the ideal length of the LMin should be within 1 cm in a non-extended state.

Protrusion of the *labia minora* is when the LMin protrude from the sexual cleft, whereas they should be fully concealed by the *labia majora* (LMaj).

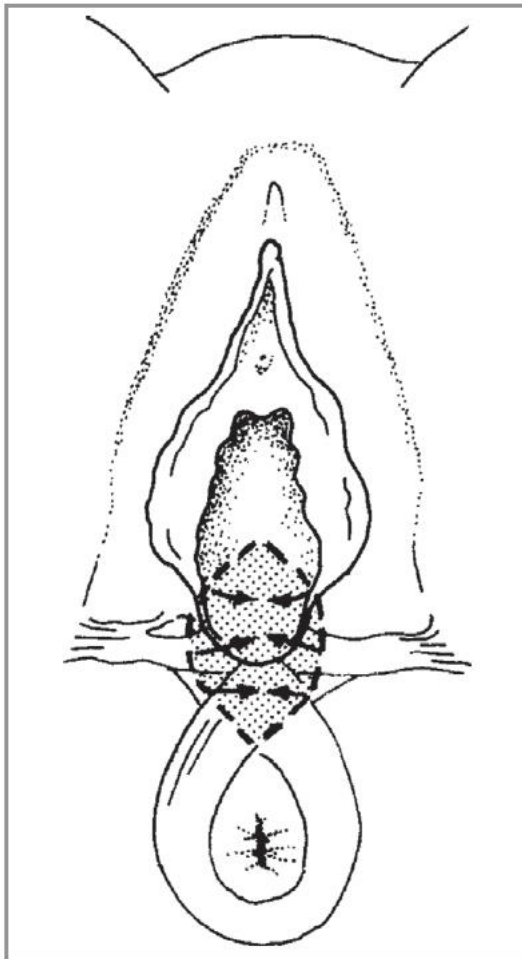


Fig. 4. Diagram of how a perineoplasty is performed in conjunction with an anterior colporrhaphy

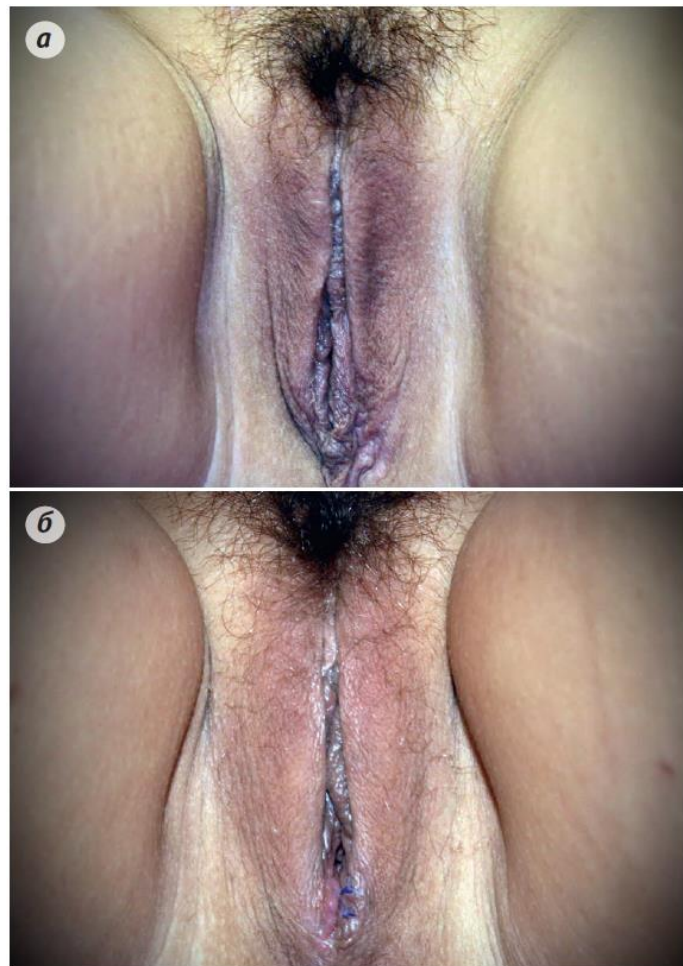


Fig. 5. Patient, aged 39, before and after perineoplasty and laser vaginal rejuvenation (photography from archives at Professor Yutskovskaia's clinic).

Besides elongation and hypertrophy of the LMin, a distinct, to a greater or lesser extent, asymmetry in them is a common enough observation, linked to anatomical idiosyncrasies and constituting a version of normal development of the external sex organs. Asymmetrical labia usually give women greater discomfort than labia that are evenly enlarged.

Labiaplasty is a procedure that entails a diminution in or alteration of the shape of the LMin. Labiaplasty not only enables the shape of the LMin to be altered, but may also be used to eliminate pigmented areas and excess wrinkles. Labiaplasty is usually carried out when there is lengthening (elongation) or asymmetry of the LMin. Any non-malignant formations (e.g. papillomas and condylomas) of the LMin may also serve as a reason for surgical intervention. When labiaplasty was being developed, its objective was to reduce the size of the LMin and to remove pigmentation and excess wrinkles, so the main method was considered to be marginal (linear) resection. But this method has serious deficiencies associated with loss of sensitivity and of the natural appearance of the vulva. At many clinics, however, this method is used because it is simple to perform (**fig. 6**) [23].

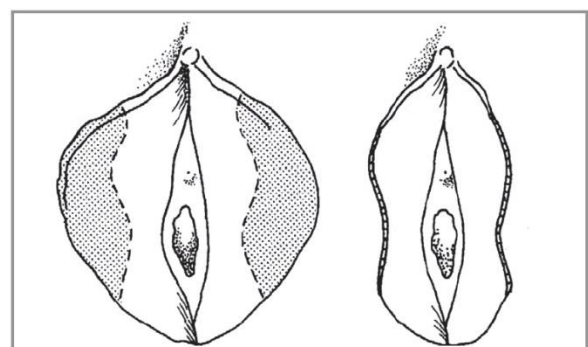


Fig. 6. Diagram of performance of marginal (amputational) labiaplasty.

Outline resection is carried out according to the canons of plastic surgery, using W-Y- and Z-plasty elements. There is virtually no risk of complications when this is done. When the intervention is carried out, it is best that intradermic sutures are used. One drawback of the method is a lack of efficacy with very distinct pigmentation of the urogenital area (**fig. 7**) [24].

The de-epithelisation method entails the creation of an elliptical de-epidermised area on the surface of the LMin while maintaining the integrity of the underlying tissues. This is the least destructive method, but still has a number of drawbacks, the most fundamental of which is the lack of potential to use the method with hypertrophy of the LMin to over 4 cm, since in this case their thickness is significantly increased. At the current stage of development of labiaplasty, a combination

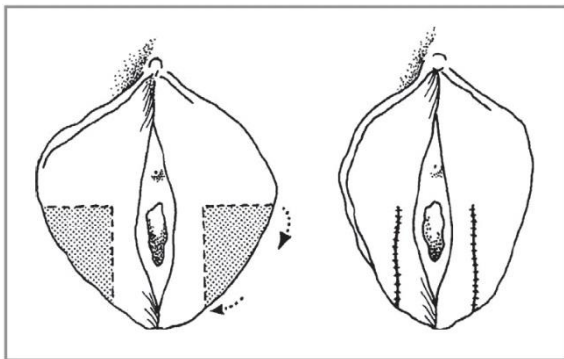


Fig. 7. Diagram of performance of outline resection.

method is most commonly used, which means outline resection with elements of the de-epithelisation method (**fig. 8**) [25]. There are dozens of ways and methods of performing this operation, but they all have their own advantages and drawbacks. We have come up with a unique algorithm for selection of a method individually for each patient.

The advantages of the “laser scalpel” over the surgical one come down to a more accurate incision line, absolute sterility and a lack of sutures and scars. The operation time and rehabilitation period are significantly curtailed. LMin correction using a surgical laser is basically carried out using a CO₂- and Nd:YAG-laser. We also make use of a radio-frequency method to perform labiaplasty.

Following a resection, an intradermic cosmetic suture is usually applied. At the end of the operation, a long-lasting local anaesthetic is introduced into each LMin, which enables the patient to return home with no problem on the day of the operation. Since the area of the genitalia features a good blood supply, the mucosa heals quite quickly and no perceptible scars are left behind. Following the operation, the recommendation is to apply antiseptic agents to treat the wound margins (5-6 times a day) for 7 days. For 2-3 weeks it is best not to go to gyms, swimming-pools or saunas. Sexual contacts are ruled out for up to 3 weeks. The patient will not have any social life for just 1-2 days. Complications are encountered extremely rarely when a labiaplasty is performed, and they are mainly linked to individual idiosyncrasies of the body. The commonest complications are haemorrhaging lasting more than 3 hours and the formation of haematomas, which sort themselves out

within no more than 4 days [26].

We conducted a retrospective analysis of 130 patient outpatient cards following surgical labiaplasty. Complications were encountered in 12% (15 patients), and these included pain in the area of the post-operative wound that lasted more than 3 days for 20% (3 patients), and LMin hypaesthesia in 46% (7 patients). There was also hyperpigmentation in the post-operative suture zone in 34% of cases (5 patients). Through a prospective assessment of the patients’ sexual function before and after the operation, conducted using the Female Sexual Function Index (FSFI) questionnaire, we established that the procedure undergone had had a positive impact on the women’s sexual health.

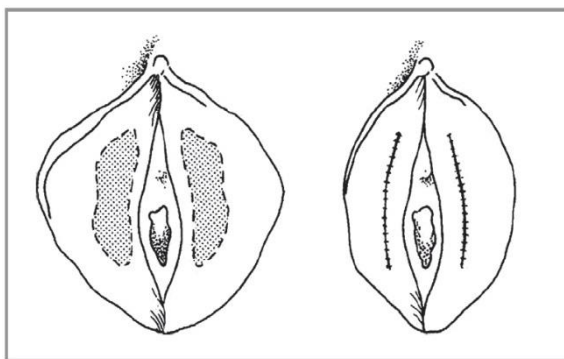


Fig. 8. Diagram of performance of de-epithelisation labiaplasty.

Plastic surgery on the hood (extreme tip or mantle) of the clitoris. An enlargement of the LMin in the upper third is commonly accompanied by an enlargement of the hood of the clitoris, which leads to an aesthetically unsatisfactory appearance, sexual hypaesthesia and a diminution in sexual satisfaction. Genetics, hormonal changes and the nature of the woman’s sex life may introduce substantial changes into the way the clitoral area looks. A poorly performed labiaplasty, not taking into account surplus skin in the clitoral area, may give rise to a disruption of the structure of this area.

At our clinic we carry out surgical correction of folds of skin to the side of the clitoris. At the same time as this procedure, correction of the frenulum of the clitoris is carried out to fix the head of the clitoris in a sexually advantageous position. The clitoris and its nerves are not directly involved in this. The procedure of surgical correction of the hood of the clitoris takes

place under outpatient conditions, under local anaesthesia. The procedure takes 30 minutes and the rehabilitation period is 7-10 days (**fig. 9**).

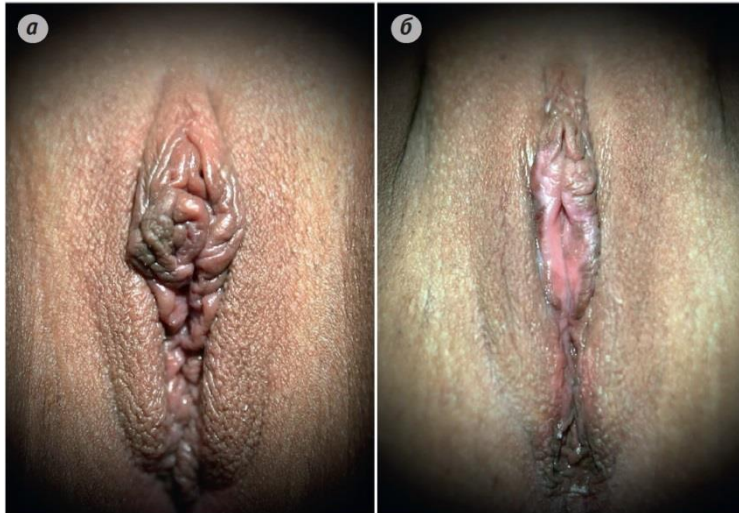

Fig. 9. Patient aged 27: before (**a**) and after correction of the hood of the clitoris (**b**) (photography from archives at Professor Yutskovskaia's clinic).

Correction of the hood and frenulum of the clitoris using hyaluronic acid products. With congenital developmental anomalies or aggressive surgical intervention in the LMin area, it is possible for a situation to arise where the head of the clitoris is not covered by the hood, as it should normally be. This leads to constant difficulty when wearing tight underwear, discomfort and a fall in the number and quality of clitoral orgasms. In this situation the performance of a surgical operation is not possible because of the complexity of the reconstructive techniques and the need for a lengthy rehabilitation period. To correct an existing defect we use high-viscosity gels based on hyaluronic acid which have been specially developed for intimate filling. The procedure takes place under local application anaesthesia and rehabilitation takes 3 days.

Correction of involution lesions of the *labia majora*

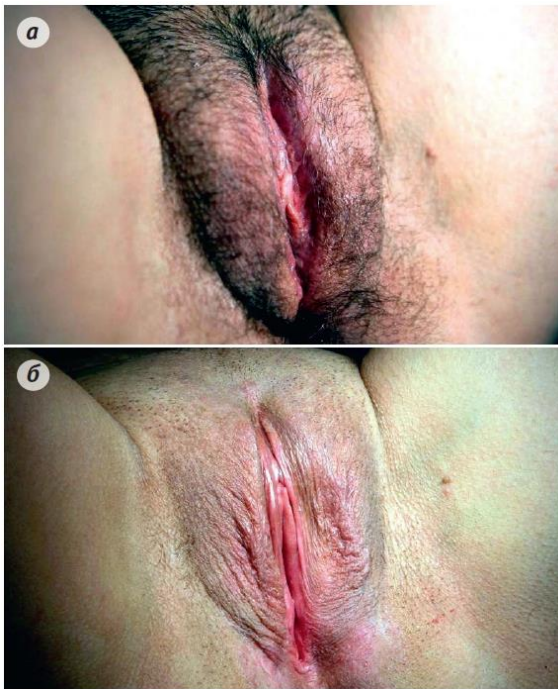An enlargement of the LMaj may be associated with loss of elasticity and surplus skin, and also with local fatty deposits. Such an enlargement of the LMaj may, when the woman is wearing trousers, bathing costumes and tight-fitting underwear, look like an unaesthetic convexity, and may also cause discomfort associated with enhanced perspiration in the external sex organs. The LMaj may be enlarged from birth, and they may also change after childbirth or with age. In many women quite large and wrinkled labia are observed following major weight loss, and especially following bariatric surgery. To achieve the optimum aesthetic result, a half-moon-shaped flap of skin is excised on the inside of the labia, and the margins are sutured using a cosmetic suture which is concealed between the *labia minora* and *majora*. LMaj plastic surgery is carried out at our clinic under local anaesthesia, and the procedure takes 60 minutes.

Another important problem is deformation of the inferior commissure of the LMaj, which in turn gives rise to looseness of the vaginal vestibule and the entry of intestinal microflora into the vagina – the main cause of recurrent infections of the vagina, urethra and bladder.

To correct the volume of the LMaj, a subcutaneous injection of various fillers is carried out. This is known as intimate filling. Earlier the “gold standard” for LMaj augmentation was lipofilling. This method entails preliminary liposuction and subsequent introduction of aspirated fatty tissue into the area where correction is intended. Purified fat is gathered from areas of local fatty deposits such as the knees, stomach and thighs, and is then treated by passing it through a system of filters. Syringes with a volume of 10-20 ml with a Luer-Lock type lock and blunt-ended 14G cannulas are used for the injections. For stabilisation of it and improvement of its regenerative properties, the collected fat is mixed with autologous platelet-enriched plasma (PRP) at a ratio of 4:1. Experience in the use of lipofilling in other areas of aesthetic medicine has revealed the negative properties of this method, such as low plasticity, lack of predictability of its effect, and frequent instances of the formation of lipogranulomas and filler migration. The mean frequency of complications when this method is used is 6.6%. In the available literature there is information on the use of liquid silicone, bovine collagen and a polyurethane biopolymer for LMaj augmentation. The authors themselves, however, mention the high risk of complications, associated primarily with the high level of toxicity of the materials and their capacity to migrate and cause aseptic inflammation [27].

To achieve the desired aesthetic result and to lower the risk of complications developing, a search was made for a bio-compatible filler with optimal physical and chemical properties. A visco-elastic hyaluronic-acid-based gel that is well known to doctors working in aesthetic medicine turned out to be a suitable candidate. There are numerous products now on the cosmetology market which could be used for plastic surgery to shape face and body. As creators of an original method for intimate filling, we recommend the use of the only filler that is currently legitimate – Bellcontour® GVISC (HyalIntertrade

S.A. Swiss), which we have been actively using since 2005. The lack of immunogenic properties and migration, lengthy biodegradation and unique rheological properties make this the optimal product for intimate filling. All procedures are carried out under local application anaesthesia, and the procedure time is 20 minutes. At Professor Yutskovskaia's Clinic we were the first in Russia to make use of the Pelleve radio-frequency apparatus (Ellman International, USA) for intimate plastic surgery. This procedure may primarily be of assistance to patients suffering from unsightly enlarged LMaj which have lost their tone. Patients who previously used to suffer from the so-called "camel toe" (swelling of the LMaj when wearing skintight clothing) may now avoid plastic surgery on the LMaj by undergoing a 30-minute non-invasive procedure (**fig. 10**).



One question that is under discussion is the use of thread lifting to correct involution lesions to the vulva. We use various Aptos thread systems for this purpose. To correct a loose vestibule and perineum height, the Thread 2G system is used, and the NanoVitis and Excellence Elegance systems (Aptos, Russia) for modelling of the *labia minora* and *majora*. Work is currently under way to create a protocol for the performance of this procedure.

Laser rejuvenescence of the vagina

Lasers have been in use for over 20 years for the correction of age-related changes in the vaginal area. Examples include venereal warts and colpectasia and scars from episiotomies and perineotomies. They are also used to treat pre-cancerous diseases of the vulva, kraurosis (sclero-atrophic lichen) and afflictions of the neck of the womb. We and our patients often notice changes to the appearance of the vulva that happen following laser treatment: elimination of hyperpigmentation, and a taut and aesthetically pleasing appearance. At Professor Yutskovskaia's Clinic we use laser rejuvenescence of the vagina to treat vulvar kraurosis. The intervention protocol includes treatment with an ablative erbium laser and the use of autoplasm (PRP) and non-stabilised hyaluronic acid.

Fig. 10. Patient aged 45: before (**a**) and after performance of laser epilation and the Pelleve procedure in the labia majora area (**b**) (photography from archives at Professor Yutskovskaia's clinic).

Use of a fractional erbium laser supports collagen regeneration and enables the skin to be smoothed out and scars to be reduced in size, with no injury to surrounding tissues. Laser vaginal and vulvar rejuvenescence are performed under local anaesthesia. The procedure lasts between 15 and 30 minutes, and the rehabilitation period is 5-7 days.

G-spot

The G-spot (lip of the urethra, G point, "12 o'clock zone", G zone, Gräfenberg spot (zone), internal trigger) is the point of projection of the female prostate onto the anterior wall of the vagina, pressure on which may be a way to achieve erogenous stimulation. G-Shot® (enlargement of the G-spot) is a trademark registered in 2001 by David Matlock. This is a low-invasive method of tissue augmentation in the anatomical area to increase sexual excitation during coitus [28]. For quite some time, the legitimacy of this procedure was questioned in scientific reports. When on 18 October 2008 the Federal International Committee on Anatomical Terminology (FICAT), based on studies conducted by M. Zaviacic, included the term "female prostate gland" in its Glossary of Terms, all doubts were resolved [29].

enlargement

Hyaluronic acid gel is introduced into the submucosal layer in the G-spot area and the gap between the anterior vaginal wall and the urethra, using a drop, linear-retrograde or "fan" technique. The volume of product introduced is 0.5-3.0 ml. A 25-27G needle is used. This leads not only to an enlargement of the G-spot projection zone, but also to a certain diminution in the volume of the vagina, which is particularly marked during sexual contact at the time of formation of what is known as the "orgasmic cuff". As a result of the intervention, the G-spot projection zone becomes the most protruding part of the anterior vaginal wall, and more accessible to tactile impact, which increases its sensitivity and thus improves the quality of sexual relations [30]. The introduction of other fillers, such as autologous fatty tissue, collagen or Radiesse (MerzPharma

GmbH & Co, Germany) may lead to unpredictable results and culminate in complications such as descent of the vaginal wall, stress urinary incontinence, bleeding and infection.

4. CONCLUSION

The objective of intimate surgery is to alleviate psychological and/or physical suffering caused by aesthetic or functional deficiencies of the genitalia. Although the number of surgeons engaged in intimate plastic surgery is rising, the increase in patient numbers is being promoted by media activity. Some gynaecologists are unable to comprehend the attitude taken by a woman to her own vulva/vagina. It is becoming clear that modern women have a psycho-biological need to obtain sexual satisfaction as a support for their self-esteem and self-respect. Modern girls and adult women who perform bikini zone epilation have a clear picture of the perineum, its proportions and beauty standards for it. Intimate images that are actively dispersed via the Internet and other media are helping to consolidate an ideal "image" in women's awareness – a narrow vestibule and delicate *labia minora*.

Surgeons performing intimate plastic surgery and having a conflict of interests may unintentionally discredit intimate surgery with modern scientific society and potential patients. It is not worth performing procedures on girls who are subsequently planning to become pregnant and who have not yet achieved sexual maturity. Women wishing to have intimate plastic surgery performed should be made aware of all the possible options for correction of the vulva and vagina and examined to see whether they have any pelvic disorders for which proven treatment methods are available. The ethical duties of surgeons in respect of a patient include professional honesty, prevention of any conflict of interests and carrying out the wishes of the patient.

REFERENCES

- Honore LH, O'Hara KE. *Benign enlargement of labia minora: report of two cases. Eur J Obstet Gynecol Reprod Biol* 1978;8(2):61–64.
- Hodgkinson DJ, HaitG. *Aesthetic vaginal labioplasty. Plast Reconstr Surg* 1984; 74(3):414–416.
- Alter G. *New technique for aesthetic labia minors reduction. Ann Plast Surg* 1998;40:287–290.
- Hernandez-Perez E, Machado A. *Fat transplants in male and female genitals. Am J Cosmet Surg* 1996;13:109–111.
- Kim JJ, Kwak TI, Jeon BG, et al. *Human glans penis augmentation using injectable hyaluronic acid gel. Int J Impot Res* 2003;15: 439–443.
- V International symposium of aesthetic medicine. *Moscow, Russia 16–18 February 2006.*
- Yurteri-Kaplan LA, Antosh DD, Sokol AI et al. *Interest in cosmetic vulvar surgery and perceptions of vulvar appearance. Am J Obstet Gynecol* 2012;207:428. e1–e7.
- Herbenick D, Schick V, Reece M, et al. *Pubic hair removal among women in the United States: Prevalence, methods and characteristics. J Sex Med* 2010;7:3322–3330.
- Konig M, Zeijlmans IA, Bouman TK, van der Lei B. *Female attitudes regarding labia minora appearance and reduction with consideration of media influences. Aesthetic Surg J* 2009;29:65–71.
- Jothilakshmi PK, Salvi NR, Hayden BE, Bose-Haider B. *Labial reduction in adolescent population – a case series study. J Pediatr Adolesc Gynecol* 2009;22:53–55.
- Michala L, Koliantzaki S, Antsaklis A. *Protruding labiaminora: abnormal or just uncool? J Psychosom Obstet Gynaecol* 2011;32(3):154–156.
- Essen B, Johnsdotter S. *Female genital mutilation in the West: traditional circumcision versus genital cosmetic surgery. Acta Obstet Gynecol Scand* 2004;83(7):611–613.
- Scholten E. *Female genital cosmetic surgery – the future. J Plast Reconstr Aesthet Surg* 2009; 62(3):290–291.
- Goodman MP, Placik OJ, Benson RH et al. *A large multi-center outcome study of female genital plastic surgery. J Sex Med* 2010;7:1565–1567.
- Pardo JS, Sola VD, Ricci PA, et al. *Colpoperineoplasty in women with a sensation of a wide vagina. Acta Obstet Gynecol Scand* 2006;85(9):1125–1127.
- Adamo C, Corvi M. *Cosmetic mucosal vaginal tightening (lateral colporrhaphy) improving sexual sensitivity in women with a sensation of wide vagina. Plast Reconstr Surg* 2009;123(6):212e–213e.
- Goodman MP, et al. *Female cosmetic genital surgery. Obstet Gynecol* 2009;113(1):154–159.
- Gaspar A, Addamo G, Brandi H. *Vaginal fractional CO2 laser: a minimally invasive option for vaginal rejuvenation. Am J Cosmetic Surg* 2011 28(3):156–162.
- Gaspar A. *Comparison of two novel laser treatments in aesthetic gynecology. J Lasers and Health Acad* 2012;Supplement(1):S10.
- Brambilla M. *Intramuscular-submucosal lipostucture for the treatment of vaginal laxity. Paper presented at: Congresso Internazionale di Medicina Estetica; October 10/2008; Milan, Italy.*
- Rouzier R, Haddad B, Deyrolle C, et al. *Perineoplasty for the treatment of introital stenosis related to vulvar lichen sclerosus. Am J Obstet Gynecol* 2002;186(1):49–52.
- Tepper OM, Wulkan M, Matarasso A. *Labioplasty: anatomy, etiology, and a new surgical approach. Aesthet Surg J* 2011;31(5):511–518.
- Rezaei A, Jansson P. *Clinical techniques: evaluation and result of reduction labioplasty. Am J Cosmetic Surg* 2007;24(2):242–247.
- Alter G. *Labia minora reconstruction using clitoral hood flaps, wedge excisions, and YV advancement flaps. Plast Reconstr Surg* 2011;127(6):2356–2363.
- Choi HY, Kim KT. *A new method for aesthetic reduction of labia minora (the deepithelialized reduction of labioplasty). Plast Reconstr Surg* 2000;105(1):419–422, discussion 423–424.
- Felicio YA. *Labial surgery. Aesthet Surg J* 2007;27(3):322–328.
- Vogt PM, Herold C, Rennekampff HO. *Autologous fat transplantation for labia majora reconstruction. Aesthetic Plast Surg* 2011;35(5):913–915.
- Kilchevsky A, Vardi Y, Lowenstein L, Gruenwald I. *Is the female G-spot a distinct anatomic entity? J Sex* 2012;9:719–726;
- Zaviacic M, Zaviacic T, Ablin RJ, et al. *The human female prostate: history, functional morphology and sexology implications. Sexologies* 2001;11:44–49.
- Юцковская Я.А., Лешунов Е.В. *Женская предстательная железа. Современные возможности малоинвазивной коррекции сексуальных дисфункций. Пластическая хирургия и косметология* 2013;2:307–315

Laser Vaginal Tightening (LVT) – evaluation of a novel noninvasive laser treatment for vaginal relaxation syndrome

(2015), *J. LAHA*, Vol. 2012, No.1; pp. 59-66.

Jorge E. Gaviria P, Jose A. Lanz L

Aldana Laser Center, Caracas, Venezuela

Abstract

The objective of this study was to evaluate the safety and efficacy of a novel laser treatment for vaginal relaxation syndrome.

Method: A pilot study was conducted on 21 patients who received the novel laser treatment for vaginal tightening with a 2940 nm Er:YAG laser between June 2011 and January 2012. All patients received two treatment sessions with an interval between sessions of 15 to 30 days. In a non-ablative, thermal-only mode, laser energies of approx. 90 J per treated area in the vaginal canal and of approx. 10 J per treated area at the vestibule and introitus were delivered to the patient's vaginal mucosa. A special Laser Vaginal Tightening (LVT) questionnaire was designed for assessing the improvement of vaginal tightness via patient self evaluation and by their sexual partner's assessment. POP-Q measurements were also performed prior to both treatment sessions in an attempt to objectively assess the change in vaginal tissue structure. Additionally, a PISQ-12 questionnaire was also used as a standard assessment tool for pelvic organ prolapse, urinary incontinence and sexual gratification. Patients were also asked about treatment discomfort, potential adverse effects, and their general satisfaction with the treatment.

Results: Twenty of twenty one patients (95%) reported significant (moderate and strong) improvement of their vaginal tightness, and also all of their partners confirmed an improvement of vaginal tightness during sexual intercourse (85% reported significant improvement and 15% reported mild improvement). All patients but one (95%) reported better sex after the treatment. Five patients had prolapses (of stages 1-3) before receiving the treatment, which improved in all of these patients, leaving just two of them with prolapses (one with stage 1 and one with stage 2). Three patients suffering from SUI before the treatment reported significant improvement (2) and complete healing (1). There were no adverse effects and patient discomfort was assessed as minimal.

Conclusions: The novel laser vaginal tightening therapy is an effective and safe method for the treatment of vaginal relaxation syndrome.

Treatment of Vaginal Relaxation Syndrome with an Erbium:YAG Laser Using 90° and 360° Scanning Scopes: A Pilot Study & Short-term Results

(2014), *Laser Ther. Jul 1;23(2):129-38.*

Min Seok Lee

Sophie-Marceau Women's Clinic, Daegu, South Korea

Abstract

Background and Aims: Vaginal relaxation syndrome (VRS) is both a physical and psychological problem for women and often their partners. Recently the 2940 nm Er:YAG laser has attracted attention for VRS treatment. The current study evaluated the clinical efficacy of this nonsurgical laser procedure.

Subjects and Methods: Thirty postpartum females with VRS or vaginal atrophy, ages from 33 – 56 yr (mean 41.7 yr) were divided randomly into two groups, Group A and Group B. Both groups were treated for 4 sessions at 1~2-weekly intervals with a 2940 nm Er:YAG via 90° and 360° scanning scopes. In Group A the first 2 sessions were performed with the 360° scope and the final 2 with the 90° scope in multiple micropulse mode, 1.7 J delivered per shot, 3 multishots, 3 passes per session. Group B underwent multiple micropulse mode treatment with the 90° scope in all 4 sessions (same parameters as Group A) then during the final 2 sessions an additional 2 passes/session were delivered with the 360° scope, long-pulsed mode, 3.7 J delivered per shot. Perineometer assessments were performed at baseline and at 2 months post-treatment for vaginal tightness. Histological specimens were taken at baseline and at 2 months post-procedure. Subjective satisfaction with vaginal tightening was assessed together with improvement in sexual satisfaction. Results were tested for statistical significance with the paired Student's *t*-test.

Results: All subjects successfully completed the study with no adverse events. Significant improvement in vaginal wall relaxation was seen in all subjects at 2 months post-procedure based on the perineometer values, on the partners' input for vaginal tightening (76.6%) and for sexual satisfaction as assessed by the subjects themselves (70.0%). The histological findings suggested better elasticity of the vaginal wall with tightening and firming.

Conclusions: Both regimens of Er:YAG laser treatment for VRS produced significant improvement in vaginal relaxation. With multishots delivered in the multiple micropulse mode via scanning scopes, nonsurgical Er:YAG laser treatment was pain-free, safe, side effect free, easily tolerated and effective.

Novel Minimally Invasive VSP Er:YAG Laser Treatments in Gynecology

(2012), *J. LAHA*, Vol. 2012, No.1; pp. 46-58.

Zdenko Vizintin¹, Mario Rivera², Ivan Fistonić³, Ferit Saraçoğlu⁴, Paolo Guimares⁵, Jorge Gaviria⁶, Victor Garcia⁷, Matjaz Lukac⁸, Tadej Perhavec¹, Leonardo Marini⁹

¹Fotona, Ljubljana, Slovenia

²GynDerma Laser Clinic, Santa Cruz, Bolivia;

³Fistonic Gynecology Clinic, Zagreb, Croatia;

⁴Numune Research and Training Hospital, Ankara, Turkey;

⁵GyneLaser, LASERCARE Medicina & Estetica, Brasilia, Brasil;

⁶Aldana Laser Center, Caracas, Venezuela;

⁷Skintima Clinic, Maracaibo, Caracas, Venezuela;

⁸Institute Jozef Stefan, Ljubljana, Slovenia;

⁹Skin Doctors' Center, Trieste, Italy

Abstract

Some of the most common health problems among women that are caused by a deteriorating laxity, elasticity and tightness of mucous membranes are vaginal relaxation (and the associated loss of sexual gratification) and stress urinary incontinence. Recently, two novel minimally invasive, non-ablative Er:YAG laser techniques have been introduced, a vaginal tightening therapy IntimaLase™ and a stress urinary incontinence therapy IncontiLase™, which show the potential to become an optimal solution for many women suffering from these problems. Both treatment techniques exploit the photothermal effect of a laser beam on mucosa tissue in order to cause its shrinkage without any removal of tissue. The overall impact and burden on the patient's organism is thus minimal, as opposed to more invasive classical or laser surgical procedures.

In this paper, a special Er:YAG Pixel Screen technology used in these novel gynecological treatments, and its ablative characteristics, are first analyzed with the aim to establish a range of laser parameters for safe, single-pulse or SMOOTH mode, non-ablative treatment of mucosa tissue. The initial results of multi-center clinical studies of the IntimaLase™ and IncontiLase™ treatments are then presented. All five centers involved in the studies of the IntimaLase™ treatment reported positive results, i.e. an improvement in vaginal tightness for a large majority of treated patients, with practically no adverse effects. Similarly, all four studies of the IncontiLase™ treatment showed improvement in stress urinary incontinence (SUI) for a large majority of treated patients. Many patients with mild SUI reported to become free of the symptoms of incontinence following the treatment. There were no adverse effects of this treatment reported in any of the studies.

FAQ

Frequently asked questions about the Juliet procedure

Dr. E. V. Leshunov, MD answers

How many procedures have you performed?

I have been performing the Juliet procedure for 6 years. As of June 2017, I have performed over 900 procedures.

How soon do patients notice results?

The Juliet procedure is performed with the MCL31 system and is unique because it incorporates a two pass technique.

1. The first pass ablates into the collagen-rich submucosa. This immediately contracts around each microchannel and also stimulates neocollagenogenesis for long-term improvement.

2. The second pass is a thermal treatment that further stimulates the body's normal "wound healing cascade" to revitalize the function of the mucosa and to remodel the damaged / atrophied tissue. It also induces new vessels and nerves endings formation in vaginal mucous membrane.

With the MCL31's unique engineering design and protocols, which normally do not require anesthesia, most of my patients report that they can feel an immediate improvement.

How soon can patients return to normal activity?

Patients walk out of the office after the treatment and can immediately resume a relatively normal lifestyle. But, we encourage our patients to relax for 3 days after the treatment. This includes avoiding strenuous exercise, hot tubs, and sexual activity. Most of my patients return to full activity (including sexual activity) in 72 hours.

How many treatments does each patient need?

Most of my patients only need two treatment sessions to achieve desired results. However, some patients do request a third treatment. For those patients, I remind them that the remodeling process (neocollagenogenesis) will continue for several months after their treatment. If they still want a second treatment, then we wait about 4 weeks from their initial treatment and repeat the protocol. Similarly, many other physicians also report a 1 – 2 treatment protocol for Vaginal Atrophy, Vaginal Relaxation Syndrome, and even Stress Urinary Incontinence^{1,2}.

How long does the improvement after the treatment last?

Personally, I have seen patients 36 months post-treatment and they are happy. But, because the Juliet procedure is not really a "repair" but "individualized rejuvenation", it is difficult to generalize how long it will last. I do feel that some severely-atrophied patients may need to "turn back the clock" more frequently (perhaps once every two years?) in order to maintain their rejuvenated condition.

How does the system know whether to tighten or to rehydrate?

The mechanism of action is to stimulate the body to heal itself from the aging process.

- The ablation pass instantly vaporizes tiny columns of damaged tissue to remove it from the aged vagina and for tightening it. The heat causes macrophage activity to remove elastotic cells for additional long-term effects. Because only a small portion of the total tissue is treated (principle of fractional treatment) and the spots are so tiny, the laser does NOT create a "fire alarm" condition for scar creation to follow. Instead, the laser stimulates heat shock proteins in a gentle fashion so the body builds new Type 3 "elastic" collagen instead of Type 1 "scar" collagen.

- As a result of the re-scaffolding architectural changes, the resulting tissue is more like PRE-menopausal tissue – more hydrous, with thicker mucosal covering to maintain hydration.

The protocol allows for a range of settings. For younger patients who are seeking more tightening, I might choose to use medium/high energy. For older patients, I may perform 1 or 2 treatments with gentler settings. Even in severe post-menopausal cases, the mucosal lining may double in thickness (from ~70 to ~150 microns) as a result of the treatment.

What are the results?

For over 5 years, physicians in Europe and South America have been trying to perfect the treatment of Vaginal Atrophy, Vaginal Relaxation Syndrome and Stress Urinary Incontinence. Over time, the Erbium:YAG laser has become the preference due to high efficacy, longerlasting results and lack of side effects associated with CO2 lasers.^{3,5} As popularity rose and patients became more educated, patients came to prefer the "one and done" effectiveness that the Juliet offers.

In my practice, I routinely share the data from the studies^{1,2} showing that 100% were happy after 2 treatments. For patients where I sense doubt or even a fear of lasers, I always offer them the ability to have 2 or 3 gentle treatments. With this approach, the majority achieve their results in 1 treatment and consider themselves to be "super responders". By telling them the protocol is for 2 treatments, this also gives me a chance for a follow-up exam or the second treatment, if needed.

How safe is the treatment?

There have been no reported side effects with Erbium:YAG laser treatments.^{3,4} The Juliet procedure is virtually “patient-calibrated”. That is, we start with a moderate energy setting for the first pulse. We increase to optimum energy, but can back down if they feel any discomfort.

The Erbium:YAG laser’s wavelength of 2,940nm is at the very peak of water absorption. Therefore, any water in the cells will absorb the energy. This acts as sort of a “safety net” to prohibit the energy from going too deep. Even at the maximum energy for this treatment, the depth is only about 300 – 400 microns, which would not reach the adventitial tissue.

The two-phase technique helps to insure that there is no bleeding. This not only makes the procedure more palatable for the patient, but also reduces the risk for infections or other side effects.

Finally, the handpiece design makes the procedure safe in three ways: homogeneous energy delivery, sterility and elimination of side effects.

Is there an “ideal” patient?

When we first started, we treated peri-menopausal patients in their 40’s and 50’s. However, this treatment has extended down to patients in their 20’s and up to patients in their late 70’s. The most important factor is patient compliance. Herein, they must take their precautionary prophylactic antiviral and antibiotic and also refrain from strenuous activity for 2 days after treatment. Of course, there are some relative contraindications (such as abnormal pap smear) that need to be considered.

How easy is it to use the MCL31 for the Juliet procedure?

Clinicians find the procedure very easy to perform. In my opinion, it is easier than inserting a standard examination speculum. Moreover, the slim cannula can be easily inserted even in elderly, post-menopausal women.

How long did it take you to learn the technique?

The technique itself is quite simple and does not require a preceptorship. Most physicians simply watch the training video and/or read the step-by-step training guide. In many situations, the primary physician treats the first dozen patients, then begins to delegate to an ancillary healthcare provider, such as a physician’s assistant or nurse practitioner.

Can the Juliet be used on patients with a mesh sling or prolapse mesh?

While I am not aware of a formal study on these patients, it should be safe because the laser energy penetrates less than 350 microns even at the maximum setting in the protocol. At that shallow level, there should be no interaction with the mesh. Laser treatment can be done after mesh surgery for better implantation and rehabilitation patients after surgery. Because sometimes this kind of patients don’t have effect after mesh surgery, but combination can improve the results.

Can Juliet treatments be combined with other therapies?

In my practice, I find that many patients using creams or hormone therapies are non-compliant or simply frustrated with the continual use. Other patients are simply not ready for an invasive procedure or dislike the thought of mesh implantation. These patients gravitate to the Juliet procedure. While I encourage most patients to continue their pre-Juliet regimen, in reality, only very few of them do.

Have any patients felt that the treatment made her worse?

Patient screening is an important part of the process – primarily because of non-compliance, unrealistic expectations, or other psychological issues. In my practice, “patient-controlled” issues are the only foreseeable reason for a suboptimal result.

1. Rivera M. (May 2011). Laser treatments for Vaginal Tightening and Stress Urinary Incontinence, oral presentation at first Symposium of Laser and Health Academy, Gozd Matruljek, Slovenia, 21 May, 2011.
2. Guimaraes P. (January 2012). Laser Vaginal Rejuvenation, oral presentation on 5th World Congress of the International Society of Cosmetogynecology. Las Vegas, USA, 17 January 2012.
3. Gaspar, A. (2012). Comparison of two novel laser treatments in aesthetic gynecology. *Journal of the Laser and Health Academy*, 2012; 1 (Supplement), S10.
4. Gaspar, A. (2013). Evolution of minimally invasive laser treatments for Vaginal Atrophy. *Journal of the Laser and Health Academy*, 2013; 1, S28. doi:ISSN 1855 – 991
5. Fistonic I, Manestar M, Perovic D, Sorta-Bilajac Turina I, Fistonic N, Maletic D, Maletic A. Laser vaginal tightening for sexual dysfunction. *Climacteric* 2011;14 (Supplement 1):8

Studies Book

Juliet[®]
the feminine laser

Copyright © Asclepion Laser Technologies GmbH.
All rights reserved.